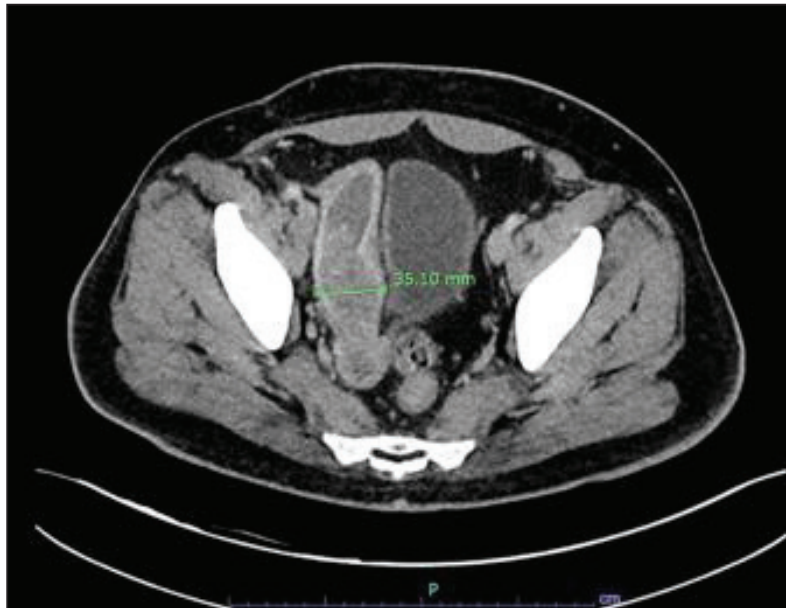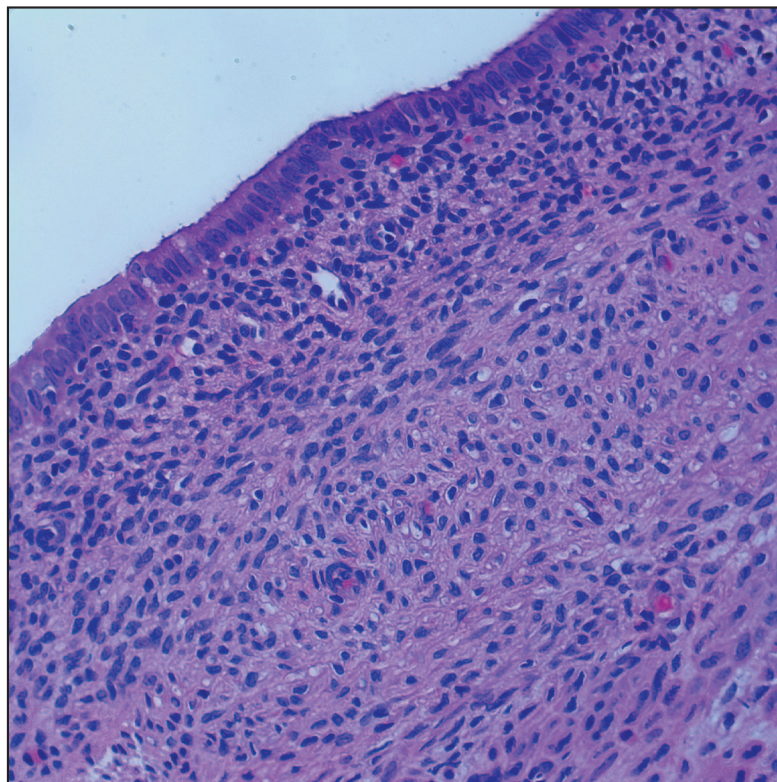


63

64 **Figure 1.** CT of the abdomen and pelvis showing a large heterogeneous tubular mass within the right hemipelvis measuring up to 16.7
65 cm in the region of the right seminal vesicle.



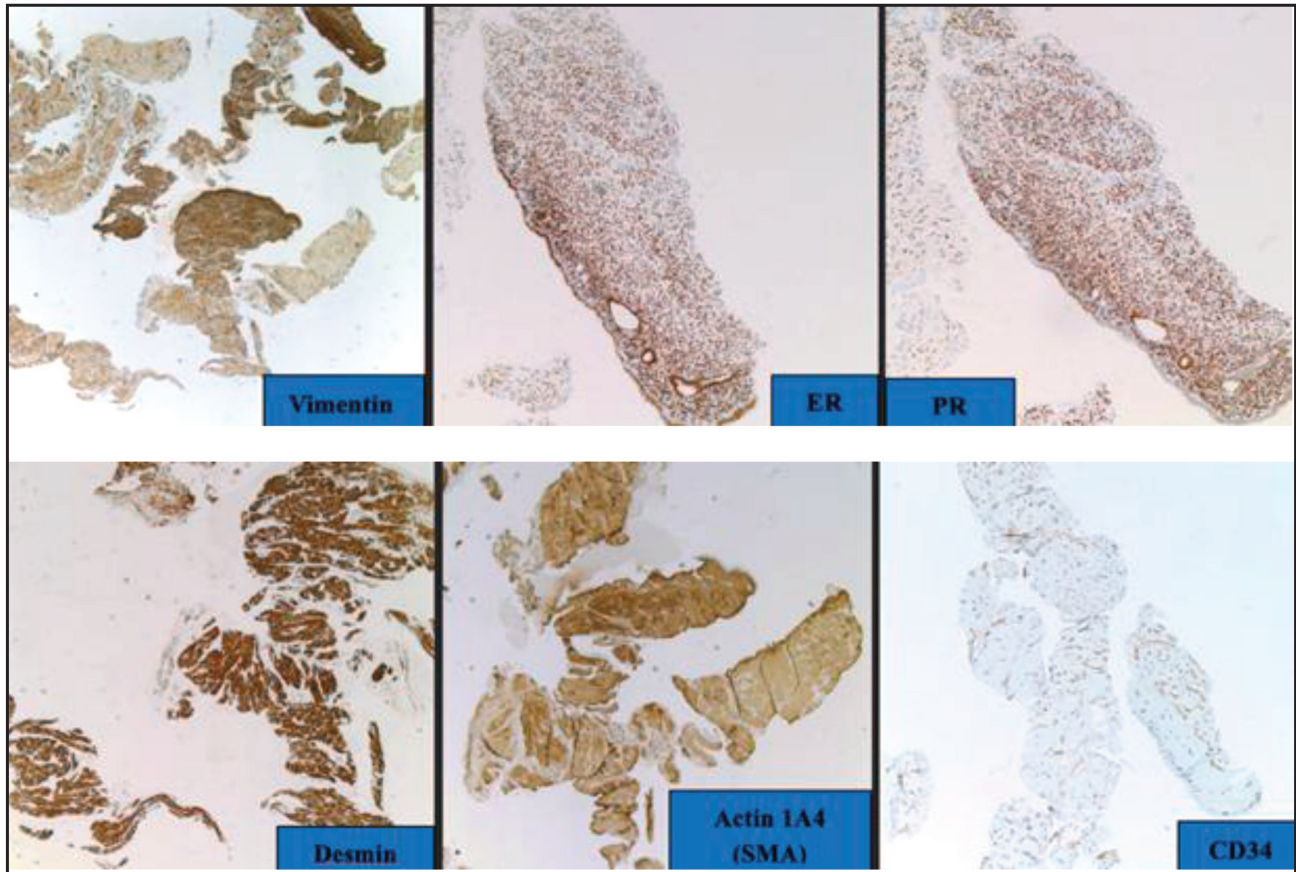
66

67 **Figure 2.** Biopsy of the seminal vesicle mass showing an epithelial proliferation composed of cuboidal to low columnar cells without
68 significant atypia associated with a stromal spindle cell proliferation with focal condensation around the epithelium. Mitotic activity or
69 necrosis were absent (H&E, 20 and 40x objectives, respectively).

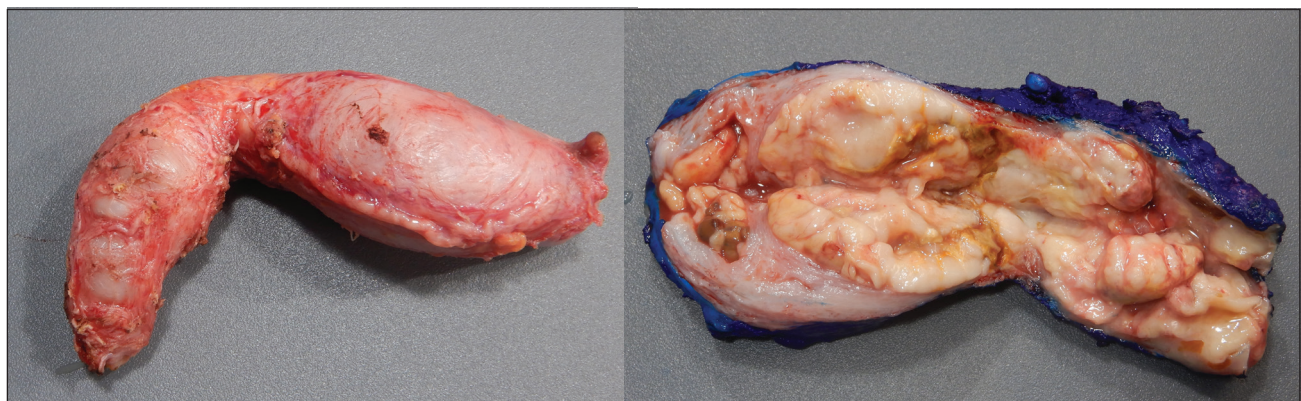
70 A CT-guided biopsy was performed, revealing a spin-
71 dle cell and epithelial proliferation (Figure 2). On immu-
72 nohistochemistry (IHC), the spindle cells were positive for
73 vimentin, estrogen receptors (ER), progesterone receptors
74 (PR), desmin, and actin-1A4 (SMA), while negative for

CD34 (Figure 3). Based on these findings and the histo- 75
76 logic features, a diagnosis of a mixed epithelial and stro-
77 mal tumor (MEST) was favored.

The patient subsequently underwent surgical excision 78
79 of the right seminal vesicle mass. Gross examination



80
81 **Figure 3.** The spindle cells on the biopsy showed positive staining for vimentin, ER, PR, desmin, and actin-1A4 (SMA) and negative for
82 CD34.



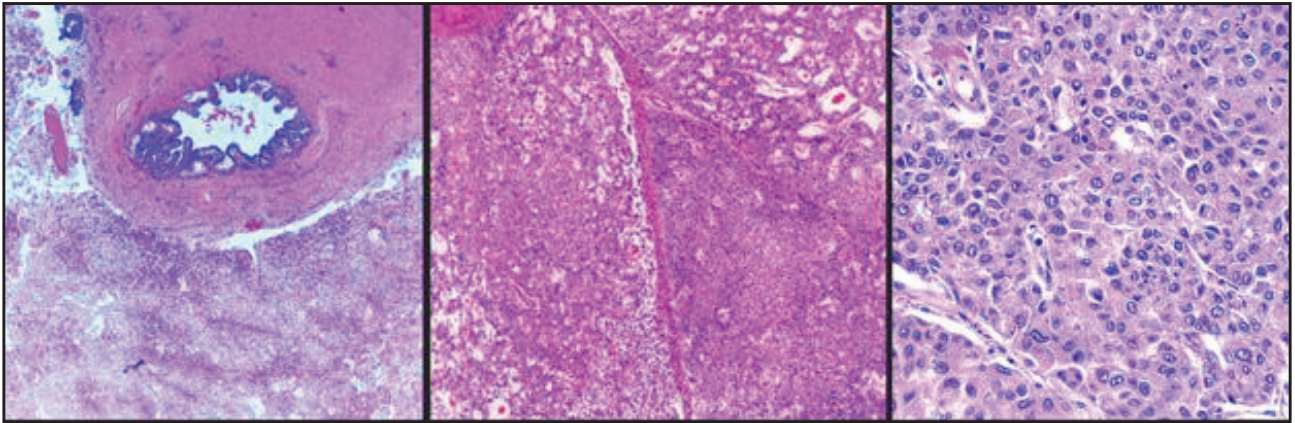
83
84 **Figure 4.** Gross examination of the seminal vesicle mass revealed an elongated tan-pink mass measuring 14 cm in greatest dimension.

85 revealed an elongated, tan-pink, soft tissue mass meas-
86 uring 14 cm in greatest dimension. Sectioning revealed
87 a lobulated, rubbery cut surface with areas of necrosis
88 (Figure 4).

89 On histopathology, the tumor showed solid areas with
90 focal gland formation associated with normal seminal ves-
91 icle epithelium (Figure 5).


92 On immunohistochemistry, the tumor cells were posi-
93 tive for PAX-8, CK7, and CEA (focal), while negative for
94 PSA, PSAP, p63, GATA3, androgen, and CK20 (Figure
95 6). NKX-3 was also negative (not pictured).

In conjunction with the histologic features, this immu- 96
noprofile supported the diagnosis of PSVA. The patient 97
completed three cycles of cisplatin and paclitaxel. 98
Approximately 1.5 years following initial surgical exci- 99
sion, a surveillance MRI showed a 2.5 cm mass in the 100
right ejaculatory duct, suggestive of recurrence. A radical 101
prostatectomy was performed, and microscopic examina- 102
tion revealed an adenocarcinoma with similar morphol- 103
ogy (Figure 7) and identical immunoprofile as the PSVA 104
previously diagnosed (Figure 8). This recurrence did not 105
show invasion into the prostatic stroma or the bladder 106



107
108
109

Figure 5. Microscopic examination revealed malignant cells forming glands along with normal seminal vesicle tissue. A solid component was also identified within the tumor (H&E, 5x, 20x, and 40x objectives, respectively).



110
111
112

Figure 6. The tumor cells were positive for PAX-8, CK7, and CEA (focal), while negative for PSA, PSAP, p63, GATA3, androgen, and CK20.

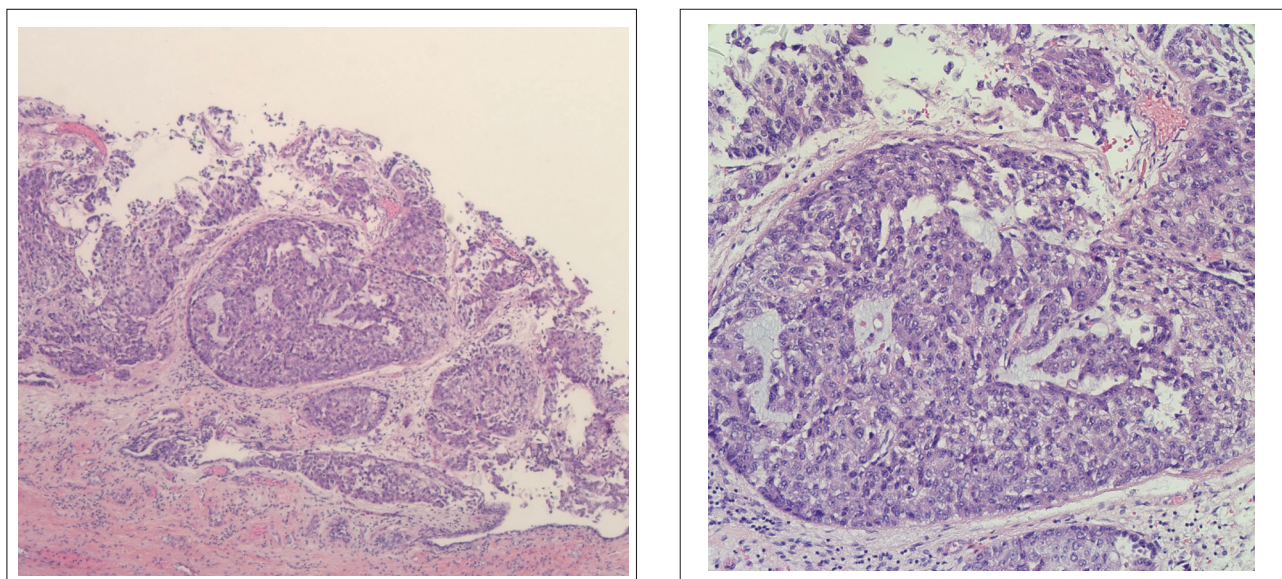


Figure 7. Microscopic examination of the radical prostatectomy revealed an adenocarcinoma with the same morphology as the one previously diagnosed in the right seminal vesicle resection (H&E, 5x and 20x objectives, respectively).

116 neck, was also not identified. Although the patient cur-
 117 rently appears to be asymptomatic, the multidisciplinary
 118 tumor board recommended radiotherapy as a potential
 119 treatment for the recurrence. However, further treatment
 120 has not yet commenced as the patient has missed subse-
 121 quent oncology appointments.

122 **Discussion**

123 In the present case, the biopsy performed prior to the sem-
 124 inal vesicle excision showed only a spindle and epithe-
 125 lial cell proliferation, suggestive of a MEST. This entity
 126 is characterized by a benign epithelial component and a
 127 stromal component that can range from benign to malig-
 128 nant. Given that malignant cells were absent in this ini-
 129 tial biopsy, the tissue sampled likely represents an area
 130 of reactive stromal changes adjacent to the actual PSVA.

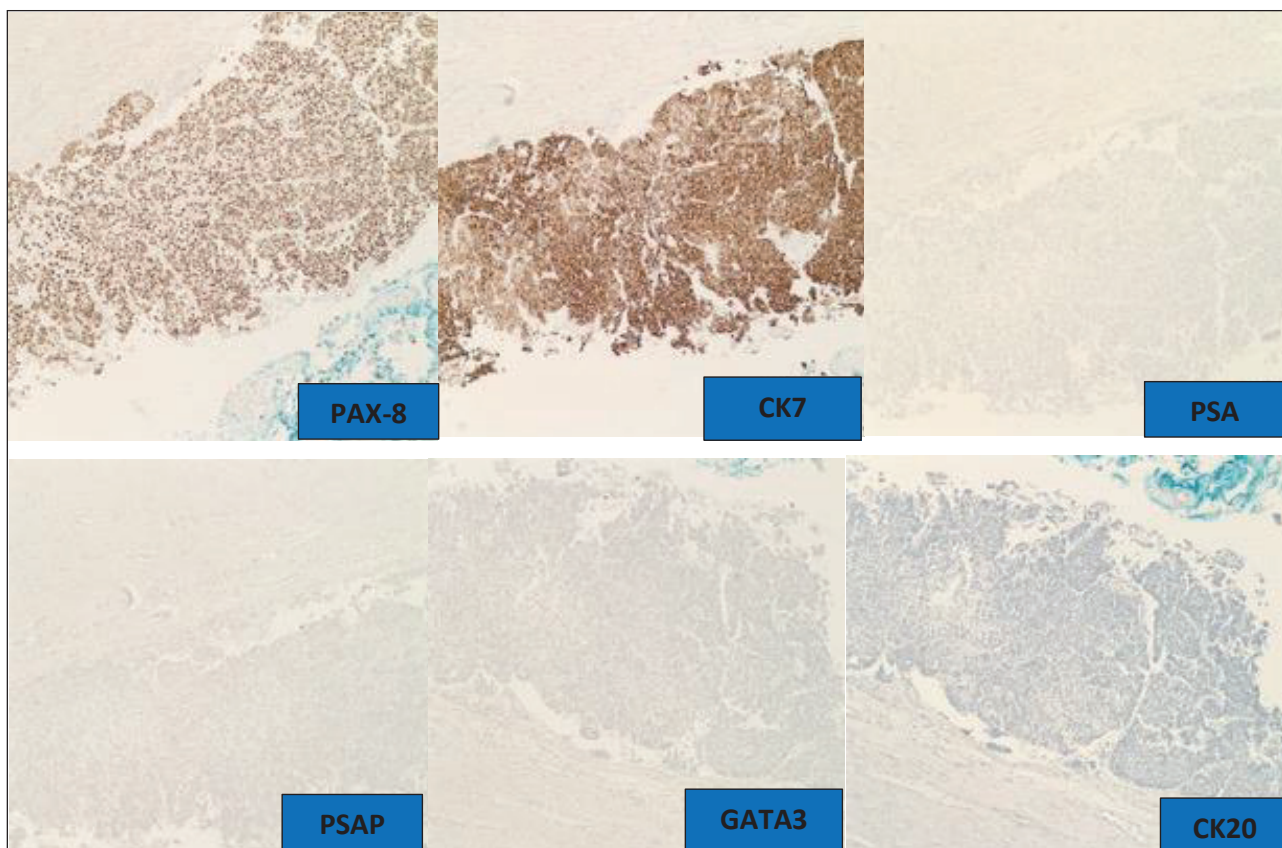
131 Grossly, PSVA may present as a solid mass, as observed
 132 in our case, or as a cystic lesion. Microscopically, most
 133 documented cases are categorized as papillary adenocar-
 134 cinomas, although they may show nested, solid, or cord-
 135 like growth patterns in poorly-differentiated tumors [7].
 136 In our case, the solid pattern was identified.

137 Differentiating PSVA from metastatic involvement of
 138 the seminal vesicles is one of the key tasks for pathol-
 139 ogists when evaluating a seminal vesicle mass. While
 140 there is no IHC stain uniquely specific for PSVA, a panel
 141 of markers is instrumental in narrowing the diagnosis.
 142 To exclude prostatic adenocarcinoma, prostate-specific
 143 (PSA), and prostate-specific acid phosphatase (PSAP) can
 144 be used as most prostatic carcinomas express these mark-
 145 ers. Meanwhile, the use of cytokeratin 7 (CK7) and cyto-
 146 keratin 20 (CK20) in tandem can play an essential role in
 147 differentiating primary seminal vesicle adenocarcinoma

from metastases [8]. Seminal vesicle adenocarcinoma is
 positive for CK7 and negative for CK20, while colorectal
 adenocarcinoma demonstrates a reverse pattern of
 staining. In contrast, urothelial carcinoma of the bladder
 is positive for both CK7 and CK20. Cancer antigen-125
 (CA125), which is positive in PSVA, can also help differ-
 entiate PSVA from prostatic, bladder, and colorectal ade-
 nocarcinomas since those tumors are usually negative [9].
 In a case of PSVA published by Ohmori et al., the tumor
 was a CA125-producing adenocarcinoma, and the patient
 presented high serum levels of this marker [10]. Bladder
 adenocarcinomas and mesotheliomas may also enter into
 the differential diagnosis. Negative immunoreactivity
 with GATA-3 and CK20 would exclude bladder adeno-
 carcinoma, while negative staining with WT1 would help
 exclude mesothelioma.

Currently, there is limited consensus about patient treat-
 ment, management, and follow-up. Standard treatment
 guidelines are not currently available. Once the diagnosis
 is confirmed microscopically, patients should be managed
 by a multidisciplinary team [11]. Most cases have been
 managed with some form of combination of radical sur-
 gery, radiation, chemotherapy, and androgen deprivation
 therapy [11]. In our case, the patient was treated with a
 combination of surgery and chemotherapy.

Given the rarity of PSVA, every documented case
 serves as a vital contribution to the limited body of clinical
 evidence. Our case reinforces the diagnostic necessity of
 a broad IHC panel, specifically the CK7+/CK20-/CA125+
 signature, to reliably distinguish this malignancy from
 more common entities. Our findings provide clinicians
 and pathologists with a refined diagnostic framework and



180
181 **Figure 8.** The tumor cells in the recurrence had the same immunoprofile as the previously diagnosed PSVA.

181 support the continued exploration of aggressive, multidis-
182 ciplinary interventions for PSVA.

183 **Conclusion**

184 Seminal vesicle adenocarcinoma is an extremely rare
185 malignancy; however, it must be considered in the dif-
186 ferential diagnosis of pelvic genitourinary tumors in
187 men. Most cases are diagnosed at an advanced stage of
188 the disease because early clinical signs and symptoms are
189 usually absent or nonspecific. The inclusion of seminal
190 vesicle adenocarcinoma in the differential diagnosis of
191 non-specific lower urinary tract symptoms can ensure an
192 earlier diagnosis. Secondary involvement of the seminal
193 vesicles by adenocarcinomas arising in adjacent organs,
194 such as the prostate and colon, occurs far more commonly
195 and, therefore, metastatic disease should be considered in
196 the differential diagnosis.

197 For challenging cases, immunohistochemistry can
198 assist in differentiating metastatic tumors from PSVA.
199 Both diagnosis and differentiation of PSVA from
200 colorectal, bladder, and prostate carcinomas can be
201 greatly aided by immunohistochemical investigation.
202 Immunohistochemical staining with CA-125 can help in
203 the distinction of PSVA from prostatic, bladder, and rec-
204 tal tumors, since these carcinomas are usually negative.
205 Measurement of serological CA-125 in the clinical eval-
206 uation of men presenting with pelvic masses presumed to

207 have a genitourinary origin is a possible recommendation,
208 considering production of CA-125 by PSVA has been
209 described in the literature.

210 Due to the delayed diagnosis of seminal vesicle ade-
211 nocarcinoma, the prognosis is poor in most cases. Most
212 cases are treated with radical surgery. However, the com-
213 plex anatomy of the area, coupled with the frequent delay
214 in diagnosis, increases the chance of residual disease, as
215 well as the need for adjuvant chemotherapy/radiation.

216 **What is new?**

217 PSVA is a rare malignancy that typically presents with non-
218 specific genitourinary symptoms, often resulting in most
219 cases being diagnosed at an advanced local stage. The
220 underlying pathogenesis remains poorly understood. This
221 case expands the limited literature by highlighting the clin-
222 ical presentation and diagnostic challenges associated with
223 this entity. It further proposes a practical diagnostic frame-
224 work to aid pathologists in the accurate identification of
225 PSVA.

226 **List of Abbreviations**

CA-125	Cancer antigen 125	227
CEA	Carcinoembryonic antigen	228
CT	Computed tomography	229
ER	Estrogen receptor	230
MEST	Mixed epithelial and stromal tumor	231
MRI	Magnetic resonance imaging	232

233 PR Progesterone receptor
 234 PSA Prostate-specific antigen
 235 PSAP Prostatic acid phosphatase
 236 PSVA Primary seminal vesicle adenocarcinoma
 237 SMA Smooth muscle actin

238 Conflict of interest

239 The authors declare that there is no conflict of interest regard-
 240 ing the publication of this article.

241 Ethical approval

242 The Institutional Review Board at Mount Sinai Medical Center
 243 granted approval and waived patient consent. For more infor-
 244 mation, please contact Juan Sabater, MD, Institutional Official
 245 for Research (email: Juan.Sabater@msmc.com /telephone
 246 number: 305-674-2790).

247 Funding

248 None.

249 Author details

250 Vielka Fernandez¹, Arunima Deb¹, Ekim Kilinc¹, Francesca Polit¹,
 251 Elias Atri², Celeste Hall³, Akshay Bhandari², Monica Recine^{1,4},
 252 Yumna Omarzai^{1,4}
 253 1. Department of Pathology and Laboratory Medicine, Mount
 254 Sinai Medical Center, Miami Beach, FL
 255 2. Department of Urology, Mount Sinai Medical Center, Miami
 256 Beach, FL
 257 3. Tufts University School of Medicine , Boston, MA
 258 4. Herbert Wertheim College of Medicine, Florida International
 259 University, Miami, FL

260 References

261 1. Lyons O. Primary Carcinoma of the Left Seminal Vesicle. J
 262 Urology. 1925;13(4):477–84.

2. Bhardwaj N, Rastogi P, Attri VS, Bora GS, Gorski U. Primary seminal vesicle adenocarcinoma: a case report of rare entity and discussion of its differential diagnosis using immunohistochemical approach for the core biopsy specimen. *Andrologia*. 2020;52(3):e13512. <https://doi.org/10.1111/and.13512> 263
 264
 265
 266
 267
 268
 269
 270
 271
 272
 273
 274
 275
 276
 277
 278
 279
 280
 281
 282
 283
 284
 285
 286
 287
 288
 289
 290
 291
 292
 293
 294
 295
 296
 297
 298
 299
 3. Thiel R, Effert P. Primary adenocarcinoma of the seminal vesicles. *J Urology*. 2002;168(5):1891–6. [https://doi.org/10.1016/S0022-5347\(05\)64260-7](https://doi.org/10.1016/S0022-5347(05)64260-7)
 4. Thyavihally YB, Tongaonkar HB, Gupta S, Gujral S. Primary seminal vesicle adenocarcinoma presenting as isolated metastasis to penis responding to chemotherapy and hormonal therapy. *Urology*. 2007;69(4):778.e1–3. <https://doi.org/10.1016/j.urology.2007.01.067>
 5. Sollini M, Silvotti M, Casali M, Giovanardi F, Zadro A, Froio A, et al. The role of imaging in the diagnosis of recurrence of primary seminal vesicle adenocarcinoma. *World J Men’s Health*. 2014;32(1):61–5. <https://doi.org/10.5534/wjmh.2014.32.1.61>
 6. Benson RC, Clark WR, Farrow GM. Carcinoma of the seminal vesicle. *J Urology*. 1984;132(3):483–5.
 7. Bostwick Dg E, J. *Urologic surgical pathology*. Philadelphia. 1997.
 8. Ormsby AE, Haskell R, Ruthven SE, Mylne GE. Bilateral primary seminal vesicle carcinoma. *Pathology*. 1996;28(2):196–200. <https://doi.org/10.1080/00313029600169883>
 9. Stenzel P, Wettach G, Leroy X. Primary seminal vesicle carcinoma. *Int J Surgical Pathol*. 2011;19(3):401–4. <https://doi.org/10.1177/1066896911398359>
 10. Ohmori T, Okada K, Tabei R, Sugiura K, Nabeshima S, Ohoka H, et al. CA125-producing adenocarcinoma of the seminal vesicle. *Pathol Int*. 1994;44(4):333–7. <https://doi.org/10.1111/j.1440-1827.1994.tb03372.x>
 11. Reddy MN, Verma S. Lesions of the Seminal Vesicles and their MRI Characteristics. *J Clin Imag Sci*. 2014;4:61. <https://doi.org/10.4103/2156-7514.143734>

Summary of the case

Patient (gender, age)	51 years old, man
Final diagnosis	Primary seminal vesicle adenocarcinoma
Symptoms	Hematuria, weakness, increased urinary frequency, weak urinary stream, intermittent hematospermia, and mild perineal/suprapubic discomfort
Medications	Losartan, Amlodipine, Hydrochlorothiazide and Glipizide
Clinical procedure	Robotic-assisted right seminal vesicle mass excision
Specialty	Pathology and Urologic Oncology