

From myositis to electrolyte crisis: a case report of dengue-associated rhabdomyolysis and salt wasting syndrome

Jun Keong Lee^{1*}, Ru-Fang Tay¹, Stephanie A.P. Marianathan¹, Katrina Kieng Huong Lau¹, Hui Chin Wong², Thai Lun Tan¹ 

European Journal of Medical Case Reports

Volume 10(2):47–51

DOI: 10.24911/ejmcr.9-2376



This is an open access article distributed in accordance with the Creative Commons Attribution (CC BY 4.0) license: <https://creativecommons.org/licenses/by/4.0/> which permits any use, Share — copy and redistribute the material in any medium or format, Adapt — remix, transform, and build upon the material for any purpose, as long as the authors and the original source are properly cited. © The Author(s) 2026

ABSTRACT

Background: Dengue fever is a common arboviral infection that is typically self-limiting, but rare complications such as myositis, rhabdomyolysis, and electrolyte disturbances can pose diagnostic and therapeutic challenges.

Case Presentation: We report a patient with dengue confirmed by non-structural 1 antigen who initially improved with supportive care but re-presented with severe myalgia, tea-colored urine, and markedly elevated creatine kinase (54,000 U/l), consistent with rhabdomyolysis. Her symptoms were refractory to hydration and analgesia but responded rapidly to corticosteroids. Subsequently, she developed polyuria and profound hypotonic hyponatremia with inappropriately concentrated urine and high urinary sodium, consistent with renal salt wasting syndrome (RSW). Management required careful fluid resuscitation to maintain euvolemia and intermittent desmopressin to control polyuria. Autoimmune screening revealed positive anti-ribonucleoprotein antibodies and anti-Ro antibodies, suggesting an immune-mediated process. She achieved full recovery with normalization of muscle enzymes and electrolytes.

Conclusion: This case highlights the diverse and clinically significant complications of dengue, including immune-mediated myositis and RSW. Importantly, distinguishing RSW from SIADH is crucial, as their treatments differ substantially and misclassification may worsen outcomes.

Keywords: Autoantibodies, dengue, myositis, rhabdomyolysis, salt-wasting syndrome.

Type of Article: CASE REPORT **Specialty:** Infectious Diseases

Correspondence to: Jun Keong Lee

*Department of Internal Medicine, Hospital Tengku Ampuan Rahimah, Klang, Malaysia.

Email: junkeong_01@hotmail.com

Full list of author information is available at the end of the article.

Received: 20 September 2025

Revised (1): 14 November 2025

Accepted: 22 November 2025

Background

Dengue fever is a widespread arboviral infection caused by the dengue virus, primarily transmitted by *Aedes aegypti* mosquitoes. In endemic regions, dengue commonly presents as an acute febrile illness with headache, retro-orbital pain, myalgia, and thrombocytopenia. While the majority of infections are self-limiting, severe or atypical manifestations - including neurological and musculoskeletal complications - are increasingly recognized. Among these, dengue-associated myositis and rhabdomyolysis are rare, and their pathogenesis remains poorly understood. Even more rarely, these musculoskeletal complications are accompanied by secondary electrolyte disturbances, such as salt-wasting syndrome (SWS), posing additional diagnostic and management challenges.

Herein, we report an unusual case of dengue-associated myositis progressing to severe rhabdomyolysis and secondary SWS in a previously healthy girl. Notably, autoimmune serology revealed positive anti-ribonucleoprotein antibodies (anti-RNP) and anti-Ro antibodies, suggesting

an underlying immune-mediated mechanism and raising questions about the intersection of infection and autoimmunity in dengue-related myositis.

Case Presentation

A previously healthy 16-year-old girl from a dengue-endemic region presented to the emergency department (ED) with a 3-day history of fever, generalized myalgia, vomiting, and diarrhea. On arrival, her vital signs showed a temperature of 37.8°C, heart rate of 116 bpm, and blood pressure of 120/70 mmHg. Physical examination was unremarkable. A dengue rapid test was positive for non-structural protein 1 antigen, while dengue IgM and IgG were negative. Laboratory investigations showed hemoglobin 12.6 g/dl, platelets $127 \times 10^3/\mu\text{l}$, white blood cell count $1.66 \times 10^3/\mu\text{l}$, and normal renal, liver, and creatine kinase (CK) levels. She was diagnosed with dengue infection and admitted for monitoring and supportive care. Her initial clinical course was uneventful, and she was discharged on day 8 of illness with mild residual myalgia.

Two days after discharge, she re-presented to the ED with severe progressive myalgia rated 9/10 on a pain scale, which significantly impaired her mobility. She also reported tea-colored urine and poor oral intake. She denied intramuscular injections, use of over-the-counter or traditional medications, and trauma. On examination, her blood pressure was 110/70 mmHg, heart rate 106 bpm, and temperature 36.7°C. There was tenderness over the quadriceps and biceps with reduced proximal muscle power graded 3/5, limited by pain. Deep tendon reflexes and sensation were intact. Laboratory tests revealed urea 3.1 mmol/l, sodium 134 mmol/l, potassium 4.9 mmol/l, creatinine 37.7 μmol/l with CK 54,000 U/l, AST 682 U/l, and lactate dehydrogenase 1,574 U/l on day 10 of illness. Other parameters were unremarkable. Urinalysis showed blood 3+ and ketones 2+. Based on the clinical and biochemical findings, she was diagnosed with dengue-associated myositis complicated by rhabdomyolysis. Hyperhydration was initiated with intravenous normal saline at 2.5 ml/kg/hr, and oral celecoxib 200 mg twice daily was prescribed for analgesia. Despite 3 days of regular celecoxib, her myalgia persisted with a pain score rated 8/10. In view of a possible immune-mediated component, a myositis panel was sent, and oral prednisolone 20 mg once daily was commenced on top of regular celecoxib. A remarkable improvement was observed within 24 hours, with pain reducing to 3/10, and she regained baseline mobility after 3 days of corticosteroid therapy.

Despite initial improvement of her rhabdomyolysis, her clinical course was further complicated by new-onset polyuria, with urine output reaching 4.5 l/day (≈110 ml/kg/day) on day 3, accompanied by an abrupt decline in serum sodium level (Figure 1).

She denied polydipsia, weakness, or numbness. Laboratory evaluation demonstrated hypotonic hyponatremia with inappropriately concentrated urine and high urinary sodium excretion as evidenced by serum osmolality 247 mOsm/kg, urine osmolality 704 mOsm/kg, and urine sodium 165 mmol/l. Serum cortisol and thyroid function were normal. Volume assessment showed clinical hypovolemia, evidenced by dry mucosa, tachycardia, and an inferior vena cava diameter of 0.8 cm with >50% collapsibility. A diagnosis of renal salt-wasting syndrome was made. She was managed with graded fluid resuscitation to maintain euvolemia and close renal profile monitoring. Polyuria resolved after 3 days of graded fluid replacement, and a total of three doses of desmopressin were given. Despite profound hyponatremia, she remained neurologically intact, and rapid correction with hypertonic saline was therefore not pursued. The patient was discharged after 7 days of hospitalization with complete clinical recovery. Importantly, her serum sodium had also normalized alongside with a down-trending CK level (Figure 2).

At follow-up 2 weeks post-discharge, she remained asymptomatic with normal renal function and CK. The myositis antibody panel, reported later, was positive for anti-RNP and anti-Ro antibodies. In view of complete clinical resolution and normal biochemical parameters, she was discharged from further medical follow-up.

Discussion

Dengue is one of the most widespread arboviral infections worldwide, with active transmission reported in over 100 countries, sustained by fluctuations in circulating serotypes and vector ecology [1,2]. Clinically, the infection most often presents as an acute febrile illness with headache, retro-orbital discomfort, musculoskeletal pain, rash, and transient reductions in blood counts, while severe cases are distinguished by plasma leakage and organ dysfunction [1,2]. Less frequently, dengue may involve the neuromuscular system, manifesting as myositis, myopathy, neuropathies, or, in rare cases, rhabdomyolysis, which are thought to arise through both viral and immune-mediated mechanisms [3-5]. In summary, although dengue is usually self-limiting, its potential to produce uncommon neuromuscular complications warrants careful attention to atypical presentations.

The true burden of dengue-associated myositis remains uncertain, as mild muscle involvement may be overlooked. Reported cases describe a broad spectrum - from modest CK elevation with self-limited weakness to severe myositis progressing to rhabdomyolysis. Proposed mechanisms include direct viral invasion of myocytes and immune-mediated injury, with pro-inflammatory signaling, including type I interferon responses, contributing to myofiber damage. Autoantibodies have also been observed in dengue; anti-RNP and anti-Ro positivity have been documented in acute infection, likely reflecting transient immune dysregulation rather than established connective-tissue disease. Consistent with this, transient Antinuclear antibody positivity is known to occur following several viral illnesses and does not, by itself, indicate autoimmune pathology [6]. Histopathological findings from muscle biopsy, when available, often demonstrate necrotic fibers with minimal lymphocytic infiltration, edema, and macrophage predominance, although results may be nonspecific or normal in milder illness [7-9]. In our case, a muscle biopsy was not performed and myositis panel was not repeated as the patient refused for the procedure and myalgia improved significantly with the course of steroid. The development of rhabdomyolysis significantly increases the risk of complications, including acute kidney injury, electrolyte imbalance, cardiac arrhythmias, and compartment syndrome [1,10]. Standard treatment emphasizes aggressive intravenous hydration to maintain renal perfusion, correction of electrolyte abnormalities, and dialysis when indicated [1,10]. Corticosteroids are not typically used for rhabdomyolysis itself, but case reports of dengue-related myositis describe improvement following short

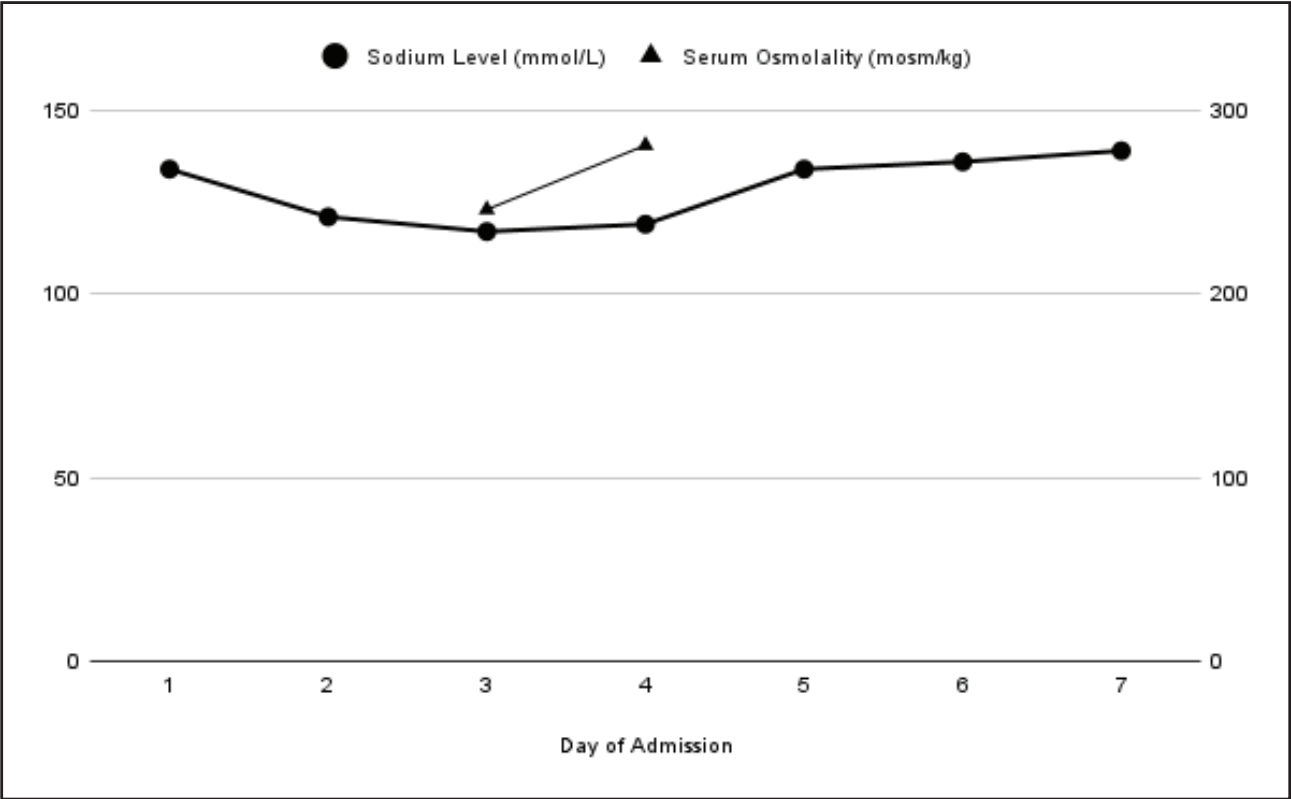


Figure 1. Serum sodium and osmolality trends during second admission.

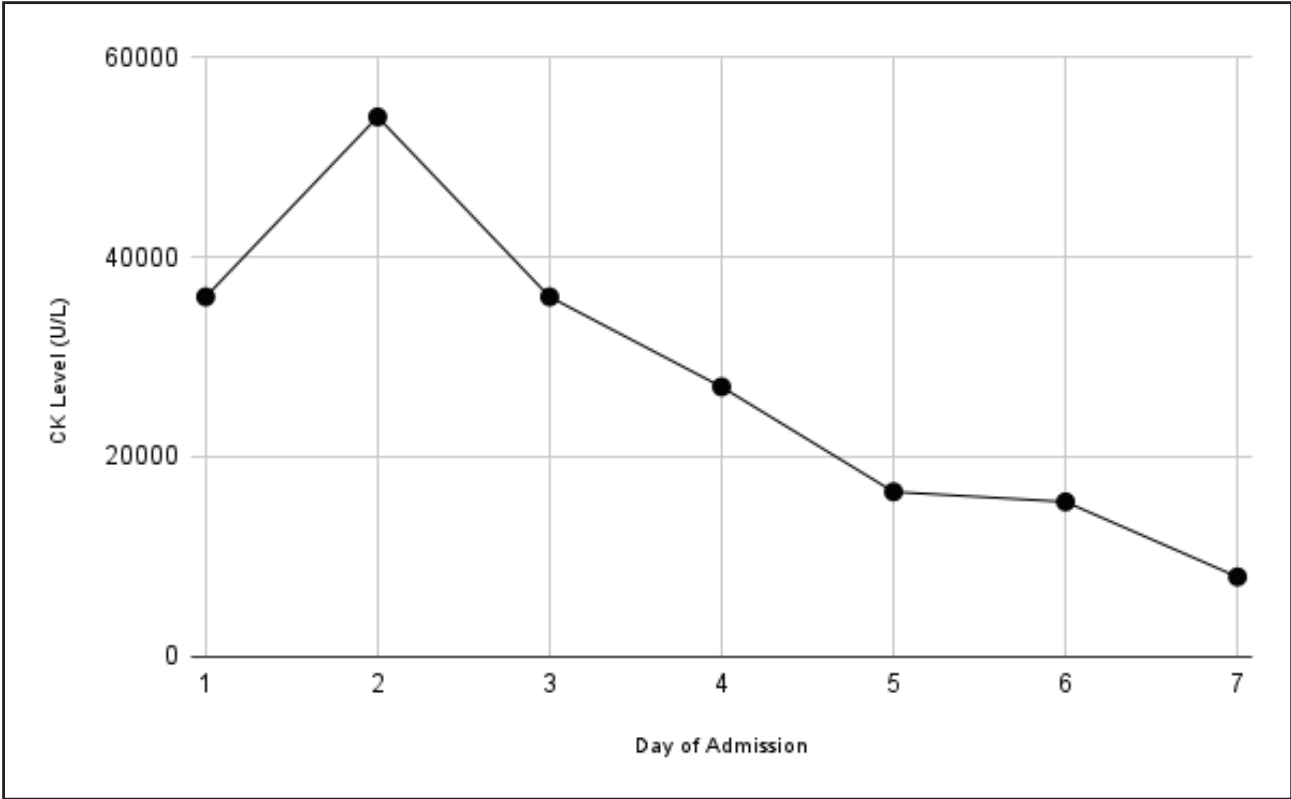


Figure 2. Trend of serum CK levels during second admission.

courses of steroids, suggesting that in select immune-mediated cases, judicious immunomodulation may be beneficial [4,11]. Thus, dengue myositis and rhabdomyolysis reflect

a complex interaction of viral infection and host response, requiring mainly supportive therapy with consideration of steroids in selected contexts.

Hyponatremia is a well-documented metabolic disturbance in dengue and may result from several mechanisms. These include gastrointestinal fluid losses, redistribution of fluids due to vascular leakage, excess antidiuretic hormone activity mimicking SIADH, and, less frequently, RSW [1,4,10]. RSW is typically characterized by hypotonic hyponatremia with clinical hypovolemia, inappropriately high urinary sodium and osmolality, elevated fractional sodium and urate excretion, and rapid correction with isotonic fluids and sodium supplementation. In this case, the presence of clinical hypovolemia, persistently elevated urine sodium, and prompt correction of serum sodium with saline strongly favored RSW over SIADH [12].

This case illustrates the broad systemic complications that dengue may provoke, extending from its classic febrile and hematological manifestations to rarer entities such as myositis, rhabdomyolysis, and secondary renal salt-wasting syndrome. Prompt recognition of these atypical features is vital, as they can lead to severe electrolyte imbalance and renal injury but are often reversible with timely diagnosis and targeted management. The clinical course emphasizes the need for close biochemical surveillance in dengue and supports an individualized therapeutic approach that considers both viral pathogenic mechanisms and host immune responses. Although our patient achieved full recovery, future monitoring for potential autoimmune myopathy may be reasonable given the transient autoantibody positivity and immune-mediated features.

Conclusion

Dengue infection, though typically self-limiting, can rarely present with severe complications such as myositis, rhabdomyolysis, and renal salt-wasting syndrome. This case underscores the role of immune-mediated mechanisms in dengue-associated muscle injury, where corticosteroids may be beneficial. Accurate differentiation of renal salt wasting from SIADH is essential, as management strategies differ. Clinicians should remain vigilant and maintain a high level of suspicion for these uncommon but potentially life-threatening complications of dengue, especially when symptoms worsen after initial recovery.

What is new

Dengue-associated myositis progressing to severe rhabdomyolysis with secondary renal RSW is exceptionally rare, especially in adolescents.

Clear differentiation between RSW and SIADH was demonstrated using clinical volume status, urine indices, and response to isotonic saline - an essential distinction with opposite management strategies.

Positive anti-RNP and anti-Ro antibodies suggest a transient immune-mediated mechanism, highlighting a possible infection - autoimmunity interaction in dengue-related myositis.

List of Abbreviations

| | |
|-------|--|
| ANA | antinuclear antibody |
| CK | creatinine kinase |
| SWS | salt wasting syndrome |
| SIADH | Syndrome of Inappropriate Antidiuretic Hormone Secretion |

Acknowledgments

We gratefully acknowledge Dr. Yong Sy Liang (Head of Medical Department, HTAR) for the invaluable review. Also, we would like to thank the Director General of Health Malaysia for his permission to publish this article.

Conflict of interest

The authors declare no competing interests.

Funding

No funds, grants, or other support were received.

Consent for publication

Written informed consent for publication was obtained from the patient's guardian.

Informed consent

Written informed consent for publication was obtained from the patient's guardian

Ethical approval

This case report has obtained approval from the National Medical Research Register (NMRR), Ministry of Health Malaysia: NMRR ID-25-03232-TL7 Date: 3 September 2025.

Author details

Jun Keong Lee¹, Ru-Fang Tay¹, Thai Lun Tan¹, Stephanie A.P. Marianathan¹, Katrina Kieng Huang Lau¹, Hui Chin Wong²

1. Department of Internal Medicine, Hospital Tengku Ampuan Rahimah, Klang, Malaysia
2. Department of Endocrinology, Hospital Tengku Ampuan Rahimah, Klang, Malaysia

References

1. World Health Organization. Dengue guidelines for diagnosis, treatment, prevention and control: new edition [Internet]. Geneva, Switzerland: World Health Organization (WHO); 2009 [cited 2025 Aug 21]. Available from: <https://iris.who.int/handle/10665/44188>
2. World Health Organization. Dengue and severe dengue [Internet]. [cited 2025 Nov 27]. Available from: <https://www.who.int/news-room/fact-sheets/detail/dengue-and-severe-dengue>
3. Misra UK, Kalita J, Syam UK, Dhole TN. Neurological manifestations of dengue virus infection. *J Neurol Sci*. 2006;244(1–2):117–22. <https://doi.org/10.1016/j.jns.2005.12.017>
4. Garg RK, Malhotra HS, Jain A, Malhotra KP. Dengue-associated neuromuscular complications. *Neurol India*. 2015;63(4):497–516. <https://doi.org/10.4103/0028-3886.162042>
5. Martina BEE, Koraka P, Osterhaus ADME. Dengue virus pathogenesis: an integrated view. *Clin Microbiol Rev*. 2009;22(4):564–81. <https://doi.org/10.1128/CMR.00035-09>
6. Chatterjee RP, Chatterjee S, Roy D, Chatterjee S, Chakraborty N. Detection and differentiation of antinuclear antibodies in serum of dengue suspected patients

- with or without systemic autoimmune disease in Kolkata, India. *Virulence*. 2024;15(1):2400553. <https://doi.org/10.1080/21505594.2024.2400553>
7. Misra UK, Kalita J, Maurya PK, Kumar P, Shankar SK, Mahadevan A. Dengue-associated transient muscle dysfunction: clinical, electromyography and histopathological changes. *Infection*. 2012;40(2):125–30. <https://doi.org/10.1007/s15010-011-0197-6>
 8. Verma R, Holla VV, Kumar V, Jain A, Husain N, Malhotra KP, et al. A study of acute muscle dysfunction with particular reference to dengue myopathy. *Ann Indian Acad Neurol*. 2017;20(1):13–22. <https://doi.org/10.4103/0972-2327.199897>
 9. Filippone C, Legros V, Jeannin P, Choumet V, Butler-Browne G, Zoladek J, et al. Arboviruses and muscle disorders: from disease to cell biology. *Viruses*. 2020;12(6):616. <https://doi.org/10.3390/v12060616>
 10. Diptyanusa A, Phumratanaprapin W. Predictors and outcomes of dengue-associated acute kidney injury. *Am J Trop Med Hyg*. 2021;105(1):24–30. <https://doi.org/10.4269/ajtmh.20-1524>
 11. Gulati K, Pasi R, Gupta A, Ravi KS. Dengue fever presenting with severe myositis—an unusual presentation. *J Fam Med Prim Care*. 2020;9(12):6285–7. https://doi.org/10.4103/jfmprc.jfmprc_1453_20
 12. Supreet K, Avais M, Prit PS, Kyrillos R, Anyelenu E, Arif A. Renal salt wasting: earliest manifestation of rhabdomyolysis (Supreet/Mehandru syndrome). *J Clin Rev Case Rep*. 2022;8(10):239–47. Available from: <https://www.opastpublishers.com/open-access-articles/renal-salt-wasting-earliest-manifestation-of-rhabdomyolysis-supreetmehandru-syndrome-6345.html>

Summary of the case

| | | |
|---|-----------------------|--|
| 1 | Patient (gender, age) | Female, 16 years old |
| 2 | Final diagnosis | Dengue-associated rhabdomyolysis and salt-wasting syndrome |
| 3 | Symptoms | Fever, tea coloured urine and muscle pain |
| 4 | Medications | Corticosteroid, desmopressin |
| 5 | Clinical procedure | Nil |
| 6 | Specialty | Endocrine and infectious disease |