

# Delayed pericarditis in a patient with COVID-19 pneumonia: a case report



Christian C. Toquica Gahona<sup>1,2\*</sup> , Kavin Raj<sup>1,2</sup>,  
 Monarch Shah<sup>1,2</sup>, Kesavan Sankaramangalam<sup>1,2</sup>,  
 Riya J. Shah<sup>3</sup>, Keval V. Patel<sup>1,2</sup>

This is an open access article distributed in accordance with the Creative Commons Attribution (CC BY 4.0) license: <https://creativecommons.org/licenses/by/4.0/> which permits any use, Share — copy and redistribute the material in any medium or format, Adapt — remix, transform, and build upon the material for any purpose, as long as the authors and the original source are properly cited. © The Author(s) 2021

## ABSTRACT

**Background:** Severe acute respiratory syndrome has been implicated in a wide spectrum of cardiovascular complications, from mild elevation in troponins to more severe cases such as pericarditis, cardiac tamponade, and myocarditis. We present a case of delayed onset of pericarditis in a patient with COVID-19 pneumonia.

**Case Presentation:** A 68-year-old woman presented to the emergency department with fever for 5 days, weakness, and fatigue. Diagnosis of COVID-19 pneumonia with superimposed bacterial infection was made. By day 22 of hospitalization, new T wave elevations were seen in cardiac monitoring and confirmation was made with EKG and diagnosis of pericarditis was made. Initial troponin was <0.03 ng/ml and repeated one increased to 1.8 ng/ml (upper limit of normal: 0.12 ng/ml). Treatment was initiated with a high dose of aspirin 650 mg oral daily. Repeat set of troponins downtrended to normal values <0.03 ng/ml. The patient died on day 25 of illness due to worsening shock. Recent reports suggest that the development of fulminant myocarditis and severe cardiac damage experiences a 10-15-day delay following the onset of symptoms from COVID-19 pneumonia, presumably after activated T-cells and macrophages infiltrate myocardial cells. Treatment options include the use of colchicine, corticosteroids, and NSAIDs. Other interventions such as the use of azathioprine, non-human immunoglobulins, and anakinra have been described as well, but there is lack of solid evidence for their benefits.

**Conclusion:** Preliminary information about the mechanisms of developing COVID-19 pericarditis may indicate that colchicine and steroids would be a reasonable treatment option. The efficacy and safety of these medications are to be elucidated.

**Keywords:** ARDS, case report, critical care, COVID-19, pericarditis SARS-CoV2.

Received: 16 March 2021

Accepted: 31 July 2021

Type of Article: CASE REPORT

Specialty: Cardiology

Correspondence to: Christian C. Toquica Gahona

\*Internal Medicine Department, Saint Peters University Hospital, Rutgers-Robert Wood Johnson University Hospital, New Brunswick, NJ.

Email: [christiantoquica@gmail.com](mailto:christiantoquica@gmail.com)

Full list of author information is available at the end of the article.

## Background

The novel coronavirus, also known as severe acute respiratory syndrome coronavirus 2 or SARS-CoV-2, was reported in Wuhan province, China, in December 2019, and since then it has expanded worldwide due to its high infectivity [1]. Coronaviruses are single-stranded RNA enveloped viruses that transmit mainly through aerosolized droplets expelled from the respiratory tract of the primary patient. The clinical

spectrum of COVID-19 infection ranges from asymptomatic states to critically ill cases. SARS-CoV-2 has been implicated in a wide spectrum of cardiovascular complications, from mild elevation in troponins to more severe cases such as pericarditis, cardiac tamponade, and myocarditis [2,3].

We present a case of cardiac involvement as a late complication of SARS-CoV-2 infection.

TIMELINE	DESCRIPTION
Day 3 of illness	Telehealth consult with primary care physician. Prescribed antibiotic course and COVID-19 testing.
Day 5 of illness	Presented to the Emergency Room due to worsening symptoms.
Day 9 of illness	Patient developed rapidly progressive hypoxemia and new retrocardiac opacity in chest X-ray.
Day 12 of illness	Increase in inflammatory markers; started on high dose steroids.
Day 17 of illness	Required intubation for worsening hypoxia and pressors for hypotension.
Day 18 of illness	Started on Continuous renal replacement therapy (CRRT) for renal failure.
Day 27	Peak T wave elevation diffusely in telemetry. EKG revealed diffuse ST wave elevation in most leads, with PR interval depression. Given high dose aspirin and continued with steroids.
Day 28	New right-sided tension in pneumothorax treated with thoracotomy tube insertion.
Day 30	Died from worsening respiratory function and sepsis.

### Case Presentation

A 68-year-old woman presented to the emergency department with fever for 5 days, weakness, and fatigue. She was asymptomatic otherwise with no respiratory symptoms and no sick contacts. Prior to admission, she consulted her primary care physician who prescribed her doxycycline, acetaminophen, and a SARS-CoV2 nasopharyngeal polymerase chain reaction (PCR) test that came back positive. Her past medical history was significant for ulcerative colitis treated with total colectomy and ileostomy, autonomic neuropathy, chronic kidney disease stage 3, and depression. Home medications included midodrine and sertraline.

On admission, the patient was tachycardic and tachypneic with a SpO<sub>2</sub>: 96% on ambient air.

Initial laboratory studies showed elevated C-Reactive Protein (CRP), lactate dehydrogenase (LDH), and ferritin, with low lymphocyte count (Table 1). Patient received treatment with ceftriaxone 1 g/d, enoxaparin 40 mg sq daily and received transfusion with one unit of convalescent plasma for COVID-19. On day 4, the patient developed worsening hypoxia requiring high flow nasal cannula at 40 l and FiO<sub>2</sub>: 100%. A repeat chest X-ray showed new retrocardiac opacity.

On day 7, the patient developed leukocytosis and increase in inflammatory markers including CRP, LDH, and ferritin (Table 1). She was given tocilizumab 4 mg/kg for 2 days, and methylprednisolone 30 mg every 12 hours for a total of 10 days. Full anticoagulation with heparin infusion was started in view of significant elevation in D dimer. By day 12 the patient developed septic shock and was transferred to the intensive care unit where she

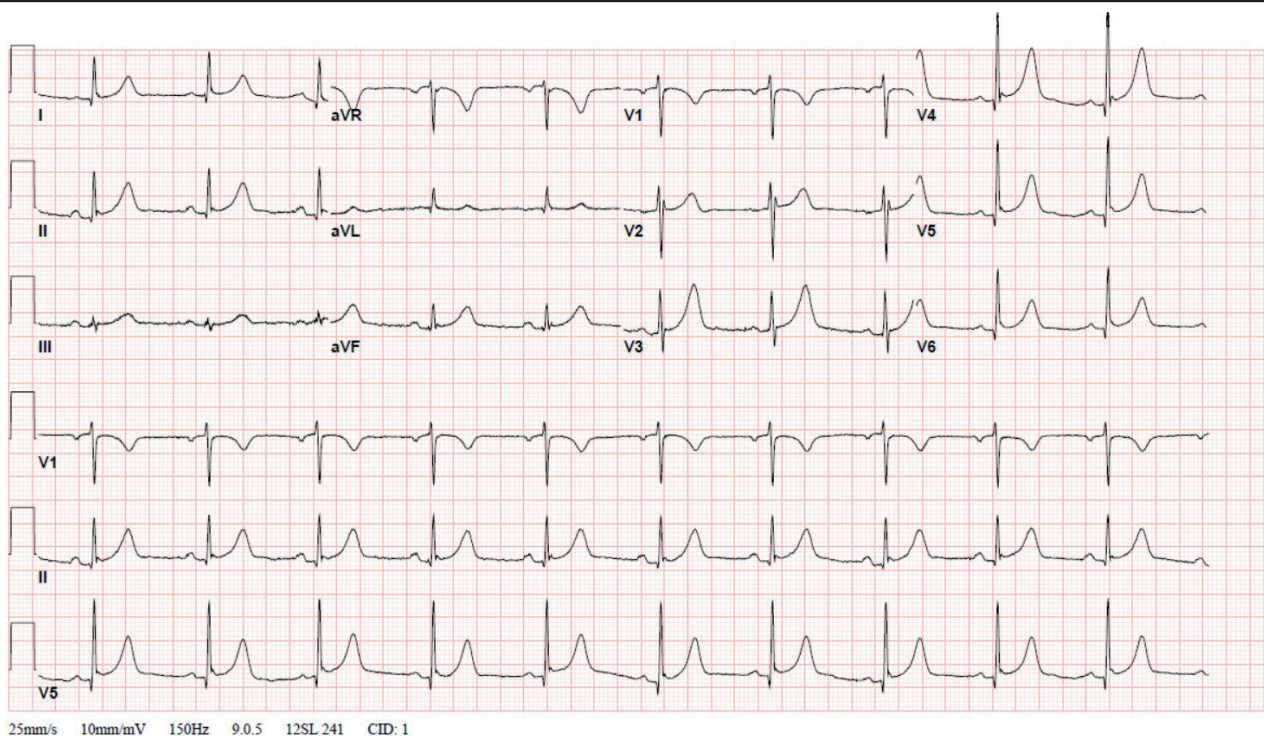
underwent orotracheal intubation and vasopressors nor-epinephrine and vasopressin were started. She became oliguric with worsening renal failure and continuous renal replacement therapy was installed. Miconazole was added empirically due to isolation of yeasts on sputum culture.

On day 22 of hospitalization, the cardiac monitor showed peak T wave elevation diffusely. An Electrocardiogram (EKG) was done and revealed diffuse ST Segment wave elevation with PR segment interval depression in lead II and PR segment elevation on AVR (Figure 1). Initial troponin was <0.03 ng/ml (i.e., normal) and repeated one increased to 1.8 ng/ml (upper limit of normal: 0.12 ng/ml in our laboratory). A transthoracic 2D echo was obtained showing ejection fraction of 60% impaired relaxation and right ventricle systolic pressure of 31 mmHg with no pericardial effusion.

Cardiology was consulted and recommended starting high dose aspirin 650 mg oral daily. Repeat set of troponin downtrended to normal values <0.03 ng/ml. Given the isolation status of the patient, no cardiac Magnetic resonance imaging (MRI) or echocardiogram was performed. The next day the patient developed right-sided pneumothorax treated with thoracostomy tube insertion. Eventually, the patient expired on day 25 of her illness due to worsening shock.

### Discussion

COVID-19 patients are likely to develop multiple cardiovascular complications. This was seen in the first studies conducted by Huang et al. [1] in which 5 out of 41 patients (i.e., 12%) diagnosed with COVID-19 had a high-sensitivity troponin above the threshold of 28 pg/ml.



**Figure 1.** Electrocardiogram showing diffuse ST elevation and PR depressions most noticeable in leads I, II, AVF, and V3-V6, with no reciprocal changes.

**Table 1.** Laboratory studies during hospitalization.

LABORATORY	ADMISSION DAY	DAY 7*	DAY 22**
White blood cell count (WBC) (4.0-11.0 × 10 <sup>3</sup> /μl)	7.1	19.2	33.1
Absolute (ABS) lymphocytes	0.57	0.76	2.33
Hemoglobin (HGB) (12.0-16.0 g/dl)	14.7	13.8	9.6
Platelet (150-400 × 10 <sup>3</sup> /μl)	157	283	153
D-Dimer (0.00-211.00 ng/ml)	209	1,183	
Blood urea nitrogen (BUN) (9-28 mg/dl)	63	46	49
Creatinine (0.52-1.04 mg/dl)	3.48	2.32	1.62
Aspartate aminotransferase (AST) (14-36 U/l)	36	20	57
Alanine aminotransferase (ALT) (9-52 U/l)	20	19	37
CO <sub>2</sub> (21-33 mmol/l)	18	21	25
LDH (140-271 U/l)	337	501	
Lactic acid (0.5-2.0 mmol/l)	1.1		1.9
C-reactive protein (0.0-5.0 mg/l)	38	259	
Ferritin	1,172	1,438	
Troponin-I (<0.12 ng/ml)	<0.03		1.8

\*Day 7: Notorious increase in the inflammatory markers which may correlate with an increase in cytokine release (cytokine storm).

\*\*Day 22: Development of diffuse ST elevation on the cardiac monitor and elevation of cardiac enzymes.

The ECG abnormalities found in patients with COVID-19 may range from non-specific ST segment-T wave abnormalities to full-blown ST-Segment Elevation Myocardial Infarction (STEMI), and differentiating acute coronary syndromes from type 2 myocardial infarction may be challenging. Consequently, cardiology consultation is encouraged if available on managing these cases [4].

The pathogenesis for the development of pericarditis in COVID-19 patients has not been defined yet. One mechanism is the systemic inflammation mediated through cytokine release (cytokine storm) during the 2nd week of symptoms, which are considered one of the major causes for complications including acute respiratory distress syndrome (ARDS) and thoughtfully myocardial injury [5]. Direct infection of the virus has also been identified in a recent study through the presence of positive results for the SARS-CoV-2 genome by PCR in endomyocardial biopsies [6]. Other authors suggest that the development of fulminant myocarditis and severe cardiac damage experience a 10-15-day delay following the onset of symptoms from COVID-19 pneumonia, presumably after activated T cells and macrophages infiltrating myocardial cells [7,8]. This becomes important in evaluating therapeutic options for these patients, including the decrease in leukocyte motility and phagocytosis from colchicine through inhibition of microtubule formation. Colchicine has also been proven to decrease symptoms in patients with pericarditis and has a favorable safety profile, appearing as a reasonable option for treatment of COVID-19 pericarditis [7].

The use of corticosteroids for treatment of viral pericarditis has been controversial. Interestingly, steroids in COVID-19 pneumonia have shown good evidence

for reduction of mortality in recent meta-analysis [9]. However, currently there is only anecdotal data for steroid use in COVID-19 pericarditis.

Regarding the use of Non-steroidal anti-inflammatory drugs (NSAIDs), there is no clear indication of harm, but some authors consider them pertinent for symptom control in patients with COVID-19 pericarditis [10].

Other interventions such as the use of azathioprine, non-human immunoglobulins, and anakinra have been described as well, but there is lack of solid evidence for their benefits [10-13].

We present a case of a late development of pericarditis in a patient with COVID-19 pneumonia and ARDS. To this date, the prevalence of this condition remains unquantified, and a targeted treatment strategy remains indefinable for cases of myocardial injury and pericarditis, and a broad supportive strategy is key.

We over score the need for more clinical research regarding safety and efficacy of the treatment options available, as well as the prognosis of these patients.

### Limitations

This study is limited by the lack of objective evidence of cardiac involvement in MRI or echocardiogram, given the restrictions for personnel exposure during the peak of the pandemic.

### Conclusion

Mortality from COVID-19 may arise from complications related to cytokine storm syndrome including ARDS, pneumothorax, and a vast number of cardiovascular insults.

Patients with COVID-19 pneumonias commonly have elevated cardiac enzymes that seldom indicate myocardial injury. Using diagnostic tools such as ECG and echocardiography may aid in this distinction.

Preliminary information about the mechanisms of developing COVID-19 pericarditis may indicate that colchicine and steroids would be a reasonable treatment option. The efficacy and safety of these medications are to be elucidated.

#### What is new?

SARS-CoV-2 has been implicated in a wide spectrum of cardiovascular complications, from mild elevation in troponins to more severe cases such as pericarditis, cardiac tamponade, and myocarditis.

#### Conflict of interests

The authors declare that there is no conflict of interest regarding the publication of this article.

#### Funding

None.

#### Consent for publication

Consent was obtained from the patient's husband in writing.

#### Ethical approval

Ethical approval is not required at our institution to publish an anonymous case report.

#### Author details

Christian C. Toquica Gahona<sup>1,2</sup>, Kavin Raj<sup>1,2</sup>, Monarch Shah<sup>1,2</sup>, Kesavan Sankaramangalam<sup>1,2</sup>, Riya J. Shah<sup>3</sup>, Keval V. Patel<sup>1,2</sup>

1. Internal Medicine Department, Saint Peters University Hospital, Rutgers-Robert Wood Johnson University Hospital, New Brunswick, NJ
2. Cardiology Department, Saint Peters University Hospital, Rutgers-Robert Wood Johnson University Hospital, New Brunswick, NJ
3. Montgomery High School Skillman, NJ

#### References

1. Huang C, Wang Y, Li X, Ren L, Zhao J, Hu Y, et al. Clinical features of patients infected with 2019 novel coronavirus in Wuhan, China. *Lancet*. 2020;395(10223):497–506. [https://doi.org/10.1016/S0140-6736\(20\)30183-5](https://doi.org/10.1016/S0140-6736(20)30183-5)
2. Sauer F, Dargrenat C, Couppie P, Jochum G, Leddet P. Pericardial effusion in patients with COVID-19: case series. *Eur Heart J Case Rep*. 2020;4(F11):1–7. <https://doi.org/10.1093/ehjcr/ytaa287>
3. Guo T, Fan Y, Chen M, Wu X, Zhang L, He T, et al. Cardiovascular implications of fatal outcomes of patients with coronavirus disease 2019 (COVID-19). *JAMA Cardiol*. 2020;5(7):811–8. <https://doi.org/10.1001/jamacardio.2020.1017>
4. Long B, Brady WJ, Koyfman A, Gottlieb M. Cardiovascular complications in COVID-19. *Am J Emerg Med*. 2020;38(7):1504–7. <https://doi.org/10.1016/j.ajem.2020.04.048>
5. Ye Q, Wang B, Mao J. The pathogenesis and treatment of the cytokine storm in COVID-19. *J Infect*. 2020;80(6):607–13. <https://doi.org/10.1016/j.jinf.2020.03.037>
6. Wenzel P, Kopp S, Gobel S, Jansen T, Geyer M, Hahn F, et al. Evidence of SARS-CoV-2 mRNA in endomyocardial biopsies of patients with clinically suspected myocarditis tested negative for COVID-19 in nasopharyngeal swab. *Cardiovasc Res*. 2020;116(10):1661–3. <https://doi.org/10.1093/cvr/cvaa160>
7. Guzik TJ, Mohiddin SA, Dimarco A, Patel V, Savvatis K, Marelli-Berg FM, et al. COVID-19 and the cardiovascular system: implications for risk assessment, diagnosis, and treatment options. *Cardiovasc Res*. 2020;116(10):1666–87. <https://doi.org/10.1093/cvr/cvaa106>
8. Xu Z, Shi L, Wang Y, Zhang J, Huang L, Zhang C, et al. Pathological findings of COVID-19 associated with acute respiratory distress syndrome. *Lancet Respir Med*. 2020;8(4):420–2. [https://doi.org/10.1016/S2213-2600\(20\)30076-X](https://doi.org/10.1016/S2213-2600(20)30076-X)
9. WHO Rapid Evidence Appraisal for COVID-19 Therapies (REACT) Working Group, Sterne JAC, Murthy S, Diaz JV, Slutsky AS, Villar J, et al. Association between administration of systemic corticosteroids and mortality among critically ill patients with COVID-19: a meta-analysis. *J Am Med Assoc*. 2020;324(13):1330–41.
10. Imazio M, Brucato A, Lazaros G, Andreis A, Scarsi M, Klein A, et al. Anti-inflammatory therapies for pericardial diseases in the COVID-19 pandemic: safety and potentiality. *J Cardiovasc Med (Hagerstown)*. 2020;21(9):625–9. <https://doi.org/10.2459/JCM.0000000000001059>
11. Russell B, Moss C, George G, Santaolalla A, Cope A, Papa S, et al. Associations between immune-suppressive and stimulating drugs and novel COVID-19—a systematic review of current evidence. *Ecantermedscience*. 2020;14:1022. <https://doi.org/10.3332/ecancer.2020.1022>
12. Hu H, Ma F, Wei X, Fang Y. Coronavirus fulminant myocarditis treated with glucocorticoid and human immunoglobulin. *Eur Heart J*. 2021;42(2):206. <https://doi.org/10.1093/eurheartj/ehaa190>
13. Irabien-Ortiz A, Carreras-Mora J, Sionis A, Pamies J, Montiel J, Tauron M. Fulminant myocarditis due to COVID-19. *Rev Esp Cardiol (Engl Ed)*. 2020;73(6):503–4. <https://doi.org/10.1016/j.rec.2020.04.005>

### Summary of the case

1	<b>Patient (gender, age)</b>	Female, 68-year-old
2	<b>Final diagnosis</b>	Delayed onset of pericarditis, ARDS.
3	<b>Symptoms</b>	Shortness of breath, weakness, fatigue, sepsis, shock, and respiratory failure.
4	<b>Medications</b>	Ceftriaxone, heparin IV, enoxaparin, tocilizumab, methylprednisolone, convalescent plasma for COVID-19, and aspirin.
5	<b>Clinical procedure</b>	Ceftriaxone 1 g/d, enoxaparin 40 mg/d, and tocilizumab 4 mg/kg for 2 days, and methylprednisolone 30 mg every 12 hours for a total of 10 days. One unit of convalescent plasma for COVID-19, heparin infusion Activated partial thromboplastin time (APTT) 55-70 seconds, and aspirin 650 mg oral daily
6	<b>Specialty</b>	Cardiology