ANCA-negative granulomatosis with polyangiitis in an elderly patient: a diagnostic and management conundrum - a case report

Malcolm Mintoff*, John Swayne, Andrew Smith and Candice Roufosse

European Journal of Medical Case Reports
Volume XX(XX):XX–XX
DOI: XXXX

OPEN ACCESS

This is an open access article distributed in accordance with the Creative Commons Attribution (CC BY 4.0) license: https://creativecommons.org/licenses/by/4.0/) which permits any use, Share — copy and redistribute the material in any medium or format, Adapt — remix, transform, and build upon the material for any purpose, as long as the authors and the original source are properly cited. © The Author(s) 2026

ABSTRACT

Background: Antineutrophil cytoplasmic antibody (ANCA)-negative granulomatosis with polyangiitis (GPA) is a diagnostically challenging vasculitis often relying on tissue biopsy for the diagnosis.

Case Presentation: Here, we present a 78-year-old male patient of moderate frailty who presented with renal failure requiring hemodialysis. Initial ANCA serology was negative; however, the clinical picture, including rash, neurological disturbances, and MRI findings, remained highly suspicious for vasculitis. Renal biopsy was complicated by bleeding and inadequate tissue sampling. Salvage histopathological techniques using frozen sections and silver stain showed pauci-immune necrotizing crescentic glomerulonephritis and granulomatous tubulointerstitial nephritis, findings highly suggestive of ANCA-negative GPA. Despite tailored treatment, his clinical course was complicated by frailty and hospital-acquired infections.

Conclusion: Negative serology does not exclude GPA and histopathological salvaging techniques are diagnostically valuable when tissue is inadequate.

Keywords: ANCA, GPA, acute kidney injury, dialysis, elderly, Case Report.

Type of Article: CASE REPORT **Specialty:** Nephrology

Correspondence to: Malcolm Mintoff
*Mater Dei Hospital, Imperial College Healthcare NHS Trust, United Kingdom.
Email: malcolm.mintoff.1@gov.mt
Full list of author information is available at the end of the article.

Received: 16 September 2026
Accepted: 31 October 2026

Background

Granulomatosis with polyangiitis (GPA) is a severe subset of antineutrophil cytoplasmic antibody (ANCA) associated vasculitis (AAV) and histologically characterized by necrotizing granulomatous inflammation as well as necrotizing vasculitis of small- to medium-sized blood vessels [1]. Pauci-immune glomerulonephritis is seen in most cases in those with renal involvement [2].

ANCA autoantibodies are typically positive in GPA. Proteinase-3 (PR3) ANCA can be seen in 80%-90% of ANCA positive cases [3], while myeloperoxidase (MPO)-ANCA positive and ANCA negative are seen in a smaller proportion of patients [4]. Although ANCA status is not necessary for diagnosis of GPA, it has both prognostic and clinical implications when managing such patients.

GPA is a multisystemic disease, which may involve the ear, nose and throat system, lungs, and/or kidneys. Constitutional symptoms of malaise, fatigue, and weight loss may also occur [5,6].

GPA is considered a rare disease with a prevalence of about 2.3-146 cases per million [7] and is especially prominent in the elderly with a peak incidence at 65-75 years of age [8]. Immunosenescence is considered to be a contributing factor in the pathogenesis of disease in the elderly [9].

Clinical Case

We present a 78-year-old gentleman with a past history of hypertension, ischemic heart disease, porcine aortic valve replacement, and moderate frailty (Rockwood Frailty Score of 6) [10] who presented with acute kidney injury, hemoproteinuria, and oligoanuria. A timeline of events is summarized in Table 1.

Prior to the admission, he reported a few day history of non-specific abdominal pain, diarrhea, and reduced oral intake. His observations were normal with a blood pressure of 118/70 mmHg, pulse rate of 81 bpm, and oxygen saturations of 97% on room air. Serum creatinine was 1428 umol/L increased from a baseline of (about) 110-120 umol/L. CRP was markedly elevated at 165 mg/L. Total white cell count was also elevated with prominent neutrophilia (22.6 and 19.6 × 10^9/L, respectively). Hemoglobin was 9 g/dl, and platelets were slightly higher than his previous results at 274 × 10^9 /L. Serum albumin was

Table 1. *Timeline of events.*

Timeline	Clinical Milestone and Diagnostic/Therapeutic Events
Day 0-1	**Presentation:** Severe acute kidney injury/renal failure; initial vasculitis screen sent (ANCA, C3/C4, anti-GBM). Emergency hemodialysis initiated
Day 14-15	First renal biopsy attempted; aborted secondary to sudden acute confusion. MRI Brain: findings consistent with possible neurovasculitis.
Day 25	**Renal biopsy performed**. PET scan: no systemic vasculitis. **Complication:** Post-biopsy perinephric hematoma/bleeding detected; successful renal angiography and selective arterial embolization performed.
Day 26	***Empiric Treatment:*** *Systemic corticosteroids consisting of Prednisolone 0.75 mg/kg/day (60 mg/day) initiated for suspected vasculitis.*
Day 33	***Infection:*** *Hospital-acquired pneumonia (HAP) diagnosed; empiric piperacillin/tazobactam started. No renal recovery noted with steroids; encephalopathy markedly improved.*
Day 46	*Final histopathology (silver stain of frozen immunofluorescence sample): pauci-immune necrotizing crescentic glomerulonephritis with granulomatous tubulointerstitial nephritis, consistent with granulomatosis with polyangiitis (GPA).*
Day 47-48	*Planned targeted rituximab held due to acute respiratory and neurological deterioration*
Day 52-55	Worsening pulmonary infiltrates confirmed on chest X-ray; bacteraemia: Blood cultures positive for *Enterococcus faecalis*; sensitive to piperacillin/tazobactam
Day 56	**Final Outcome:** Patient clinically deteriorated secondary to severe sepsis/septic shock and passed away.

Table 2*. Vasculitis screen, dates performed.*

Date	Test	Result	Units	Reference range
19-Jul-2025	Anti-Nuclear Antibody (Serum)	(<1/100)		
19-Jul-2025	Complement 3 (Serum)	434	mg/L	900-1800
19-Jul-2025	Complement 4 (Serum)	208	mg/L	100-400
19-Jul-2025	Free light chains, type kappa (serum)	433	mg/L	6.7-22.4
19-Jul-2025	Free light chains, type lambda (serum)	434	mg/L	8.3-27.0
19-Jul-2025	Free light chains, type ratio	0.999	ratio	0.31-1.56
19-Jul-2025	Anti-myeloperoxidase antibody (serum)	<2.0	U/mL	0.0-20.0
19-Jul-2025	Anti-proteinase 3 antibody (Serum)	17.3	U/mL	0.0-20.0
19-Jul-2025	Anti-streptolysin 'O' (Serum)	123	IU/mL	0-200
24-Jul-2025	Anti-glomerular basement membrane antibody (serum)	<2.0	U/mL	0.0-20.0
24-Jul-2025	Rheumatoid Factor IgM (serum)	630	IU/mL	0-15.9
24-Jul-2025	IgG (serum)	20.4	g/L	7.01-16.0
24-Jul-2025	IgM (serum)	1.28	g/L	0.40-2.30
24-Jul-2025	IgA (Serum)	3.47	g/L	0.70-4.00
08-Aug-2025	Cryoglobulins	Negative		

significantly low at 20 g/L. Urinalysis revealed hemoproteinuria. A CT of the abdomen and pelvis showed splenic infarcts and bilateral pleural effusions, while kidneys and urinary tract appeared normal. Immediate management consisted of intravenous fluids, antibiotics, and omission of his anti-hypertensive regimen including an angiotensin converting enzyme inhibitor.

Hemodialysis was initiated the following day for fluid overload with anuria.

An immune panel revealed the presence of a significantly elevated rheumatoid factor (630 IU/ml) and low C3. Anti-GBM, ANA, immunoglobulins, cryoglobulins, serum protein electrophoresis, and free light chain ratio were within normal limits. Initial cryoglobulin levels were reported as weakly positive, but subsequent testing was negative. ANCA testing, including MPO and PR3 testing, was also negative. An echocardiogram and transesophageal echocardiography excluded the presence of endocarditis, and blood cultures were negative from the date of admission. A summary of vasculitis screen is in Table 2.

The patient later developed confusion, and MRI of the brain demonstrated extensive, confluent periventricular, and deep white matter hyperintensities suggestive of diffusion restriction affecting the right and left frontal lobes and left parietal lobe. Discussions with the neurology team about these acute findings were suggestive of neurovasculitis (Figure 1). He later developed a purpuric rash, initially involving the lower limbs before becoming

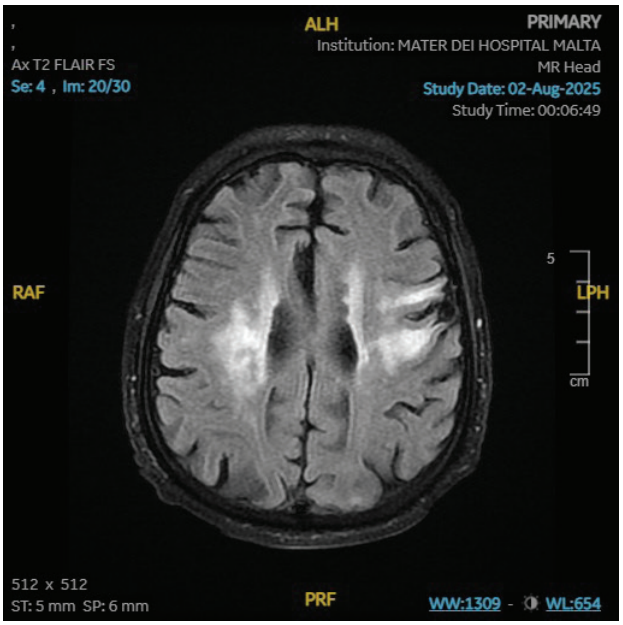

Figure 1. *Axial T2-FLAIR MRI of the brain demonstrating extensive, confluent periventricular, and deep white matter hyperintensities, along with subcortical hyperintensity involving the left frontoparietal region*

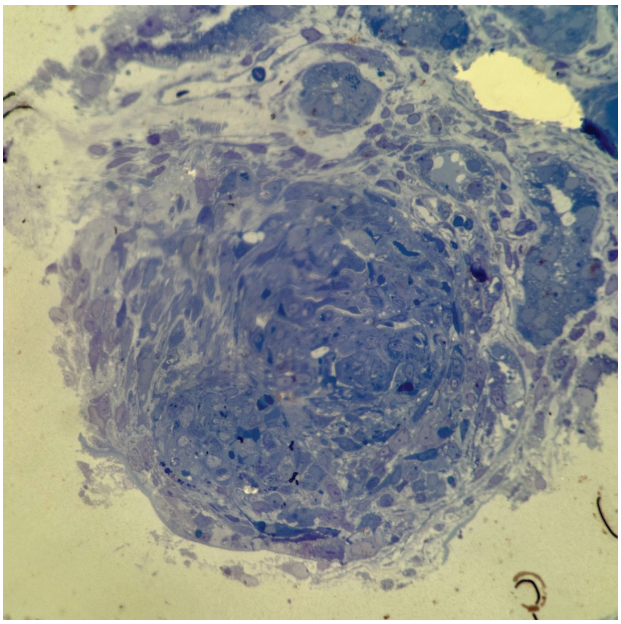

Figure 2. *Toluidine Blue. The section demonstrates necrotizing granulomatous tubulointerstitial nephritis.*

more diffuse and affecting the upper limbs and trunk. A skin biopsy revealed florid leukocytoclastic vasculitis. A renal biopsy was performed followed by a PET/CT, which excluded the presence of medium and large vessel vasculitis. The patient was started empirically on intravenous prednisolone 0.75 mg/kg/day for a systemic vasculitis while awaiting the preliminary biopsy reports. The prednisolone dose was gradually tapered down over a span of 4 weeks to 25 mg daily in accordance with the recommended KDIGO guidelines [12].

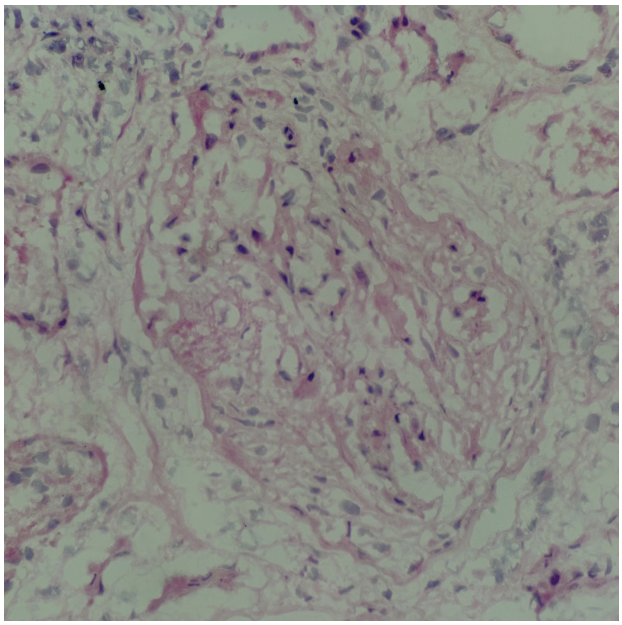

Figure 3. *Frozen section, H&E Stain. The section demonstrates a glomerulus, but the morphology cannot be reliably interpreted.*

The biopsy was complicated by a post-biopsy bleed requiring embolization of two renal vessels.

The formalin-fixed light microscopy sample did not contain renal parenchyma and was therefore unsuitable for analysis. Review of the toluidine blue staining (Figure 2) prepared for electron microscopy showed the presence of necrotizing granulomatous tubulointerstitial nephritis. In view of the patient's frailty and inability to undergo repeat biopsy, salvage techniques were employed. An unstained sample from the frozen section reserved for immunofluorescence was processed for silver staining (Jones/PAM). This successfully demonstrated necrotizing glomerulonephritis with crescents in thirteen of the twenty glomeruli (Figures 3-5), with four out of twenty glomeruli obsolete and an otherwise normal appearance of the remaining three glomeruli. Tubulointerstitial scarring was reflected by interstitial fibrosis and tubular atrophy in 20%-30% of the cortex. Together with negative immunofluorescence and the absence of deposits on electron microscopy, the findings were compatible with pauci-immune necrotizing glomerulonephritis with crescents and granulomatous tubulointerstitial nephritis. In the context of his clinical presentation, this supported a diagnosis of ANCA-negative GPA [2,7].

Renal improvement was not achieved with steroids alone, and he remained dialysis dependent. The encephalopathy and skin rash subsequently improved following steroid therapy, which is suggestive of a steroid responsive illness. Treatment with rituximab (alongside steroid therapy) was originally planned once a definitive diagnosis was made but deferred because of the emergence of bronchopneumonia and bacteriaemia. The patient sadly

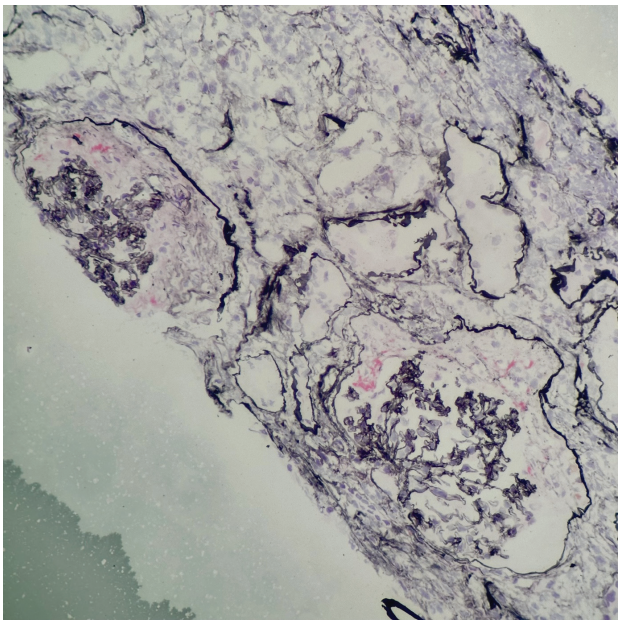

Figure 4. *Frozen section, Jones Silver Stain. The section demonstrates segmental necrosis and crescent formation in two glomeruli together with tubulointerstitial nephritis.*

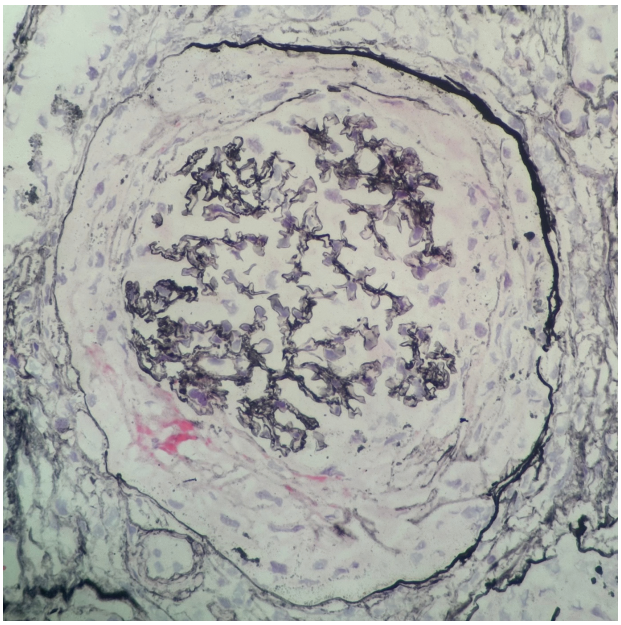

Figure 5. *Frozen section, Jones Silver Stain. The section demonstrates segmental necrosis and crescent formation in a glomerulus.*

passed away due to sepsis despite targeted antibacterial treatment.

Discussion

Early investigations taken to attempt to unmask the underlying disease process posed numerous challenges. A high rheumatoid factor and low C3 may correlate with various infective (hepatitis C, tuberculosis, and other viral infections), auto-immune (rheumatoid arthritis and systemic lupus erythematosus), and malignancy aetiologies. Cryoglobulins were not detected, and cryoglobulinemia was excluded.

Pauci-immune necrotizing crescenteric glomerulonephritis with granulomatous interstitial nephritis is associated with various conditions [2,7,17].

The lack of eosinophilia and eosinophilic infiltrates on biopsy make eosinophilic GPA less likely. Granulomata are not typical in microscopic polyangiitis [1,7].

Necrotizing granulomatous tubulointerstitial nephritis can be seen with sarcoidosis as well as mycobacterial infections.[11] Sarcoidosis may rarely present with necrotizing granulomatous disease, but clinical diagnostic criteria were insufficient. Typical features of sarcoidosis such as bilateral hilar lymphadenopathy, hypercalcemia, and an elevated serum ACE, for example, were not present. A quantiFERON test for latent or active tuberculosis was indeterminate, and this was likely due to the ongoing steroid therapy. There was no history of infection or auto-immune disease, and screening panels ruled out the presence of such illnesses. Renal limited ANCA-associated vasculitis would not present with granulomata on biopsy, and the majority are ANCA positive . [7]

When small vessel vasculitis is suspected alongside a positive ANCA titre, immunosuppressive treatment should not be delayed if a renal biopsy has not yet been performed [12]. Although the ANCA titer was within normal limits, a strong clinical suspicion for such disease warranted empirical steroid therapy prior to histological diagnosis. KDIGO guidelines typically recommend rituximab and / or cyclophosphamide alongside steroids for induction therapy in AAV. Medical management in this case was ultimately determined by clinical discretion. Given the patient's frail premorbid condition, the difficulty in obtaining a prompt diagnosis and the significant bleed complicating the kidney biopsy, combination immunosuppressive regimens from the outset were deemed not to be in the patient's benefit. Similarly, plasma exchange was considered an extraordinary measure. Avacopan is not available locally. Rituximab is well tolerated in the elderly population and is preferable in induction and remission phase therapy over cyclophosphamide [12]. Rituximab administration was abandoned due to the emergence of severe sepsis.

Since the standard light microscopy specimen was insufficient and a repeat biopsy was not feasible in this case, salvage staining of frozen tissue reserved for immunofluorescence offered an invaluable alternative. The unconventional process provided the necessary tissue diagnosis without exposing the patient to another risky biopsy.

Prompt, intensive therapy for patients with GPA to improve outcomes and preventing progression to established end-stage kidney disease is paramount. Patient frailty, however, is associated with higher mortality and

longer hospital stays and should be factored in when managing such patients [13,14].

Glucocorticoids are the cornerstone of induction remission therapy. Reduced steroid dosage regimens are used to alleviate the side effects. [12]. Higher dose steroids in the elderly, especially within the first 3 months of therapy are associated with treatment related significant complications such as fatal infections [15].

Conclusion

The report describes a case with numerous obstacles both in the diagnosis and management of a patient with ANCA-negative GPA.

ANCA-negative GPA occurs in about 10-15% of patients [3]. Although empirical therapy was initiated early on, obtaining a definitive diagnosis through kidney biopsy was delayed due to the patient's clinical state. The histopathological analysis was unconventional in the fact that the sample was devoid of renal cortex, and silver staining of the frozen section was performed. The significant renal bleed post biopsy and background chronic disease on biopsy made renal recovery less likely and a further attempt at renal biopsy inappropriate.

GPA-related renal vasculitis in the elderly is often severe, necessitating intensive immunosuppressive regimens carefully tailored to the patient's susceptibility to life-threatening infections and other drug-related adverse events. Therapy was administered to attempt to manage the patient's neurological, skin, and renal sequelae of a suspected systemic vasculitis and to prevent other life-threatening events such as pulmonary hemorrhage from occurring. The patient sadly passed away from infection despite early broad-spectrum antibiotic therapy preceded by judicious steroid taper during the induction phase and long-term outcomes of therapy could not be assessed.

Elderly patients are unfortunately underrepresented in ANCA vasculitis clinical trials despite the peak incidence of disease in the seventh and eighth decades [16,17]. Results are thus largely drawn from results pertaining to younger individuals who may present and respond differently to older patients. Future trials should be attempted to assess the management of vasculitis in the elderly. Furthermore, current recommendations do not specify the treatment needs for those with ANCA-negative vasculitis and further research in this area is needed.

List of abbreviations

AAV	ANCA-associated vasculitis
ANA	Antinuclear antibody
ANCA	Antineutrophil cytoplasmic antibodies
Anti	GBM: Anti-glomerular basement membrane
GPA	Granulomatosis with polyangiitis
MPO	Myeloperoxidase
PR3	Proteinase 3
TOE	Transoesophageal echocardiogram

Conflict of interests

The authors declare that there is no conflict of interest regarding the publications of this article.

Funding

None.

Consent for publication

Written informed consent was obtained from the next kin of the patient.

Ethical approval

Ethical approval is not required at our institution to publish an anonymous case report.

Author details

Malcolm Mintoff, John Swayne, Andrew Smith and Candice Roufosse[1]

Mater Dei Hospital, Imperial College Healthcare NHS Trust, United Kingdom.

What is new

Salvaging techniques in ANCA- negative vasculitis. Delayed differential due to lack of positive vasculitis screen. Difficult in treatment due to patients age and comorbidities.

References

1. Rasmussen N. SP0065 the 2012 revised international chapel hill consensus conference nomenclature of the vasculitides. Ann Rheum Dis. 2012;71:16. https://doi.org/10.1136/annrheumdis-2012-eular.1540.
2. Jennette JC, Nachman PH. ANCA glomerulonephritis and vasculitis. Clin J Am Soc Nephrol. 2017;12(10):1680–91. https://doi.org/10.2215/cjn.02500317.
3. Bossuyt X, Cohen Tervaert JW, Arimura Y, Blockmans D, Flores-Suárez LF, Guillevin L, et al. Position paper: revised 2017 international consensus on testing of ancas in granulomatosis with polyangiitis and microscopic polyangiitis. Nat Rev Rheumatol. 2017;13(11):683–92. https://doi.org/10.1038/nrrheum.2017.140.
4. Hagen EC, Daha MR, Hermans J, Andrassy K, Csernok E, Gaskin G, et al. Diagnostic value of standardized assays for anti-neutrophil cytoplasmic antibodies in idiopathic systemic vasculitis. EC/BCR project for ANCA assay standardization. Kidney Int. 1998;53(3):743–53. https://doi.org/10.1046/j.1523-1755.1998.00807.x.
5. Seo P, Stone JH. The antineutrophil cytoplasmic antibody-associated vasculitides. Am J Med. 2004;117(1):39–50. https://doi.org/10.1016/j.amjmed.2004.02.030.
6. Hoffman GS, Kerr GS, Leavitt RY, Hallahan CW, Lebovics RS, Travis WD, et al. Wegener granulomatosis: an analysis of 158 patients. Ann Intern Med. 1992;116(6):488–98. https://doi.org/10.7326/0003-4819-116-6-488.
7. Kitching AR, Anders HJ, Basu N, Brouwer E, Gordon J, Jayne DR, et al. ANCA-associated vasculitis. Nat Rev Dis Primers. 2020;6(1):71. https://doi.org/10.1038/s41572-020-0204-y.
8. Watts RA, Mooney J, Skinner J, Scott DG, Macgregor AJ. The contrasting epidemiology of granulomatosis with polyangiitis (wegener's) and microscopic polyangiitis. Rheumatology (Oxford). 2012;51(5):926–31. https://doi.org/10.1093/rheumatology/ker454.

9. López-Otín C, Blasco MA, Partridge L, Serrano M, Kroemer G. The hallmarks of aging. Cell. 2013;153(6):1194–217. https://doi.org/10.1016/j.cell.2013.05.039.
10. Moorhouse P, Rockwood K. Frailty and its quantitative clinical evaluation. J R Coll Physicians Edinb. 2012;42(4):333–40. https://doi.org/10.4997/jrcpe.2012.412.
11. Janssen U, Naderi S, Amann K. Idiopathic granulomatous interstitial nephritis and isolated renal sarcoidosis: two diagnoses of exclusion. SAGE Open Med. 2021;9:20503121211038470. https://doi.org/10.1177/20503121211038470.
12. Kidney Disease: Improving Global Outcomes (KDIGO) ANCA Vasculitis Work Group, Flöge J. Corrigendum to "KDIGO __ic_title_3__ for the Management of Antineutrophil Cytoplasmic Antibody (ANCA)-Associated Vasculitis." kidney international 2024;105(3S):S71–S116. https://publications.rwth-aachen.de/record/1007502
13. Chang SF, Lin HC, Cheng CL. The relationship of frailty and hospitalization among older people: evidence from a meta-analysis. J Nurs Scholarsh. 2018;50(4):383–391. https://doi.org/10.1111/jnu.12397.
14. Boucher EL, Gan JM, Rothwell PM, Shepperd S, Pendlebury ST. Prevalence and outcomes of frailty in unplanned hospital admissions: a systematic review and meta-analysis of hospital-wide and general (internal) medicine cohorts. EClinicalMedicine. 2023;59:101947. https://doi.org/10.1016/j.eclinm.2023.101947.
15. Weiner M, Goh SM, Mohammad AJ, Hrušková Z, Tanna A, Sharp P, et al. Effect of treatment on damage and hospitalization in elderly patients with microscopic polyangiitis and granulomatosis with polyangiitis. J Rheumatol. 2020;47(4):580–588. https://doi.org/10.3899/jrheum.190019.
16. Thietart S, Karras A, Augusto JF, Philipponnet C, Carron PL, Delbrel X, et al. Evaluation of rituximab for induction and maintenance therapy in patients 75 years and older with antineutrophil cytoplasmic antibody-associated vasculitis. JAMA Netw Open. 2022;5(7):e2220925. https://doi.org/10.1001/jamanetworkopen.2022.20925.
17. Sattui SE, Jiang B, Fu X, Cook C, Srivatsan S, Williams ZK, et al. The effects of age and frailty on the risks of end-stage renal disease, death, and severe infection in older adults with antineutrophil cytoplasmic antibody-associated vasculitis: a retrospective cohort study. Lancet Rheumatol. 2024;6(11):e771–e779. https://doi.org/10.1016/s2665-9913(24)00193-0.

Summary of case

1	**Patient (gender, age)**	Male, 78 years old
2	**Final diagnosis**	ANCA-negative granulomatosis with polyangiitis
3	**Symptoms**	Renal failure, rash, confusion
4	**Medications**	Steroids
5	**Clinical procedure**	Dialysis
6	**Specialty**	Nephrology