EJMCR EJMCR EJMCR EJMCR EJMCR

Endoscopic submucosal dissection for simultaneous four foci of multiple primary early-stage esophageal cancer after tongue cancer surgery: a case report

Xiaona Ni[1], Tong Lin[1], Xingxing Wang[2], Xiaodong Chen[1]*

European Journal of Medical Case Reports
Volume 10(12):489–494
DOI: 10.24911/ejmcr.9-3038

OPEN ACCESS

This is an open access article distributed in accordance with the Creative Commons Attribution (CC BY 4.0) license: https://creativecommons.org/licenses/by/4.0/) which permits any use, Share — copy and redistribute the material in any medium or format, Adapt — remix, transform, and build upon the material for any purpose, as long as the authors and the original source are properly cited. © The Author(s) 2026

ABSTRACT

Background: Multiple primary early-stage esophageal cancer is not uncommon in patients with head and neck squamous cell carcinoma, but simultaneous four foci after tongue cancer surgery is rarely reported.

Case Presentation: A 67-year-old male with a history of tongue base squamous cell carcinoma (pT1N0M0) treated by radical surgery in 2018 presented with dysphagia in 2024. Gastroscopy revealed four separate iodine-unstained areas in the esophagus. All four lesions were completely resected by endoscopic submucosal dissection (ESD) in a single procedure. Pathology confirmed three lesions as pT1a and one as pT1b (submucosal invasion, ~0.2 mm), all with negative margins. The patient received adjuvant radiotherapy (50 Gy/25 fractions) for the pT1b lesion. At 1.5 years post-surgery, follow-up computed tomography, barium meal, and serum squamous cell carcinoma antigen showed no recurrence or metastasis, although follow-up endoscopy had not yet been performed.

Conclusion: This case suggests that head and neck cancer patients require regular esophageal screening after surgery. ESD can achieve complete (R0) endoscopic resection for multiple synchronous early-stage esophageal cancers. Additional oncological treatment should be considered for pT1b lesions.

Keywords: Esophageal neoplasms, multiple primary cancers, endoscopic submucosal dissection, field cancerization, radiotherapy.

Type of Article: CASE REPORT **Specialty:** Gastroenterology

Correspondence to: Xiaodong Chen
*Endoscopy Center, the Second Affiliated Hospital of Shantou University Medical College, Shantou, Guangdong, China.
Email: xiaodongchen0712@163.com
Full list of author information is available at the end of the article.

Received: 25 July 2026
Revised (1): 08 October 2026
Accepted: 11 October 2026

Background

Simultaneous multiple primary early-stage esophageal cancer in patients with head and neck squamous cell carcinoma has been increasingly recognized. The reported incidence of multiple primary cancers in patients with head and neck squamous cell carcinoma ranges from 9.5% to 21.9%. The concept of "field cancerization," first proposed by Slaughter et al. [1], suggests that the entire upper aerodigestive tract mucosa is exposed to long-term carcinogenic factors, leading to widespread genetic and epigenetic alterations and predisposing to multicentric, independent carcinogenesis [2,3].

However, cases of simultaneous four foci of early-stage esophageal cancer after tongue cancer surgery, all treated by endoscopic submucosal dissection (ESD), are rarely reported in the literature. Here, we present a rare case of a patient who developed four synchronous early-stage esophageal squamous cell carcinomas 6 years after radical surgery for tongue cancer, all successfully treated by ESD in a single procedure. The patient also received adjuvant radiotherapy for a pT1b lesion and remained without detected recurrence at 1.5 years of follow-up.

Case Report

A 67-year-old male patient presented to our hospital in October 2024 with a chief complaint of dysphagia for 2 months. In 2018, the patient had undergone radical surgery for left tongue base well-differentiated squamous cell carcinoma (pT1N0M0) at the Cancer Hospital. The surgical procedure included left tongue base wide excision, left cervical lymph node dissection, and flap reconstruction. Postoperative recovery was uneventful, and regular follow-up until 2023 showed no evidence of recurrence or metastasis. The patient had a long history of smoking (40 years, 20 cigarettes/day) and alcohol consumption (30 years, approximately 100 ml of white liquor/day). There was no family history of esophageal cancer or head and neck tumors.

Gastroscopy revealed four separate iodine-unstained areas in the esophagus (Figure 1), located at approximately

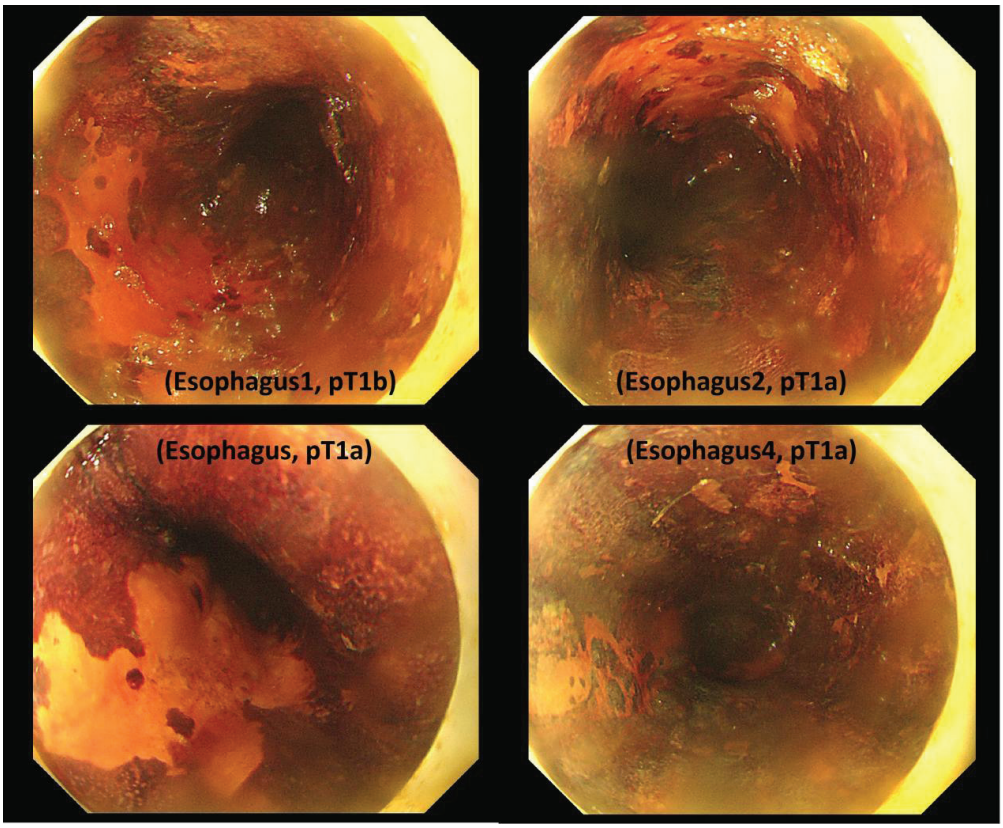

Figure 1. *Iodine staining of the esophagus (four lesions). A: Lesion 1 (25–28 cm from incisors, left posterior wall), approximately 3.0 × 2.0 cm, iodine-unstained area with clear margins and positive pink-color sign; B: Lesion 2 (28–31 cm from incisors, anterior wall), approximately 3.0 × 2.8 cm, extensive iodine-unstained area; C: Lesion 3 (32–35 cm from incisors, left lateral wall), approximately 2.5 × 2.5 cm, large patchy iodine-unstained area; D: Lesion 4 (37–38 cm from incisors, left lateral wall), approximately 1.0 × 0.5 cm, irregular iodine-unstained area. The surrounding normal squamous epithelium appears brown-black (iodine-positive). The lesions appear unstained or lightly stained due to intracellular glycogen loss, with clear margins and positive pink-color sign, consistent with the endoscopic features of early esophageal cancer.*

25-28 cm (lesion 1, left posterior wall, approximately 3.0 × 2.0 cm), 28-31 cm (lesion 2, anterior wall, approximately 3.0 × 2.8 cm), 32-35 cm (lesion 3, left lateral wall, approximately 2.5 × 2.5 cm), and 37-38 cm (lesion 4, left lateral wall, approximately 1.0 × 0.5 cm) from the incisors. Narrow-band imaging (NBI) with magnification demonstrated irregular intraepithelial papillary capillary loops (IPCL) in all four lesions, classified as type B1 according to the Japan Esophageal Society classification, with focal type B2 vessels observed in lesion 1 (Figure 2). Endoscopic ultrasound suggested that all lesions were confined to the mucosal layer with intact submucosa and no enlarged lymph nodes.

After obtaining informed consent, all four lesions were resected by ESD in a single procedure. En bloc resection was achieved for all lesions, with operative times of 40, 35, 30, and 20 minutes for lesions 1 through 4, respectively. Intraoperative bleeding was minimal and was controlled by electrocoagulation. No perforation or delayed bleeding occurred.

Postoperative pathology (Figure 3, Table 1) confirmed that all four lesions were moderately differentiated squamous cell carcinoma. Three lesions (lesions 2, 3, and 4) invaded the lamina propria mucosa (pT1a), and one lesion (lesion 1) invaded the submucosa to a depth of approximately 0.2 mm (pT1b). According to the Japan Esophageal Society classification, submucosal invasion of ≤200 μm is classified as SM1 (T1b-SM1), and invasion >200 μm is classified as SM2/3. A depth of exactly 200 μm is categorized as SM1, as the boundary is defined at ≤200 μm. All resection margins were negative, and no lymphovascular or perineural invasion was identified.

The patient was discharged on postoperative day 5 without feeding difficulties. Because lesion 1 was pT1b (SM1), with an estimated lymph node metastasis risk of 10%-20% after ESD, additional oncological treatment was recommended after multidisciplinary discussion. The patient was considered for surgery, chemoradiotherapy, and radiotherapy alone. Given the patient's history of multiple primary cancers, the presence of four synchronous lesions, and the relatively limited depth of submucosal invasion (SM1), the multidisciplinary team considered that the risk of residual nodal disease was relatively low and that organ-preserving radiotherapy alone would be appropriate. The patient also expressed a preference for avoiding surgery. Therefore, adjuvant radiotherapy alone

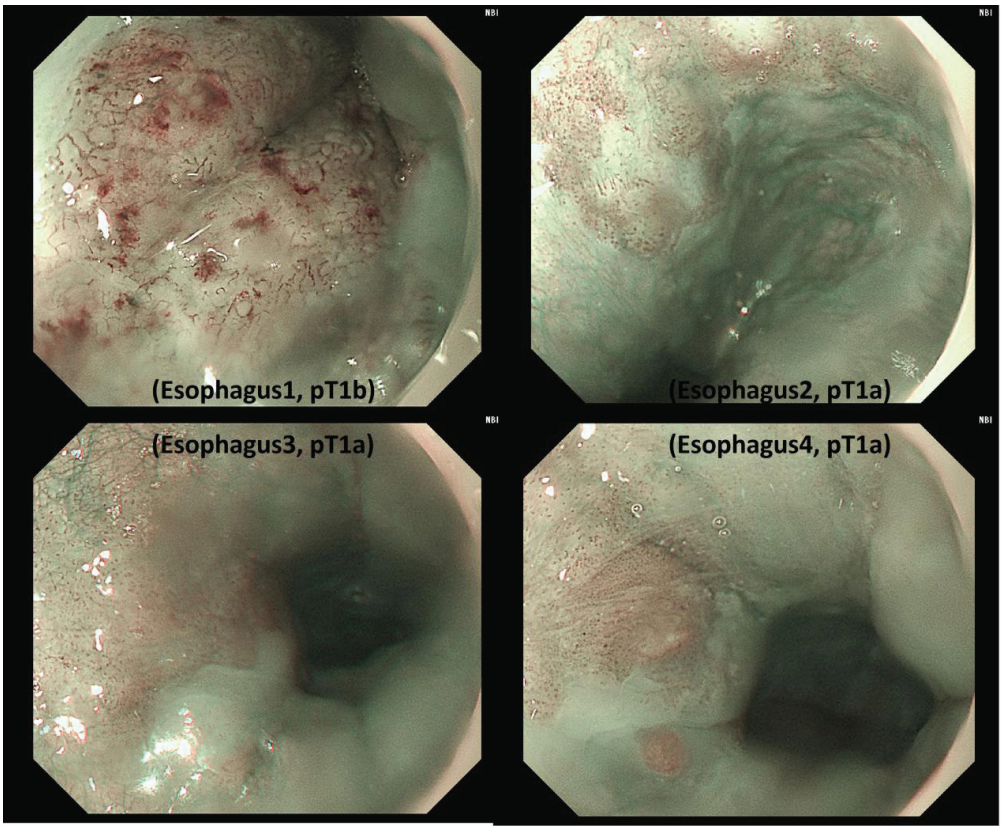

Figure 2. *NBI with magnification (four lesions). A: Lesion 1 (25-28 cm, left posterior wall): IPCL predominantly B1 type with focal B2 type vessels (vessel destruction, unlooping, and marked dilatation with irregular morphology), suggesting possible superficial submucosal invasion; B: Lesion 2 (28-31 cm, anterior wall): IPCL predominantly B1 type with irregular, tortuous, and dilated vessels, with a clear demarcation line; C: Lesion 3 (32-35 cm, left lateral wall): IPCL B1 type with irregular vessels, with a clear demarcation line; D: Lesion 4 (37-38 cm, left lateral wall): IPCL B1 type showing tortuous, dilated, and uneven-caliber vessels, with a clear demarcation line. A clear demarcation line is visible in all four lesions. According to the Japan Esophageal Society classification, B1 type vessels correspond to high-grade intraepithelial neoplasia/carcinoma in situ (Tis/T1a), while B2 type vessels suggest possible superficial submucosal invasion (T1b-SM1).*

(50 Gy in 25 fractions) was delivered, starting 6 weeks after ESD. The treatment was well tolerated, with only mild radiation esophagitis managed symptomatically.

At 1.5 years post-surgery, follow-up chest computed tomography (CT) showed no esophageal wall thickening or mediastinal lymphadenopathy. Esophageal barium meal revealed good esophageal contraction with no filling defects or strictures. Serum squamous cell carcinoma antigen level was 1.23 ng/ml (reference range: 0.50-2.70 ng/ml), which was within normal limits. However, follow-up endoscopy with iodine staining was not performed at this time point; therefore, the possibility of small local or metachronous mucosal lesions cannot be excluded.

The patient remained generally well without dysphagia or chest pain. At 1.8 years post-surgery, the patient was diagnosed with active pulmonary tuberculosis complicated by tuberculous pericarditis and is currently receiving anti-tuberculosis treatment with stable condition. Gastroscopy with iodine staining is planned once the tuberculosis is adequately controlled.

Discussion

Simultaneous multiple primary early-stage esophageal cancer is not uncommon in clinical practice. The reported incidence of multiple primary cancers in patients with head and neck squamous cell carcinoma ranges from 9.5% to 21.9% [2,3]. However, cases with four simultaneous foci successfully treated by ESD remain rare in the literature. Our case has several distinctive features: (1) the patient developed four synchronous esophageal cancers 6 years after radical tongue cancer surgery, which strongly supports the field cancerization theory [4,5]—the entire upper gastrointestinal squamous epithelium, chronically exposed to carcinogens, becomes a “cancerized field” with independent carcinogenesis at different sites and times; (2) all four lesions were early-stage squamous cell carcinoma, with three pT1a and one pT1b; and (3) all lesions achieved complete (R0) endoscopic resection by ESD. For lesion 1, which showed pT1b (SM1) invasion, additional radiotherapy was administered; no recurrence was detected at 1.5 years of follow-up.

The field cancerization theory, first described by Slaughter et al. [1], suggests that the squamous epithelium

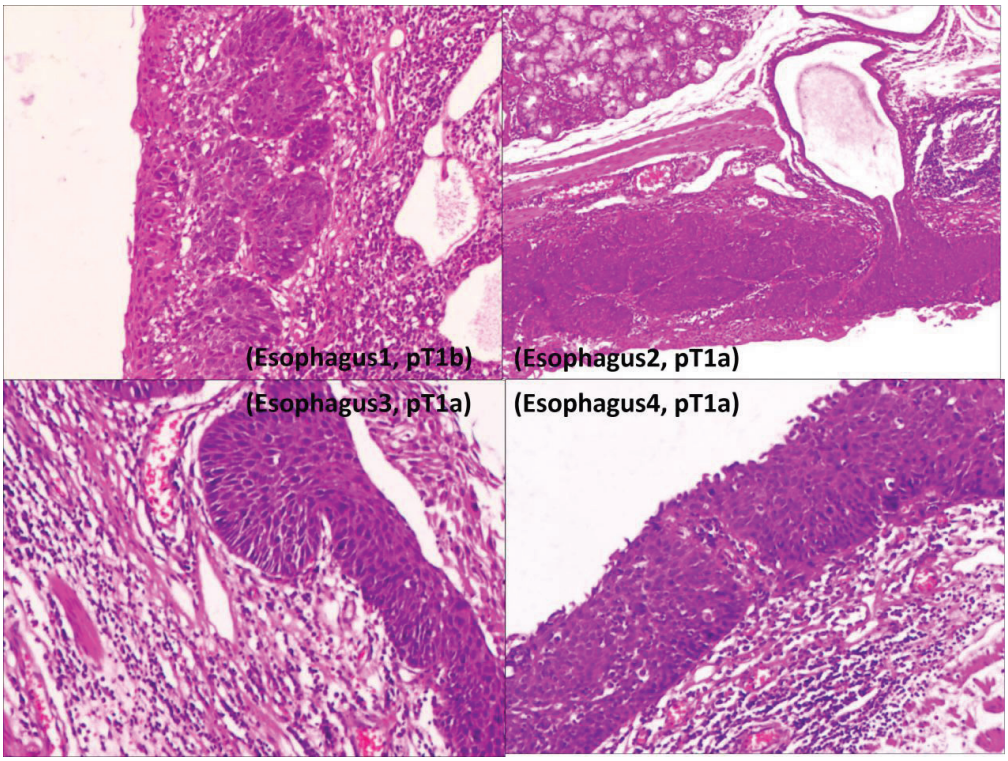

Figure 3. *Postoperative pathology (hematoxylin-eosin staining, ×40) (four lesions). A: Lesion 1 (HE, ×40): moderately differentiated squamous cell carcinoma, invading the submucosa to a depth of approximately 0.2 mm (200 μm), pathological stage pT1b; B: Lesion 2 (HE, ×40): moderately differentiated squamous cell carcinoma, carcinoma in situ with focal superficial invasion into the lamina propria mucosa, negative margins, pathological stage pT1a; C: Lesion 3 (HE, ×40): moderately differentiated squamous cell carcinoma, carcinoma in situ with focal superficial invasion into the lamina propria mucosa, negative margins, pathological stage pT1a; D: Lesion 4 (HE, ×40): moderately differentiated squamous cell carcinoma, carcinoma in situ with focal invasion into the lamina propria mucosa, negative margins, pathological stage pT1a. No lymphovascular or perineural invasion was identified in any of the four lesions. Oral, anal, lateral, and basal margins were all negative. Lesions 2, 3, and 4 are pT1a; lesion 1 is pT1b (invasion depth approximately 0.2 mm).*

Table 1. *Pathological characteristics of the four lesions after ESD.*

LESION	LOCATION (FROM INCISORS)	SIZE (CM)	DEPTH OF INVASION	PT STAGE	DIFFERENTIATION	MARGINS
Lesion 1	25-28 cm, left posterior wall	3.0 × 2.0	Submucosa, ~0.2 mm	pT1b	Moderately	Negative
Lesion 2	28-31 cm, anterior wall	3.0 × 2.8	Lamina propria	pT1a	Moderately	Negative
Lesion 3	32-35 cm, left lateral wall	2.5 × 2.5	Lamina propria	pT1a	Moderately	Negative
Lesion 4	37-38 cm, left lateral wall	1.0 × 0.5	Lamina propria	pT1a	Moderately	Negative

of the oral cavity, pharynx, and esophagus, under prolonged exposure to carcinogens such as tobacco and alcohol, undergoes widespread genetic mutations and epigenetic changes, resulting in multicentric, non-contiguous carcinogenesis [6,7]. The presence of normal mucosal intervals between the four lesions in our patient further supports this theory. Therefore, regular esophageal screening with iodine staining and NBI magnification is strongly recommended for patients with a history of head and neck squamous cell carcinoma. Although the optimal surveillance interval remains to be established, annual or biennial endoscopic examination appears reasonable based on the available evidence [8].

ESD is currently the preferred treatment for early-stage esophageal cancer, with en bloc and curative resection rates exceeding 90%. For pT1a esophageal squamous cell carcinoma, ESD is an absolute indication because the risk of lymph node metastasis is extremely low (<2%) [9]. For pT1b lesions, the risk of lymph node metastasis increases significantly (10%-20%) and requires further stratification by depth of invasion [10,11]. The Japan Esophageal Society classification defines SM1 as submucosal invasion ≤200 μm and SM2/3 as invasion >200 μm. Lesions with SM1 invasion have a controversial benefit from additional treatment after ESD, whereas SM2/3 lesions are generally recommended for additional surgery or chemoradiotherapy. In our case, the depth of invasion of lesion 1 was exactly 0.2 mm (200 μm), which is classified as SM1 [12]. After multidisciplinary discussion, considering the patient's history of multiple primary cancers, the presence

of four synchronous lesions, the relatively limited depth of submucosal invasion (SM1), and the patient's preference for organ preservation, a more aggressive strategy with additional radiotherapy was chosen.

Regarding adjuvant radiotherapy after ESD, there is currently no consensus. Japanese studies comparing prophylactic doses (40-41.4 Gy) with higher doses (50-61.2 Gy) [13,14] have shown that in areas receiving ≥50 Gy, no lymph node recurrence was observed, whereas the prophylactic-dose area still had a 5% recurrence rate [15]. Our patient received 50 Gy/25 fractions. It should be noted that this was adjuvant radiotherapy without concurrent chemotherapy, which is distinct from definitive chemoradiotherapy. No recurrence was detected at the 1.5-year follow-up. However, given the single-patient nature of this report and the relatively short follow-up, these findings cannot establish the effectiveness of this strategy, and further studies are needed.

It is worth noting that the field cancerization state of the patient's esophageal mucosa persists, and the remaining esophagus remains at high risk. This underscores the importance of regular endoscopic surveillance [16]. Although gastroscopy with iodine staining has not been performed at 1.5 years post-surgery due to patient preference and subsequent active pulmonary tuberculosis, combined follow-up with CT, barium meal, and serum SCC showed no evidence of recurrence. However, these investigations do not replace endoscopic assessment for detecting small local or metachronous mucosal lesions. Gastroscopy with iodine staining should be arranged as soon as the patient's tuberculosis is adequately controlled.

This case report has several limitations. First, it describes a single patient, and the findings cannot be generalized. Second, the follow-up period is relatively short (1.5 years), and follow-up endoscopy had not been performed at the time of the reported assessment. Third, the role and optimal dose of additional radiotherapy after ESD for pT1b (SM1) lesions cannot be established from a single case.

Conclusion

This case suggests that patients with head and neck squamous cell carcinoma should receive regular esophageal screening after surgery. ESD can achieve complete (R0) endoscopic resection for simultaneous multiple foci of early-stage esophageal cancer. For pT1b (SM1) lesions, additional oncological treatment should be considered, although the optimal strategy requires further investigation.

What is new?

This case reports a rare instance of simultaneous four foci of early-stage esophageal cancer occurring 6 years after radical tongue cancer surgery. All four lesions were successfully resected in a single ESD procedure. One lesion had pT1b stage (submucosal invasion of 0.2 mm), representing a clinical decision-making boundary. The patient received adjuvant radiotherapy and remained disease-free at 1.5 years of follow-up. This case highlights the importance of lifelong esophageal surveillance in head and neck cancer patients and provides clinical evidence for adjuvant radiotherapy in pT1b lesions.

List of Abbreviations

CT	Computed tomography
ESD	Endoscopic submucosal dissection;
IPCL	Intraepithelial papillary capillary loops;
NBI	Narrow-band imaging;
SCC	Squamous cell carcinoma antigen;
SM1	Submucosal invasion ≤200 μm

Conflict of Interest

The authors declare that they have no conflict of interest regarding the publication of this case report.

Funding

No funding was received for this case report.

Consent for publication

The patient provided written informed consent for the publication of this case report and accompanying images. A copy of the written consent is available for review by the Editor-in-Chief of this journal.

Ethical approval

The institutional review board of the Second Affiliated Hospital of Shantou University Medical College approved the publication of this case.

Author details

Xiaona Ni[1], Tong Lin[1], Xingxing Wang[2], Xiaodong Chen[1]

1. Endoscopy Center, the Second Affiliated Hospital of Shantou University Medical College, Shantou, China
2. Department of Pathology, the Second Affiliated Hospital of Shantou University Medical College, Shantou, China

References

1. Slaughter DP, Southwick HW, Smejkal W. Field cancerization in oral stratified squamous epithelium: clinical implications of multicentric origin. Cancer 1953;6(5):963–8.
2. Lu H, Bei Y, Wang C, Deng X, Hu Q, Guo W, et al. A retrospective cohort study to observe the efficacy and safety of Endoscopic Submucosal Dissection (ESD) with adjuvant radiotherapy for T1a-MM/T1b-SM Esophageal Squamous Cell Carcinoma (ESCC). PLoS One 2024;19(2):e0298792. https://doi.org/10.1371/journal.pone.0298792
3. Katada C, Yokoyama T, Yano T, Suzuki H, Furue Y, Yamamoto K, et al. Alcohol consumption, multiple Lugol-voiding lesions, and field cancerization. DEN Open 2023;4(1):e261. https://doi.org/10.1002/deo2.261
4. Ko JM, Guo C, Liu C, Ning L, Dai W, Tao L, et al. Clonal relationship and alcohol consumption-associated mutational signature in synchronous hypopharyngeal tumours and oesophageal squamous cell carcinoma. Br J Cancer. 2022;127(12):2166–74. https://doi.org/10.1038/s41416-022-01995-0
5. Gu X, Wang L, Coates PJ, Gnanasundram SV, Sgaramella N, Sörlin J, et al. Evidence for etiologic field changes in

tongue distant from tumor in patients with squamous cell carcinoma of the oral tongue. J Pathol. 2023;259(1):93–102. https://doi.org/10.1002/path.6025
6. Johnson DE, Burtness B, Leemans CR, Lui VW, Bauman JE, Grandis JR. Head and neck squamous cell carcinoma. Nat Rev Dis Primers. 2020;6(1):92. https://doi.org/10.1038/s41572-020-00224-3
7. Jena SS, Nundy S. Synchronous multiple primary neoplasms of the esophagus, rectosigmoid and central nervous system. Int J Surg Case Rep. 2024;117(C):109566. https://doi.org/10.1016/j.ijscr.2024.109566
8. Liu J, Zhang M, Zhu M, Tan S, Luo X, Liu J, et al. Comparative analysis of diagnostic techniques and treatment modalities for early-stage esophageal carcinoma: a comprehensive review. Front Oncol. 2025;15:1650965. https://doi.org/10.3389/fonc.2025.1650965
9. Nehme F, Wahba GM, Ge PS. Expanded indications in advanced endoscopic resection of malignant gastrointestinal lesions. Curr Gastroenterol Rep. 2026;28(1):7. https://doi.org/10.1007/s11894-025-01029-8
10. Akashi T, Yamaguchi N, Isomoto H. Recent advances in gastrointestinal cancer endoscopic diagnosis and treatment: focusing on older adults. Intern Med. 2026;65(3):353–61. https://doi.org/10.2169/internalmedicine.4665-24
11. Lin Y, Wang SF, Liang HW, Liu Y, Huang W, Pan XB. Additional chemoradiotherapy following endoscopic submucosal dissection in patients with esophageal squamous cell carcinoma: a narrative review. Front Oncol. 2025;15:1527634. https://doi.org/10.3389/fonc.2025.1527634
12. Yang Y, Su Y, Zhang X, Liu J, Zhang H, Li B, et al. Esophagectomy versus definitive chemoradiotherapy for patients with clinical stage N0 and pathological stage T1b esophageal squamous cell carcinoma after endoscopic submucosal dissection: study protocol for a multicenter randomized controlled trial (Ad-ESD Trial). Trials 2020;21(1):603. https://doi.org/10.1186/s13063-020-04461-5
13. Hisano O, Nonoshita T, Hirata H, Sasaki T, Watanabe H, Wakiyama H, et al. Additional radiotherapy following endoscopic submucosal dissection for T1a-MM/T1b-SM esophageal squamous cell carcinoma improves locoregional control. Radiat Oncol. 2018;13(1):14. https://doi.org/10.1186/s13014-018-0960-y
14. Nishibuchi I, Murakami Y, Adachi Y, Imano N, Takeuchi Y, Tkahashi I, et al. Effectiveness of salvage radiotherapy for superficial esophageal Cancer after non-curative endoscopic resection. Radiat Oncol. 2020;15(1):133. https://doi.org/10.1186/s13014-020-01582-8
15. Ikawa T, Ishihara R, Matsueda K, Konishi K, Yamamoto S, Morimoto M, et al. Influence of radiation dose and predicted tumor invasion depth on local recurrence after definitive chemoradiotherapy for stage 0-I esophageal squamous cell carcinoma: a propensity score-weighted, retrospective, observational study. BMC Cancer. 2022;22(1):301. https://doi.org/10.1186/s12885-022-09418-2
16. Sakaguchi Y, Saito Y, Ando M, Yoshida M, Fukuoka O, Kobayashi K, et al. Risk factors for incomplete resection with pharyngeal endoscopic submucosal dissection and long-term prognosis after resection. Surg Endosc. 2023;37(5):3593–601. https://doi.org/10.1007/s00464-022-09820-8

Summary of the case

Patient (gender, age)	Male, 67 years old
Final diagnosis	Multiple primary early-stage esophageal squamous cell carcinoma (three pT1a, one pT1b)
Symptoms	Dysphagia for 2 months
Medications	None
Clinical procedure	Endoscopic submucosal dissection (ESD) followed by adjuvant radiotherapy (50 Gy/25 fractions)
Specialty	Gastroenterology/Endoscopy