EJMCR EJMCR EJMCR EJMCR EJMCR

High-resolution MRV reveals hemodynamically significant venous sinus stenosis not apparent on initial contrast-enhanced MRV in idiopathic intracranial hypertension

Ziyue Xu, Xiaolin Dong, Jingting Lu, Hailong Zhao, Gang Wu, Rui Li*

European Journal of Medical Case Reports
Volume 10(12):478–483
DOI: 10.24911/ejmcr.9-3014

OPEN ACCESS

This is an open access article distributed in accordance with the Creative Commons Attribution (CC BY 4.0) license: https://creativecommons.org/licenses/by/4.0/) which permits any use, Share — copy and redistribute the material in any medium or format, Adapt — remix, transform, and build upon the material for any purpose, as long as the authors and the original source are properly cited. © The Author(s) 2026

ABSTRACT

Background: Idiopathic intracranial hypertension (IIH) is characterized by elevated intracranial pressure of unknown etiology, with headache and visual disturbances being the predominant symptoms. Proposed pathophysiological mechanisms include increased cerebrospinal fluid (CSF) production, impaired CSF reabsorption, hormonal influences, and elevated venous sinus pressure.

Case Presentation: A 27-year-old female with a 3-month history of headache and blurred vision presented to our department. Initial contrast-enhanced MR venography (CE-MRV) showed no obvious stenosis. However, due to persistent symptoms, high-resolution MR venography (MRV-HR) was performed, revealing bilateral transverse-sigmoid sinus stenosis. Cerebral angiography confirmed severe stenosis with a trans-stenotic pressure gradient of 22.2 mmHg. The patient underwent successful venous sinus stenting, resulting in complete symptom resolution and normalization of the pressure gradient.

Conclusion: This case highlights the diagnostic value of MRV-HR in detecting hemodynamically significant venous sinus stenosis that may be missed by conventional CE-MRV, emphasizing the importance of advanced imaging in guiding endovascular treatment for selected IIH patients.

Keywords: Idiopathic intracranial hypertension, transverse-sigmoid sinus stenosis, venous sinus stenting, contrast-enhanced magnetic resonance venography.

Type of Article: CASE REPORT **Specialty:** Neurology

Correspondence to: Rui Li
*Department of Neurology, The Affiliated Yan'an Hospital of Kunming Medical University, Kunming, Yunnan, China.
Email: 2729066586@qq.com
Full list of author information is available at the end of the article.

Received: 13 July 2026
Revised (1): 19 September 2026
Revised (2): 02 October 2026
Accepted: 15 October 2026

Background

Idiopathic intracranial hypertension (IIH) is a neurological disorder characterized by elevated intracranial pressure (ICP) of unknown etiology, primarily affecting obese women of reproductive age. Its clinical presentation typically includes headaches, visual disturbances, and papilledema [1]. While historically considered a diagnosis of exclusion, the term "idiopathic" is increasingly challenged by evidence implicating venous sinus stenosis (VSS) as a significant pathophysiological factor in a subset of patients. This report details a representative case of IIH with concomitant VSS, illustrating the diagnostic process and exploring the therapeutic implications of this association [2]. Although existing literature has established the efficacy of venous sinus stenting for IIH [3], this case shows that clinically evident VSS was not demonstrated on the initial contrast-enhanced MR venography (CE-MRV), and the working diagnosis remained IIH without a confirmed structural etiology. It was only through subsequent high-resolution MR venography (MRV-HR), corroborated by invasive venous manometry, that bilateral hemodynamically significant stenosis was identified and subsequently treated with unilateral stenting. This sequence suggests that, in selected patients with persistent IIH and nondiagnostic initial imaging, further dedicated venous evaluation may be warranted.

Case History

A 27-year-old female presented to our neurology department on February 15, 2025, with a 3-month history of progressive dull headache, orbital pain, blurred vision, and diplopia. Her medical history included vitiligo and prior use of oral contraceptives, which had been discontinued 6 months before symptom onset. She denied any history of hypertension, diabetes, smoking, or alcohol consumption. She was overweight (body mass index 26 kg/m²; above the normal range of 18.5-23.9 kg/m² for Chinese adults but below the obesity threshold of 28 kg/m²) and reported regular menstrual cycles.

An outside ophthalmologic consultation prior to referral had documented optic disc edema. Upon admission, the neurological examination was non-focal apart from the reported diplopia. Best-corrected visual acuity was 1.0 in each eye [oculus dexter (right eye) 1.0; oculus sinister (left eye) 1.0], with 3-mm, isocoric pupils bilaterally. The patient was alert and cooperative, with normal cranial nerve function, full motor power (grade 5/5) in all four limbs, intact sensation, and downgoing plantar responses bilaterally. There was no clinical evidence of abducens (sixth cranial nerve) palsy: no abduction deficit was found on examination of extraocular movements, although the convergence (convergence–accommodation) reflex was sluggish. The diplopia was not otherwise characterized in the record.

A comprehensive diagnostic workup was initiated. Neuroimaging with non-contrast and contrast-enhanced magnetic resonance imaging (MRI), as well as CE-MRV (Figure 1), excluded significant mass lesions, structural anomalies, or venous sinus thrombosis. Lumbar puncture, however, revealed a markedly elevated cerebrospinal fluid (CSF) opening pressure of >400 mm H_2O, substantially above the diagnostic threshold for IIH (≥250 mm H_2O in adults). CSF composition was normal: the fluid was colorless and clear, containing 1×10^6/l cells and 3×10^6/l red blood cells, with protein 0.26 g/l, glucose 3.03 mmol/l, and adenosine deaminase <4 U/L; CSF smear showed no abnormal organisms. A pituitary hormone panel (six hormones) was normal. Subsequent investigations, including CSF analysis for demyelinating antibodies, oligoclonal bands, and next-generation sequencing for infections, along with rheumatologic serology and gynecologic ultrasonography, all yielded normal results. She reported having taken no medication during the month preceding admission. These findings collectively argued against secondary causes such as autoimmune, infectious, endocrine, medication-related, or thrombotic etiologies. Accordingly, the patient fulfilled the modified Dandy criteria for IIH: papilledema; neurologic examination normal apart from cranial nerve abnormalities; elevated opening pressure with normal CSF composition; and no identifiable secondary cause on neuroimaging and laboratory evaluation.

A repeat lumbar puncture on February 25, 2025, confirmed persistent pressure elevation (350 mm H_2O); the CSF was colorless and slightly turbid, containing 3×10^6/l cells and 1×10^6/l red blood cells. Fundoscopy at that time showed blurred optic disc margins without obvious retinal hemorrhage, and ophthalmologic assessment documented improvement of papilledema and visual symptoms compared with the outside examination. Initial management focused on reducing ICP and alleviating symptoms. At discharge, the patient was started on an oral regimen of acetazolamide 0.25 g twice daily, furosemide 20 mg once daily, and spironolactone 20 mg once daily, supplemented with mecobalamin for neuroprotection; she continued this regimen for approximately two months until readmission.

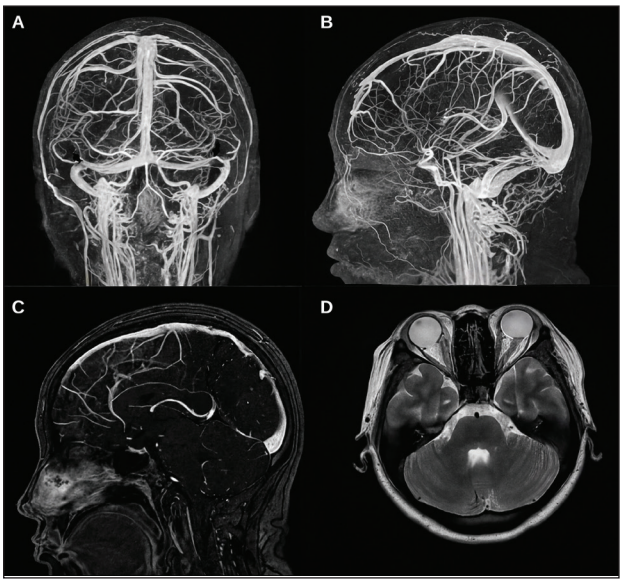

Figure 1. *Initial contrast-enhanced MR venography (CE-MRV). (A) Coronal maximum-intensity projection and (B) sagittal maximum-intensity projection, showing the superior sagittal, transverse and sigmoid sinuses and the internal jugular veins. (C) Sagittal source image and (D) axial source image. The initial report described no obvious stenosis of the transverse–sigmoid sinuses. On retrospective neuroradiological re-review after MRV-HR identified the lesion, mild bilateral narrowing at the transverse–sigmoid junction was appreciated but had not been judged significant on the original reading.*

Due to persistent headache, despite medical management, the patient was readmitted on April 3, 2025. Following recommendations from specialists at Capital Medical University, MRV-HR was performed. Whereas CE-MRV is a gadolinium-enhanced technique that depicts the contrast-opacified sinus lumen, MRV-HR in this study employed a high-resolution, thin-slice acquisition that better delineates the sinus lumen, the venous wall, and extrinsic compression at the transverse-sigmoid junction. This imaging modality revealed bilateral transverse-sigmoid sinus stenosis (Figure 2), a finding associated with elevated ICP and symptomatic manifestations such as headache and visual disturbances. After the stenosis had been identified on MRV-HR, the initial CE-MRV was retrospectively reviewed by neuroradiologists. Mild bilateral narrowing at the transverse-sigmoid junction was acknowledged in retrospect but had not been judged significant on the initial reading; the lesion was therefore subtle on CE-MRV rather than entirely absent, and had not become more apparent over time. A multidisciplinary consultation with ophthalmology was conducted, including visual field examination, computer optometry, B-ultrasound, and fundus stereography. These assessments confirmed stable papilledema without progressive visual field loss. Based on the imaging findings and persistent symptoms, cerebral angiography was indicated to further evaluate the hemodynamic significance of the stenosis.

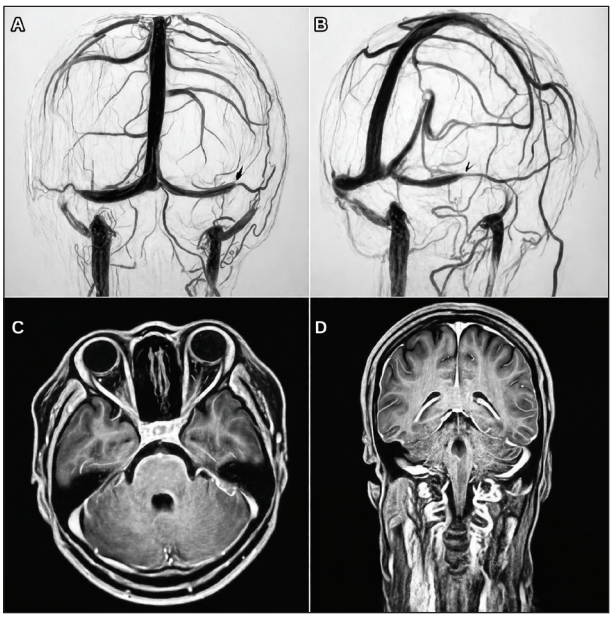

Figure 2. *High-resolution MR venography (MRV-HR). (A) Coronal and (B) sagittal maximum-intensity projections; arrows indicate bilateral transverse–sigmoid sinus stenosis, more pronounced on the right. (C) Axial and (D) coronal source images. Thin-slice acquisition delineates the sinus lumen, venous wall and extrinsic compression at the transverse–sigmoid junction.*

Diagnostic cerebral angiography confirmed severe VSS, with 90% narrowing in the right transverse sinus and 85% in the left. A trans-stenotic pressure gradient of 22.2 mmHg was recorded, indicating hemodynamic significance. The precise anatomical sampling points of the individual pressure measurements were not documented in the procedural record; the reported gradient represents the pressure difference measured across the stenotic segment. Under general anesthesia, endovascular stenting was performed via a transfemoral approach. Only the dominant right transverse-sigmoid sinus was stented; the left-sided stenosis was not treated. An 8F guiding catheter was positioned in the right jugular bulb, and a microcatheter (XT-27) was advanced across the stenotic segment. Pre-dilatation was performed using a 5 × 30 mm balloon catheter, followed by deployment of a 7 × 50 mm Wallstent self-expanding stent across the lesion. Post-stenting angiography demonstrated optimal stent expansion with complete resolution of the stenosis (residual stenosis 0%). Post-procedural manometry was performed twice across the treated segment immediately after stenting, yielding gradients of 5.7 and 6.8 mmHg on the two sequential measurements; the reported 5.7-6.8 mmHg range reflects these two measurements rather than different measurement locations. Dyna-CT imaging ruled out acute complications such as intracranial hemorrhage, and no periprocedural complication otherwise occurred.

Postoperative lumbar puncture revealed a reduction in CSF pressure to 160 mm H_2O. The patient reported significant symptomatic improvement, with resolution of headache and visual disturbances. After 7 days of hospitalization, she was discharged on dual antiplatelet therapy (aspirin 100 mg/day, planned for 3 months, and clopidogrel 75 mg/day, planned for long-term continuation) and rabeprazole for gastrointestinal protection, with scheduled follow-up in 3 months for clinical and imaging reassessment. At the 3-month outpatient follow-up, she remained free of headache and visual symptoms, and fundoscopy showed further improvement of papilledema. No repeat lumbar puncture, MRV, or catheter angiography was performed during follow-up; therefore, imaging-confirmed stent patency and late hemodynamic data are not available.

Discussion

Pathophysiological mechanisms of IIH and the role of VSS

IIH is a neurological disorder characterized by elevated ICP of unknown etiology, predominantly affecting obese women of reproductive age [1]. Although the exact pathophysiology remains incompletely understood, several mechanistic frameworks have been proposed. The Monro-Kellie doctrine provides a foundational model, positing that the intracranial volume—comprising brain tissue, blood, and CSF—is constant under normal conditions; an imbalance among these components can lead to raised ICP [9,10]. Emerging evidence has increasingly implicated VSS as a critical factor in IIH pathogenesis [11]. A compelling pathophysiological model suggests that elevated ICP may externally compress the relatively vulnerable transverse sinuses, leading to venous outflow obstruction [12,13]. This, in turn, impedes CSF reabsorption at the arachnoid granulations, creating a self-perpetuating cycle of rising ICP—a mechanism analogous to a Starling resistor [14,15]. Recent insights into the glymphatic system and perivenous CSF flow pathways further illuminate the complex interplay between cerebral venous hemodynamics and CSF dynamics [16]. Our case, demonstrating significant bilateral transverse-sigmoid sinus stenosis with a high trans-stenotic pressure gradient of 22.2 mmHg, is consistent with VSS participating in this vicious cycle; however, in an individual patient the direction of causality—whether the stenosis elevates ICP or chronically raised ICP secondarily narrows the sinuses—cannot be established with certainty. Furthermore, the persistence of symptoms despite guideline-directed medical therapy in our patient aligns with previous observations that hemodynamically significant stenosis may be associated with treatment resistance [4,7].

Diagnostic imaging strategies: from morphology to hemodynamic significance

Accurate identification of VSS is paramount for guiding treatment decisions in IIH [7]. Our case illustrates the complementary roles of advanced neuroimaging techniques

and highlights the limitations of conventional modalities. CE-MRV serves as an excellent initial screening tool for visualizing sinus anatomy and detecting gross stenosis or thrombosis [5,17,18]. However, it is primarily limited to morphological assessment and may fail to detect functionally significant stenoses, particularly those caused by external compression rather than intraluminal thrombus [19]. In our patient, the initial CE-MRV was reported as showing no significant stenosis; after MRV-HR disclosed the lesions, retrospective re-review identified subtle bilateral narrowing that had not been appreciated prospectively. Phase-contrast MRI (PC-MRI) offers a functional dimension by quantifying venous blood flow velocity and volume, thereby helping to distinguish between hemodynamically significant stenosis and incidental anatomical variants [20,21]. MRV-HR, particularly using black-blood techniques, provides detailed visualization of the venous wall and surrounding structures [24,25]. In this case, MRV-HR was instrumental in identifying the subtle bilateral stenoses that were later confirmed by angiography. This single observation does not establish that MRV-HR is generally diagnostically superior to CE-MRV; it demonstrates only that MRV-HR disclosed stenosis that was not evident on the initial CE-MRV in this patient, and comparative studies are required to define the respective roles of the two techniques. Despite advances in non-invasive imaging, invasive venous manometry remains the gold standard for measuring the trans-stenotic pressure gradient. A gradient exceeding 8 mmHg is widely considered indicative of hemodynamic significance and a potential indication for intervention [22,23]. Our patient's gradient of 22.2 mmHg far exceeded this threshold, providing a clear rationale for endovascular treatment.

Therapeutic implications and the role of venous sinus stenting

The management of IIH traditionally follows a stepwise approach, beginning with weight loss and pharmacotherapy such as acetazolamide [8]. For patients with refractory symptoms and radiologically confirmed VSS with a significant pressure gradient, venous sinus stenting has emerged as a highly effective intervention [26]. Stenting mechanically disrupts the positive feedback loop by restoring venous outflow, which subsequently facilitates CSF reabsorption and reduces ICP [27]. Our patient's outcome aligns with the growing body of literature supporting the efficacy of VSS. Meta-analyses and case series report significant improvement in headache (68%), pulsatile tinnitus (84.7%), and visual symptoms (76.2%) following the procedure [28]. The immediate reduction of the trans-stenotic gradient from 22.2 mmHg to 5.7 and 6.8 mmHg on two post-stenting measurements and the subsequent complete resolution of symptoms in our patient underscore the therapeutic value of this intervention in carefully selected cases. Similar outcomes have been reported in previous case series [6]. Importantly, this case reinforces the necessity of a multidisciplinary evaluation involving neurology, ophthalmology, and interventional neuroradiology to optimize patient selection and outcomes [1].

Study limitations and future directions

Despite the illustrative nature of this case report, several limitations should be acknowledged. First, as a single-case study, its generalizability is inherently limited. The long-term durability of the stenting procedure and the potential for in-stent restenosis or symptom recurrence require sustained follow-up. Our follow-up duration was only 3 months and included no repeat imaging or venous manometry; therefore, durable stent patency, in-stent restenosis, and long-term symptom control could not be assessed. Second, the precise causality between VSS and IIH—whether it is a primary cause or a secondary consequence of chronically elevated ICP—can be challenging to definitively establish in individual cases, though the positive feedback model provides a plausible explanation [15]. Third, while post-stenting lumbar puncture demonstrated a marked reduction in ICP (from 350 mm H_2O at repeat lumbar puncture to 160 mm H_2O after stenting), repeat lumbar puncture was not performed during subsequent outpatient follow-up due to significant symptomatic resolution. The hemodynamic data—a fall in the trans-stenotic pressure gradient from 22.2 mmHg preoperatively to 5.7-6.8 mmHg postoperatively, below the widely accepted 8 mmHg threshold for hemodynamic significance [22,23]—support the short-term efficacy of stenting in this patient, but longer and prospectively collected follow-up is required before broader conclusions can be drawn.

Future research should prioritize large-scale, prospective studies to better define the criteria for patient selection for VSS and to evaluate long-term outcomes. Comparative studies of different imaging modalities (CE-MRV, PC-MRI, and MRV-HR) could help establish an optimal, non-invasive diagnostic algorithm. Furthermore, investigations into the molecular and biomechanical mechanisms linking obesity, venous compliance, and ICP regulation may unveil novel therapeutic targets.

Conclusion

This case demonstrates that, in a selected patient with persistent IIH whose initial CE-MRV was nondiagnostic, dedicated high-resolution venous imaging followed by catheter angiography and manometry can disclose hemodynamically significant transverse-sigmoid sinus stenosis. Unilateral stenting of the dominant right sinus reduced the trans-stenotic gradient from 22.2 mmHg to 5.7-6.8 mmHg, with resolution of headache and visual symptoms and improvement of papilledema over a 3-month follow-up; long-term stent patency and durability remain to be established. The report supports further venous evaluation and

manometry in selected patients with persistent IIH when initial imaging is nondiagnostic; it does not imply that all patients with a negative CE-MRV require MRV-HR, nor does it establish general diagnostic superiority of MRV-HR over CE-MRV. Multidisciplinary management incorporating neurology, ophthalmology, and interventional neuroradiology remains essential, and prospective studies are needed to define optimal patient selection for venous interventions in IIH.

What is new?

- In a patient with IIH and persistent symptoms, an initial contrast-enhanced MR venogram showed no stenosis, whereas high-resolution MR venography disclosed bilateral transverse–sigmoid sinus stenosis that was subsequently confirmed by catheter venography and manometry.
- The trans-stenotic pressure gradient was 22.2 mmHg, far above the 8 mmHg threshold of hemodynamic significance, and unilateral stenting of the dominant right sinus reduced it to 5.7-6.8 mmHg with complete resolution of symptoms.
- A "negative" CE-MRV does not exclude a hemodynamically significant stenosis in selected patients with persistent IIH; dedicated venous imaging with manometry may be warranted before a treatable cause is excluded.

List of Abbreviations

CE-MRV	Contrast-enhanced MR venography
CSF	Cerebrospinal fluid
ICP	Intracranial pressure
IIH	Idiopathic intracranial hypertension
MRV-HR	High-resolution MR venography
PC-MRI	Phase-contrast magnetic resonance imaging
VSS	Venous sinus stenosis

Clinical trial number

Not applicable.

Conflicts of interest

The authors declare that they have no conflict of interest regarding the publication of this case report.

Funding

This work was supported by the Yunnan Provincial Department of Science and Technology-Kunming Medical University Joint Special Project (No. 202401AY070001-187); Yunnan Provincial Department of Education Science Research Fund Project (No. 2024J0281); Kunming Health Science and Technology Talent Training Project – Medical Technology Center Construction Project (No. 2024-SW(Ji)-18); Training Plan for Medical Discipline Leaders of High-Level Health Technology Talents in Yunnan Province (No. D-2024040); Kunming "Spring City Plan" High-Level Talent Training Project (No. 2024014); Kunming City Health Science and Technology Talent Training Project (No.2024-SW(HB)-83).

Data availability

The data supporting the findings of this study are available from the corresponding author upon reasonable request.

Consent for publication

Written informed consent was obtained from the patient for publication of this case report and any accompanying images. A copy of the written consent is available for review by the Editor-in-Chief of this journal.

Ethical approval

Ethical approval was not required for this case report.

Author details

Ziyue Xu, Xiaolin Dong, Jingting Lu, Hailong Zhao, Gang Wu, Rui Li

Department of Neurology, The Affiliated Yan'an Hospital of Kunming Medical University, Kunming, Yunnan, China

References

1. Mollan SP, Davies B, Silver NC, Shaw S, Mallucci CL, Wakerley BR, et al. Idiopathic intracranial hypertension: consensus guidelines on management. J Neurol Neurosurg Psychiatry. 2018;89(10):1088–100. https://doi.org/10.1136/jnnp-2017-317440
2. Elder BD, Goodwin CR, Kosztowski TA, Radvany MG, Gailloud P, Moghekar A, et al. Venous sinus stenting is a valuable treatment for fulminant idiopathic intracranial hypertension. J Clin Neurosci. 2015;22(4):685–9. https://doi.org/10.1016/j.jocn.2014.10.012
3. Giridharan N, Patel SK, Ojugbeli A, Nouri A, Shirani P, Grossman AW, et al. Understanding the complex pathophysiology of idiopathic intracranial hypertension and the evolving role of venous sinus stenting: a comprehensive review of the literature. Neurosurg Focus. 2018;45(1):E10. https://doi.org/10.3171/2018.4.FOCUS18100
4. Markey KA, Mollan SP, Jensen RH, Sinclair AJ. Understanding idiopathic intracranial hypertension: mechanisms, management, and future directions. Lancet Neurol. 2016;15(1):78–91. https://doi.org/10.1016/S1474-4422(15)00298-7
5. Morris PP, Black DF, Port J, Campeau N. Transverse sinus stenosis is the most sensitive MR imaging correlate of idiopathic intracranial hypertension. AJNR Am J Neuroradiol. 2017;38(3):471–7. https://doi.org/10.3174/ajnr.A5055
6. Ahmed RM, Wilkinson M, Parker GD, Thurtell MJ, Macdonald J, McCluskey PJ, et al. Transverse sinus stenting for idiopathic intracranial hypertension: a review of 52 patients and of model predictions. AJNR Am J Neuroradiol. 2011;32(8):1408–14. https://doi.org/10.3174/ajnr.A2575
7. Zhao K, Gu W, Liu C, Kong D, Zheng C, Chen W, et al. Advances in the understanding of the complex role of venous sinus stenosis in idiopathic intracranial hypertension. J Magn Reson Imaging. 2022;56(3):645–54. https://doi.org/10.1002/jmri.28177
8. Raoof N, Hoffmann J. Diagnosis and treatment of idiopathic intracranial hypertension. Cephalalgia 2021;41(4):472–8. https://doi.org/10.1177/0333102421997093
9. Mokri B. The Monro-Kellie hypothesis: applications in CSF volume depletion. Neurology 2001;56(12):1746–8. https://doi.org/10.1212/WNL.56.12.1746
10. Kakizawa Y, Hongo K, Takasawa H, Miyairi Y, Sato A, Tanaka Y, et al. "Real" three-dimensional constructive interference in steady-state imaging to discern microneurosurgical anatomy. Technical note. J Neurosurg. 2003;98(3):625–30. https://doi.org/10.3171/jns.2003.98.3.0625
11. Colman BD, Boonstra F, Nguyen MN, Raviskanthan S, Sumithran P, White O, et al. Understanding the pathophysiology of idiopathic intracranial hypertension (IIH): a review of recent developments. J Neurol Neurosurg Psychiatry. 2024;95(4):375–83.

12. King JO, Mitchell PJ, Thomson KR, Tress BM. Cerebral venography and manometry in idiopathic intracranial hypertension. Neurology. 1995;45(12):2224–8. https://doi.org/10.1212/WNL.45.12.2224
13. Johnston I, Hawke S, Halmagyi M, Teo C. The pseudotumor syndrome. Disorders of cerebrospinal fluid circulation causing intracranial hypertension without ventriculomegaly. Arch Neurol. 1991;48(7):740–7. https://doi.org/10.1001/archneur.1991.00530190088020
14. Farb RI, Vanek I, Scott JN, Mikulis DJ, Willinsky RA, Tomlinson G, et al. Idiopathic intracranial hypertension: the prevalence and morphology of sinovenous stenosis. Neurology. 2003;60(9):1418–24. https://doi.org/10.1212/01.WNL.0000066683.34093.E2
15. Bono F, Giliberto C, Mastrandrea C, Cristiano D, Lavano A, Fera F, et al. Transverse sinus stenoses persist after normalization of the CSF pressure in IIH. Neurology 2005;65(7):1090–3. https://doi.org/10.1212/01.wnl.0000178889.63571.e5
16. Iliff JJ, Wang M, Liao Y, Plogg BA, Peng W, Gundersen GA, et al. A paravascular pathway facilitates CSF flow through the brain parenchyma and the clearance of interstitial solutes, including amyloid β. Sci Transl Med. 2012;4(147):147ra111. https://doi.org/10.1126/scitranslmed.3003748
17. Beier D, Korsbæk JJ, Bsteh G, Macher S, Marik W, Pemp B, et al. Magnetic resonance imaging signs of idiopathic intracranial hypertension. JAMA Netw Open. 2024;7(7):e2420138. https://doi.org/10.1001/jamanetworkopen.2024.20138
18. Saposnik G, Bushnell C, Coutinho JM, Field TS, Furie KL, Galadanci N, et al.; American Heart Association Stroke Council; Council on Cardiopulmonary, Critical Care, Perioperative and Resuscitation; Council on Cardiovascular and Stroke Nursing; and Council on Hypertension. Diagnosis and management of cerebral venous thrombosis: a scientific statement from the American Heart Association. Stroke 2024;55(3):e77–90. https://doi.org/10.1161/STR.0000000000000456
19. Khan F, Seyam M, Sharma N, Ud Din M, Bansal V. New horizons for diagnostic pitfalls of cerebral venous thrombosis: clinical utility of a newly developed cerebral venous thrombosis diagnostic score: a case report and literature review. Am J Case Rep. 2021;22:e932123. https://doi.org/10.12659/AJCR.932123
20. Baskar D, Gandikota G, Botchu R, Singh DK, Khan R, Papineni V. Utility of magnetic resonance arthrography in the age of expanded magnetic resonance imaging capabilities: a global survey perspective. Cureus 2024;16(10):e71526. https://doi.org/10.7759/cureus.71526
21. Chan W, Green AL, Mishra A, Maxner C, Shankar JJ. Transverse venous sinus stenosis in idiopathic intracranial hypertension: a prospective pilot study. Can J Ophthalmol. 2020;55(5):401–5. https://doi.org/10.1016/j.jcjo.2020.05.008
22. Azzam AY, Mortezaei A, Morsy MM, Essibayi MA, Ghozy S, Elamin O, et al. Venous sinus stenting for idiopathic intracranial hypertension: an updated Meta-analysis. J Neurol Sci. 2024;459:122948. https://doi.org/10.1016/j.jns.2024.122948
23. Abou-Mrad T, Alaraj A. Venous sinus stenosis intracranial hypertension, rethinking idiopathic intracranial hypertension in the setting of venous sinus stenosis: a call for new nomenclature and diagnostic precision. Interv Neuroradiol. 2024;•••:15910199241285754. https://doi.org/10.1177/15910199241285754
24. Sarabi MS, Ma SJ, Jann K, Ringman JM, Wang DJ, Shi Y. Vessel density mapping of small cerebral vessels on 3D high resolution black blood MRI. Neuroimage. 2024;286:120504. https://doi.org/10.1016/j.neuroimage.2023.120504
25. Yang X, Wu F, Liu Y, Duan J, Fisher M, Ji X, et al. Diagnostic performance of MR black-blood thrombus imaging for cerebral venous thrombosis in real-world clinical practice. Eur Radiol. 2022;32(3):2041–9. https://doi.org/10.1007/s00330-021-08286-x
26. Fargen KM, Coffman S, Torosian T, Brinjikji W, Nye BL, Hui F. "Idiopathic" intracranial hypertension: an update from neurointerventional research for clinicians. Cephalalgia 2023;43(4):3331024231161323. https://doi.org/10.1177/03331024231161323
27. Essibayi MA, Oushy SH, Lanzino G, Brinjikji W. Venous causes of pulsatile tinnitus: clinical presentation, clinical and radiographic evaluation, pathogenesis, and endovascular treatments: a literature review. Neurosurgery 2021;89(5):760–8. https://doi.org/10.1093/neuros/nyab299
28. Nicholson P, Brinjikji W, Radovanovic I, Hilditch CA, Tsang AC, Krings T, et al. Venous sinus stenting for idiopathic intracranial hypertension: a systematic review and meta-analysis. J Neurointerv Surg. 2019;11(4):380–5. https://doi.org/10.1136/neurintsurg-2018-014172

Summary of case

1	Patient (gender, age)	27 years, female
2	Final diagnosis	IIH with bilateral transverse-sigmoid sinus stenosis
3	Symptoms	Progressive headache, orbital pain, blurred vision, and diplopia
4	Medication	Acetazolamide, furosemide, aspirin, clopidogrel
5	Clinical procedure	Lumbar puncture CE-MRV MRV-HR Cerebral angiography Venous sinus stenting
6	Specialty	Neurology, Ophthalmology, Interventional Neuroradiology