Inguinal myofibroblastoma found incidentally at hernia repair: a surgical rarity: a rare case report

Naveed Abbas Akbar[1], Asad Suleman[2*], Fareen Fatima[3], Sidra Amin[4], Umair Rehman[5]

European Journal of Medical Case Reports
Volume XX(XX):01–05
DOI: XXXX

OPEN ACCESS

This is an open access article distributed in accordance with the Creative Commons Attribution (CC BY 4.0) license: https://creativecommons.org/licenses/by/4.0/) which permits any use, Share — copy and redistribute the material in any medium or format, Adapt — remix, transform, and build upon the material for any purpose, as long as the authors and the original source are properly cited. © The Author(s) 2026

ABSTRACT

Background: Myofibroblastoma is a rare mesenchymal tumor,predominantly found in the breast, but it may rarely occur in extramammary regions as in our case, in the inguinal region. Extramammary myofibroblastoma can easily be misdiagnosed as lipoma, hernia, or fibromatosis due to their non-specific radiological and clinical appearance, which may lead to unexpected intraoperative findings.

Case Presentation: We report a case of a 28-year-old male who presented with right inguinal swelling for six months, clinically diagnosed as hernia. During hernioplasty, a well-circumscribed, firm mass was found within the inguinal canal, completely separate from the spermatic cord and hernia sac and was excised in its entirety.

Conclusion: Histopathological examination, supported by immunohistochemistry, remains the gold standard for diagnosis, helping to differentiate myofibroblastoma from other spindle-cell neoplasms. The patient recovered uneventfully, and active surveillance with clinical and ultrasound evaluation at 6 months showed no evidence of recurrence. We present this case to emphasize the importance of diagnostic histopathological examination, helping to differentiate myofibroblastoma from other inguinal and spindle-cell lesions.

Keywords: Myofibroblastoma; inguinal hernia; immunohistochemistry; incidental findings; herniorrhaphy.

Type of Article: Case Report **Specialty:** General Surgery

Correspondence to: Asad Suleman
*Emergency Medical Officer, Sardaran Siddique Hospital, Chiniot, Punjab, Pakistan.
Email: Asads0561414@gmail.com
Full list of author information is available at the end of the article.

Received: 30 July 2026
Revised (1): 25 October 2026
Accepted: 01 November 2026

Background

Mammary-type myofibroblastoma (MTM) is an uncommon, benign mesenchymal tumor that typically occurs in the breast [1,2–7]. However, histologically identical tumors can occasionally arise in extra-mammary sites, with the inguinal region representing one of the rarest locations [2,8]. This entity was first delineated in extra-mammary soft tissues in 2001 by McMenamin and Fletcher [9], who described lesions sharing morphological and immunohistochemical features with their mammary counterpart.

The clinical presentation of an inguinal myofibroblastoma poses a significant diagnostic challenge. It typically manifests as a slow-growing, painless mass clinically indistinguishable from more common entities such as an inguinal hernia or a spermatic cord lipoma [8,10]. Preoperative imaging often lacks specificity, frequently leading to initial misdiagnosis [10]. Consequently, the definitive diagnosis is most often an incidental finding during surgery for a suspected hernia.

In this context, histopathological examination supplemented by immunohistochemistry serves as the gold standard for definitive diagnosis. The classic immunoprofile of the tumor strong positivity for CD34 and desmin, combined with negativity for S100 and STAT6 is crucial to differentiate it from other spindle-cell neoplasms in the differential diagnosis, such as solitary fibrous tumors or fibromatosis [8–10].

We present this case of an incidental mass discovered during hernia repair to emphasize the clinical necessity of submitting unexpected or discrete intraoperative lesions for histopathological analysis. This practice ensures accurate diagnosis, confirms benign pathology, and rules out potential malignancies, thereby preventing adverse patient outcomes.

Case Presentation

A 28-year-old male with no significant past medical or surgical history presented to General Surgery outdoor patient department with right sided inguinal swelling of six months' duration.

Clinical findings

On examination, a visible right inguinal swelling was noted, which was soft in consistency, reducible and positive cough impulse. There was no tenderness, skin changes, or associated lymphadenopathy. So, the diagnosis of right inguinal hernia was made.

Diagnostic assessment

Preoperative laboratory investigations, including a complete blood count, liver function tests, renal function tests, and viral markers (Hepatitis B, Hepatitis C, and HIV), were within normal limits. A preoperative ultrasound of the abdomen and pelvis was performed. The ultrasound report confirmed the presence of an inguinal hernia but did not identify any discrete soft tissue mass separate from the hernia contents.

Therapeutic intervention

The patient was scheduled for elective right inguinal hernioplasty. Intraoperatively, the lesion was identified within the inguinal canal (specifically in relation to Hesselbach's triangle) and was found to be entirely separate from the spermatic cord and surrounding paratesticular soft tissues. Furthermore, it was completely distinct and separate from the hernia sac, with no evidence of invasion into the peritoneal lining. The mass was excised in its entirety and sent for histopathological examination. Subsequently, a standard Lichtenstein tension-free hernioplasty was performed using a polypropylene mesh.

Follow-up and outcomes

Postoperative course was uneventful and the patient was discharged on the following day. The patient was placed on an active surveillance protocol consisting of clinical follow-up and physical examinations at 3-month intervals for the first year, supplemented by a local ultrasound at 6 months, which confirmed complete clinical recovery with no evidence of local recurrence.

Patient perspective

The patient expressed complete satisfaction with the surgical outcome, experienced a smooth and uneventful recovery, and felt reassured by the definitive benign diagnosis.

Histopathological findings

Gross examination

The specimen was received as a single, well-circumscribed nodular mass measuring 4.8 × 3.8 × 2.4 cm. Serial sectioning revealed a gray-white, flexible lesion. The surgical margin was noted to be narrow, with a distance of 1 mm from the nearest peripheral edge; however, complete histological excision (R0 resection) was achieved, and given the benign nature of the tumor, no additional re-excision was required (Figure 1).

Microscopic examination

Histological sections demonstrated a spindle cell neoplasm composed of bland, fibroblast-like cells with short, ovoid nuclei. The tumor cells were arranged in intersecting fascicles between bundles of dense collagen and



Figure 1. *Gross specimen of the excised mass in container. Description: A single well circumscribed 4.8 × 3.8 × 2.4 cm in size, round to oval in shape. External surface appears to be smooth and translucent with areas of hemorrhagic discoloration and soft in consistency.*

admixed with mature adipose tissue. There was no significant nuclear atypia or mitotic activity.

Immunohistochemistry

An immunohistochemical panel was performed, which revealed a definitive profile:

- The tumor cells showed strong positivity for CD34 and Desmin.
- Stains for S100 and STAT6 were negative.

Diagnosis

The gross, microscopic, and immunohistochemical features are diagnostic of a MTM, measuring 4.8 cm, with narrow excision margins. No lymph node tissue was submitted for evaluation (Figure 2).

Discussion

The incidental discovery of a soft tissue mass during routine inguinal hernia repair presents a significant diagnostic dilemma, underscoring the necessity of histopathological evaluation for unexpected intraoperative lesions. The definitive diagnosis of a MTM in the inguinal region confirms a rare, benign mesenchymal neoplasm that is histomorphologically identical to its mammary counterpart [7]. This finding is supported by established literature indicating that while MTMs are predominantly located in the breast, they can also arise in various extra-mammary sites, with the inguinal canal representing one of the rarest locations [2,8]. The seminal work of McMenamin and Fletcher, who first characterized this entity in soft tissues, accurately describes the morphological and immunohistochemical features observed in our case [9].

The clinical presentation of our patient illustrates the diagnostic challenge associated with an extra-mammary myofibroblastoma. As documented, these tumors typically present as slow-growing, painless masses that are clinically indistinguishable from common inguinal hernias or spermatic cord lipomas [8,10]. In our patient, preoperative ultrasonography confirmed the presence of a hernia but failed to identify the discrete mass, highlighting the limited sensitivity of routine imaging for small soft-tissue neoplasms and leading to an initial misdiagnosis [10]. Consequently, the definitive diagnosis relied entirely on an unanticipated intraoperative discovery.

In this context, our case reaffirms that histopathological examination supplemented by immunohistochemistry remains the gold standard for definitive diagnosis. The classic immunoprofile of our tumor strong positivity for CD34 and desmin, combined with negativity for S100 and STAT6 was crucial to secure the diagnosis of MTM [8–10]. This precise immunohistochemical signature was vital to differentiate it from other morphologically similar spindle-cell neoplasms in the inguinal region, such as solitary fibrous tumors (which are typically STAT6 positive) and neural tumors (which are typically S100 positive). Accurate histopathological characterization is essential as it directly guides surgical management and reassures against malignancy.

The primary limitation of this report is its single-case nature and a medium-term follow-up duration (6 months). While short-to-medium-term outcomes are excellent, long-term surveillance protocols for extramammary myofibroblastoma remain to be established in larger cohort studies.

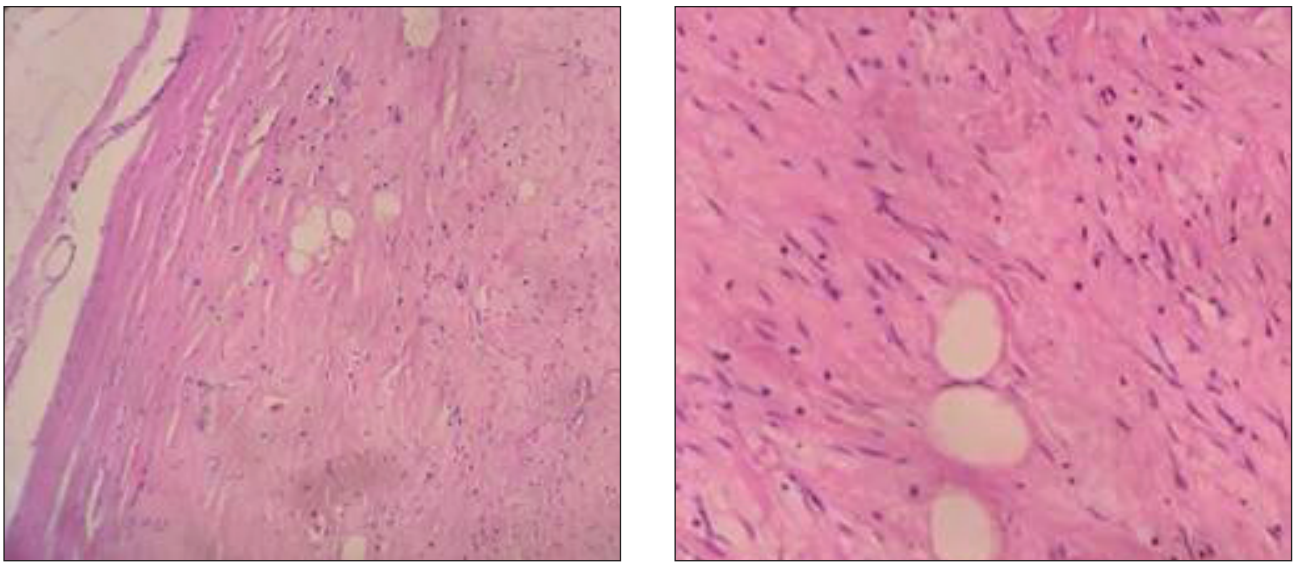

Figure 2. *Histopathological slide images. Well circumscribed spindle cell tumor comprised of short fascicles of bland spindled cells and dense hyalinized collagen bundles. The tumour cells are bland, uniform, short to elongated spindle cells arranged as short haphazard intersecting fascicles, admixed with bands of hyalinized, brightly eosinophilic collagen and variable amounts of fat. No nuclear atypia, atypical mitoses, or necrosis is present (H&E stain; Left: 100× magnification, Right: 400× magnification).*

Our case of an incidental inguinal myofibroblastoma serves as an important reminder that discrete or unexpected masses encountered during routine hernia repair should routinely undergo histopathological examination. While MTM is a benign entity with an excellent prognosis following complete resection, formal microscopic analysis is vital to exclude potential malignancies and ensure appropriate patient surveillance.

Conclusion

This case of an incidental inguinal myofibroblastoma highlights a rare but important differential diagnosis for a common groin swelling. It emphasizes the diagnostic limitations of imaging techniques and confirms the role of histopathology supported by immunohistochemistry as the definitive diagnostic tool. We strongly advocate for the histopathological examination of unexpected or discrete masses encountered during routine hernia surgery to determine the nature of the tissue, whether benign or malignant, ensuring accurate diagnosis and optimal disease management.

Whats New?

This case reports a 28-year-old male with a 4.8 cm MTM incidentally found during Lichtenstein hernioplasty for a clinically diagnosed right inguinal hernia. The novelty is threefold: (1) Preoperative ultrasound completely missed the discrete mass, highlighting imaging limitations; (2) the tumor was an unexpected intraoperative finding adjacent to the spermatic cord, despite a typical hernia presentation; and (3) it emphasizes the mandatory pathological examination of all excised hernia tissues, as missing this could overlook benign tumors or, worse, malignant mimics. The documented narrow surgical margin (1 mm) further underscores the value of detailed pathology to guide follow-up for even benign lesions.

Conflict of interest

The authors declare that they have no conflicts of interest regarding the publication of this case report.

Funding

None.

Consent for publication

Written informed consent was obtained from the patient for the publication of this case report and any accompanying clinical images.

Ethical approval

Ethical approval was granted by the Ethical Committee/ Institutional Review Board (IRB) of DHQ Hospital Jhang.

Author details

Naveed Abbas Akbar[1], Asad Suleman[2], Fareen Fatima[3], Sidra Amin[4], Umair Rehman[5]

1. Consultant Surgeon, DHQ Hospital, Pakistan
2. Emergency Medical Officer, Sardaran Siddique Hospital, Chiniot, Punjab, Pakistan
3. B.S. Molecular Biology & Genetics, Liaquat University of Medical & Health Sciences (LUMHS), Pakistan
4. MBBS, Postgraduate Resident (PGR IV) Surgery, Pakistan
5. Demonstrator, Community Medicine, Aziz Fatimah Medical & Dental College (AFMDC), Faisalabad, Punjab, Pakistan

References

1. Hassan RE, Raza M, Hamad SB, Vasudevan K, Abbas J. An unexpected giant: a case of massive paratesticular extra-mammary myofibroblastoma. Cureus. 2024;16(8):e66856. https://doi.org/10.7759/cureus.66856.
2. Ishihara A, Yasuda T, Sakae Y, Sakae M, Hamada T, Tsukazaki H, et al. A case of mammary-type myofibroblastoma of the inguinal region. Int J Surg Case Rep. 2018;53:464–7. https://doi.org/10.1016/j.ijscr.2018.11.048.
3. Zeng YF, Dai YZ, Chen M. Mammary-type myofibroblastoma with infarction and atypical mitosis-a potential diagnostic pitfall: a case report. World J Clin Cases. 2022;10(16):5343–51. https://doi.org/10.12998/wjcc.v10.i16.5343.
4. Blake Sullivan C, Dass C, Lee J, Bayon R. Mammary-type myofibroblastoma of the larynx: a rare tumor of the head and neck. Otolaryngol Case Rep. 2018;9(7):20–22. https://doi.org/10.1016/j.xocr.2018.10.004.
5. Mele M, Jensen V, Wronecki A, Lelkaitis G. Myofibroblastoma of the breast: case report and literature review. Int J Surg Case Rep. 2011;2(6):93.
6. Mukkamalla SKR, Lotfollahzadeh S. Breast myofibroblastoma. Treasure Island, FL: StatPearls; 2023.
7. Sitges C, Úbeda B, Ganau S, Macedo M, Sanfeliu E, Bargalló X. Myofibroblastoma of the breast: 3 case reports and review of literature. Radiologia (Engl Ed). 2024;66(5):479–84. https://doi.org/10.1016/j.rxeng.2023.03.008.
8. Maggiani F, Debiec-Rychter M, Verbeeck G, Sciot R. Extramammary myofibroblastoma is genetically related to spindle cell lipoma. Virchows Arch. 2006;449(2):244–7. https://doi.org/10.1007/s00428-006-0228-z.
9. McMenamin ME, Fletcher CDM. Mammary-type myofibroblastoma of soft tissue: a tumor closely related to spindle cell lipoma. Am J Surg Pathol. 2001;25(8):1022–9. https://doi.org/10.1097/00000478-200108000-00006.
10. Kawakami K, Sato Y, Sugimoto S. A case of mammary-type myofibroblastoma occurring in the inguinal region. Cureus. 2024;16(6):e62679. https://doi.org/10.7759/cureus.62679.

Summary of the case

Patient (gender, age)	Male, 28 years old
Final diagnosis	Inguinal mammary-type myofibroblastoma (MTM)
Symptoms	Right-sided painless, reducible inguinal swelling
Medications	None reported
Clinical procedure	Excision of the mass and Lichtenstein tension-free hernioplasty
Specialty	General surgery