# Presumed pulmonary actinomycosis mimicking malignancy and tuberculosis: a diagnostic challenge and response to empirical therapy—a case report

Aiman Mushir[1*], Syed Amad Bukhari[1], Rahul Mukherjee[1]

**European Journal of Medical Case Reports**
Volume XX(XX):01–08
DOI: XXXX

OPEN ACCESS

This is an open access article distributed in accordance with the Creative Commons Attribution (CC BY 4.0) license: https://creativecommons.org/licenses/by/4.0/) which permits any use, Share — copy and redistribute the material in any medium or format, Adapt — remix, transform, and build upon the material for any purpose, as long as the authors and the original source are properly cited. © The Author(s) 2026

## ABSTRACT

**Background:** Pulmonary actinomycosis is a rare, chronic bacterial infection that frequently mimics pulmonary malignancy and tuberculosis (TB), making diagnosis challenging, particularly when microbiological confirmation cannot be obtained.

**Case Presentation:** A 68-year-old woman presented with a two-week history of cough, exertional dyspnea, low-grade fever, night sweats, and weight loss. Imaging showed a cavitating left upper lobe consolidation initially concerning for TB or malignancy. Bronchoscopy, bronchoalveolar lavage, and repeated sputum sampling did not identify TB, malignant cells, or a specific organism, but computed tomography-guided lung biopsy demonstrated filamentous organisms resembling *Actinomyces* on histopathology, with no evidence of malignancy; Gram staining did not confirm the organism, and anaerobic culture was not obtained. In the absence of microbiological or definitive histological confirmation, a presumed diagnosis of thoracic actinomycosis was made, and empirical, prolonged oral amoxicillin was commenced. Over approximately four years of follow-up, her course fluctuated, with symptomatic and radiological relapse on two occasions when antibiotics were interrupted, and subsequent improvement on re-treatment, before therapy was eventually discontinued in September 2025 following sustained clinical and radiological improvement.

**Conclusion:** Thoracic actinomycosis should remain a differential diagnosis for cavitating pulmonary lesions once common causes are excluded. In the absence of microbiological confirmation, histological suspicion combined with a pattern of relapse on treatment withdrawal and improvement on re-treatment can support, though not confirm, a presumed diagnosis, and can help guide management when repeat invasive biopsy is declined or unfeasible.

**Keywords:** Actinomycosis, pulmonary cavitation, lung diseases, amoxicillin, tuberculosis, pulmonary, differential diagnosis, case report.

**Type of Article:** Case Report **Specialty:** Respiratory Medicine/ Infectious Diseases

**Correspondence to:** Aiman Mushir
*Department of Respiratory Medicine, Heartlands Hospital, Birmingham, B9 5SS,, UK.
**Email:** aimanmushir@live.com
*Full list of author information is available at the end of the article.*

**Received:** 07 May 2026
**Revised (1):** 24 October 2026
**Accepted:** 03 November 2026

## Background

Actinomycosis is an uncommon bacterial infection caused by filamentous, gram-positive, non–acid-fast organisms of the genus *Actinomyces*. It typically presents in subacute or chronic forms and is characterized by a granulomatous response, often with abscess formation. Approximately 70% of reported cases are attributed to *Actinomyces israelii* and *Actinomyces gerencseriae* [1].

Thoracic actinomycosis remains particularly challenging to diagnose, as its clinical and radiological features closely resemble other pulmonary conditions such as tuberculosis (TB), bacterial pneumonia and malignancy. Misdiagnosis is therefore common, leading to inappropriate or delayed therapy [2,4].

In the present case, the initial differential diagnoses included TB and lung cancer. Both were extensively investigated without confirmation, and the patient's subsequent fluctuating clinical course - including relapse when amoxicillin was interrupted and improvement on re-treatment - supported a presumed diagnosis of thoracic actinomycosis, illustrating the diagnostic and therapeutic value of a high index of clinical suspicion in this rare condition.

## Case Presentation

A 68-year-old housewife presented to our tertiary care hospital with a two-week history of dry cough, exertional dyspnoea, low-grade fever, and night sweats. Over time, her cough became mildly productive with scant sputum,

and she experienced one episode of minor haemoptysis. She also reported intermittent evening fevers resolving with sweating, progressive shortness of breath, and left-sided pleuritic chest pain radiating to her back and shoulder.

She had no recent travel history, with her last trip to Pakistan 13 years prior, and no known exposure to TB. Her medical history included an admission for pneumonia one year earlier, during which bronchoscopy had been performed, but no organism was identified; she improved with empirical antibiotics. She was a lifelong non-smoker, with no alcohol or illicit drug use. Additional history revealed gradual weight loss of 6–8 kg over two years. She was a known type 2 diabetic and hypertensive, both well controlled on long-term medication.

On examination, she was alert, comfortable, and able to converse in full sentences. Oxygen saturation was maintained on room air. Respiratory examination revealed bronchial breath sounds over the left chest. No peripheral lymphadenopathy or systemic stigmata were present.

Initial blood work demonstrated elevated inflammatory markers, including a C-reactive protein (CRP) of 121 mg/l and a white cell count of 12.62 × $10^9$/l (Table 1). Chest radiograph showed a mass-like consolidation in the left upper lobe (LUL, Figure 1). Contrast-enhanced computed tomography (CT) chest performed in August 2022 revealed a 4.8 cm multiloculated cavity with gas and fluid in the LUL and lingular segments, with malignancy not excluded.

Bronchoscopy showed normal-appearing airways. Bronchoalveolar lavage (BAL) and bronchial washings (17 August 2022) showed: acid-fast bacilli (AFB) negative on smear; TB not detected by polymerase chain reaction (PCR); no growth on bacterial or mycobacterial culture of the washings; heavy growth of *Candida* sp. on BAL culture; and numerous neutrophils, with no fungal elements or malignant cells on cytology (Table 2).

A subsequent CT-guided biopsy (September 2022) demonstrated lung tissue fibrosis with dense inflammatory infiltrates of plasma cells, lymphoid aggregates, and neutrophils. Branching, filamentous organisms resembling *Actinomyces* were identified on histopathological examination; however, Gram staining did not confirm the organism, and further special stains were inconclusive. No sulfur granules were identified, and anaerobic culture of the biopsy specimen was not obtained. No carcinoma

***Table 1.*** *Selected laboratory investigations.*

| DATE | INVESTIGATION | FINDINGS |
|---|---|---|
| 11/08/2022 | CRP | 121 mg/l (elevated) |
| 11/08/2022 | White blood cell count (WBC) | 12.62 × $10^9$/l |
| 11/08/2022 | Sodium (Na) | 128 mmol/l |
| 15/08/2022 | CRP | 21 mg/l |
| 15/08/2022 | WBC | 7.32 × $10^9$/l |
| 26/08/2022 | CRP | 20 mg/l |
| 26/08/2022 | WBC | 6.57 × $10^9$/l |
| 05/06/2023 | CRP | 10 mg/l |
| 05/06/2023 | WBC | 8.94 × $10^9$/l |
| 02/11/2023 | CRP | 81 mg/l |
| 02/11/2023 | WBC | 12.99 × $10^9$/l |
| 23/11/2023 | CRP | 71 mg/l |
| 23/11/2023 | WBC | 10.84 × $10^9$/l |
| 24/11/2023 | CRP | 56 mg/l |
| 24/11/2023 | WBC | 13.98 × $10^9$/l |
| 26/11/2023 | CRP | 22 mg/l |
| 26/11/2023 | WBC | 6.69 × $10^9$/l |
| 01/03/2024 | CRP | 200 mg/l |
| 01/03/2024 | WBC | 15.24 × $10^9$/l |
| 2024–2025 | Hemoglobin (Hb) | 99 g/l → 109 g/l |
| 2024–2025 | Albumin | 27 g/l → 33 g/l |
| 13/12/2025 | CRP | 169 mg/l |
| 13/12/2025 | WBC | 5.75 × $10^9$/l |
| 15/12/2025 | CRP | 94 mg/l |
| 15/12/2025 | WBC | 3.49 × $10^9$/l |
| – | Pulmonary function tests | Not performed |

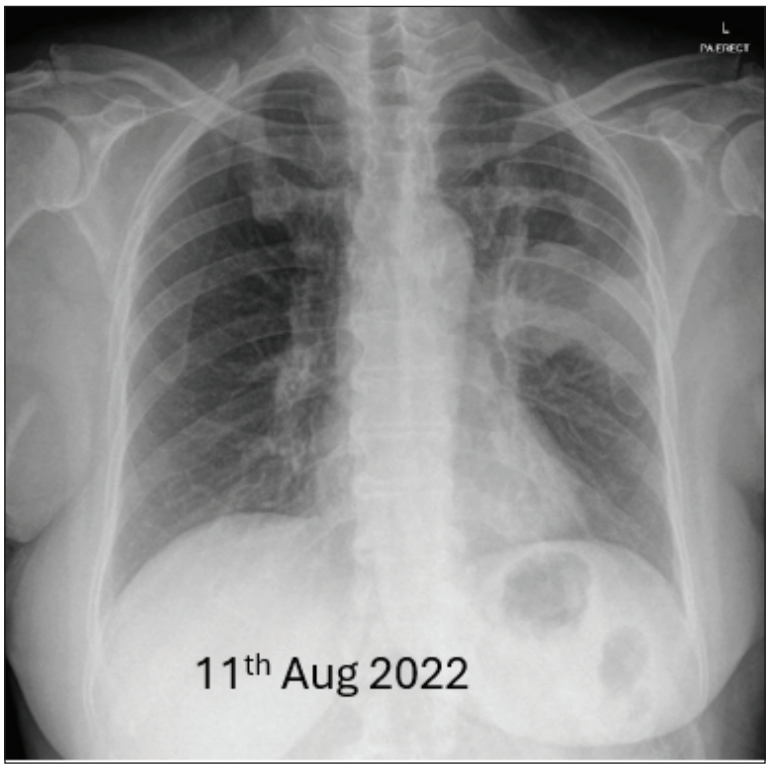


***Figure 1.*** *Chest radiograph (11 August 2022) showing a mass-like consolidation in the LUL, which prompted further evaluation with contrast-enhanced CT chest (4.8 cm multiloculated cavity, not shown separately).*

***Table 2.*** *Microbiology test results.*

| TEST | RESULT |
|---|---|
| COVID-19 PCR | Negative |
| MRSA screen | Negative |
| AFB smear (BAL) | Negative |
| TB PCR (BAL) | Not detected |
| BAL culture | Heavy growth of Candida sp. |
| Bronchial washing culture | No growth |
| Repeat sputum AFB smear and TB PCR (multiple samples, to Feb 2024) | Negative/not detected on all occasions |
| Anaerobic culture (CT-guided biopsy specimen) | Not obtained |
| Special stains on biopsy (e.g., GMS (Grocott's Methenamine Silver) and PAS (Periodic Acid-Schiff)) | Inconclusive |
| Sulfur granules on histopathology | Not identified |

or lymphoma was identified. These findings prompted a working, presumed diagnosis of thoracic actinomycosis, rather than a confirmed one.

Given the patient's social circumstances - she resided in Burton-upon-Trent but attended our Birmingham service while visiting family, which limited the feasibility of hospital admission and consistent attendance for parenteral therapy - and in the absence of features such as sepsis or empyema mandating intravenous treatment, empirical therapy with oral amoxicillin (1 g three times daily) was commenced from the outset. This decision was supported by the clinical and histopathological features and by multidisciplinary team (MDT) discussion.

The case was discussed at the lung MDT on October 7, 2022, where the decision was made to refer to the infectious diseases MDT for joint management, with a plan for repeat imaging. A repeat CT performed in October 2022, after approximately four weeks of amoxicillin, demonstrated interval progression, with the cavitary lesion enlarging to 10.4 × 5.9 cm with central necrosis (Figure 2). Repeat biopsy was advised, but the patient declined further invasive procedures for personal reasons; amoxicillin was continued in view of the absence of alternative diagnostic tissue, ongoing infectious diseases MDT input, and the absence of clinical deterioration.

Over the following three years, the patient's clinical and radiological course fluctuated considerably; the

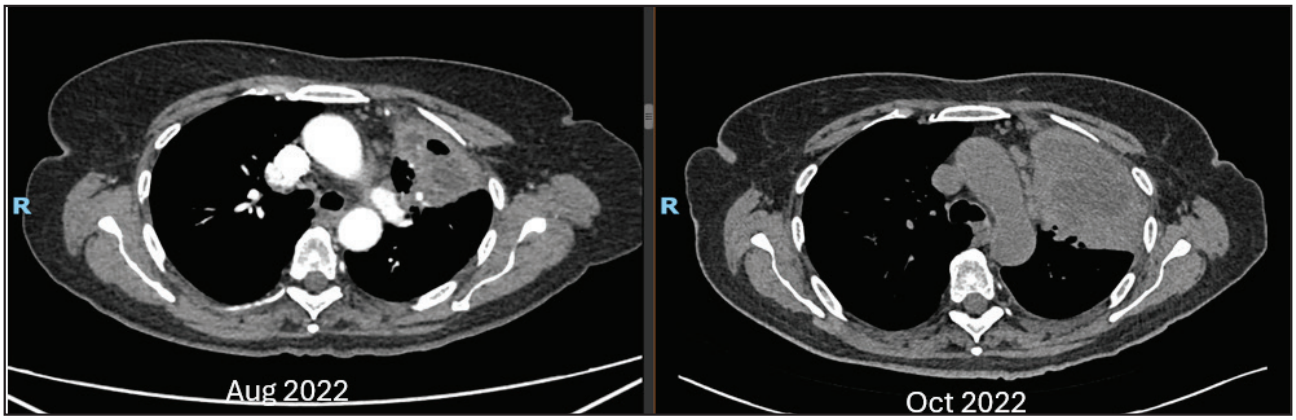


***Figure 2.*** *CT chest comparison between August 2022 (initial 4.8 cm cavity) and October 2022 (interval progression), showing enlargement of the cavitary lesion to 10.4 × 5.9 cm with central necrosis.*

***Table 3.*** *Timeline of clinical course, investigations, and interventions.*

| DATE | EVENT |
|---|---|
| ~2021 | Admission for pneumonia; bronchoscopy performed, no organism identified; improved with empirical antibiotics. |
| August 2022 | Presented with cough, dyspnea, fever, night sweats, and hemoptysis. CRP 121 mg/l, WBC 12.62 × $10^9$/l. Chest Xray (CXR): mass-like LUL consolidation (Figure 1). CT chest: 4.8 cm cavitating LUL lesion. Bronchoscopy: normal airways; BAL/bronchial washings: AFB negative, TB PCR negative, no bacterial growth, heavy *Candida* growth, no malignant cells (Table 2). |
| September 2022 | CT-guided lung biopsy: fibrosis and inflammatory infiltrate with filamentous organisms resembling *Actinomyces*; Gram stain inconclusive, no sulfur granules identified, anaerobic culture not obtained; no malignancy. Empirical oral amoxicillin 1 g ter die sumendum (TDS) started (oral route chosen given social circumstances limiting inpatient IV therapy). |
| 7 October 2022 | Case discussed at lung MDT; referred to infectious diseases MDT for joint management; plan made for repeat imaging. |
| October 2022 | Repeat CT (after ~4 weeks amoxicillin): interval progression to 10.4 × 5.9 cm cavity with central necrosis (Figure 2). Repeat biopsy advised but declined by patient. Amoxicillin continued. |
| December 2022 – March 2023 | Clinically stable; no further weight loss; persistent daytime dry cough; exercise tolerance preserved. |
| March 2023 | Sputum production resolved after 7 months of prolonged co-amoxiclav, then productive cough recurred after stopping; sputum grew mixed flora and yeast. Four-week course of amoxicillin restarted for presumed relapse; minor improvement on CXR. |
| October 2023 | CXR: resolving cavitating consolidation, chronic LUL collapse. Total of 2 months co-amoxiclav and 1 month amoxicillin given; weight fell 4 kg over 7 months; antibiotics stopped. Infectious diseases MDT review: no specific microbiological marker for actinomycosis identified, but presumed diagnosis of thoracic actinomycosis agreed based on histopathology, TB exclusion and clinical response. |
| November 2023 | Repeat CT (after 5 months off antibiotics): expanding LUL consolidation; further 2 kg weight loss; persistent dry cough. Compliance challenges related to social circumstances. Repeat CT-guided biopsy planned but declined by patient (family illness). Six-month course of amoxicillin recommenced. |
| February 2024 | Weight stabilized at 63 kg; 3 months into amoxicillin course; clinically well. TB considered fully excluded after multiple negative sputum AFB smears/PCR. |
| August 2024 | Weight and clinical status stable. |
| March 2025 | Repeat CT: significant improvement in LUL consolidation with prolonged amoxicillin. |
| June 2024–June 2025 | Weight increased 65→72 kg; albumin 27→33 g/l; hemoglobin 99→109 g/l. |
| June 2025 | Clinically well; no crackles or pedal edema; comorbidities stable. Treatment extended to September 2025. |
| October 2025 | Weight stable; repeat CT showed persistent resolution of the cavitating lesion (Figures 3 and 4 compare October 2022 with February 2025). Amoxicillin discontinued after September 2025 given sustained clinical and radiological improvement. |
| July 2026 | Surveillance CT planned; patient did not attend. Remained clinically well and stable at last contact. |

full timeline of investigations, treatment changes, and follow-up are summarized in Table 3. In brief, TB was considered comprehensively excluded, with repeatedly negative sputum AFB smears and TB PCR on

multiple occasions through to early 2024. Sputum production resolved after around seven months of prolonged co-amoxiclav therapy but recurred, together with radiological relapse, on two occasions when antibiotics were stopped or reduced (March 2023 and November 2023); on both occasions, symptoms and imaging improved again after amoxicillin was restarted. Adherence to treatment and follow-up was affected at times by the patient's social circumstances, including a period of family illness, and dose reduction was attempted but not sustained because of recurrent symptoms. Repeat CT-guided biopsy was offered again in November 2023 but declined by the patient given her personal circumstances at the time.

The infectious diseases MDT reviewed the case in October 2023; no microbiological marker specific for actinomycosis was identified, but based on the histopathological finding of filamentous organisms, exclusion of TB, and the clinical response to treatment, a presumed diagnosis of thoracic actinomycosis was agreed.

Comparative CT imaging between October 2022 and February 2025 (Figures 3 and 4) demonstrated a marked interval reduction in the size of the cavitating lesion, to approximately 7.0 cm, with persistent central fluid but no new pathology. Clinical parameters also improved over this period (Table 1): weight increased from 65 to 72 kg between June 2024 and June 2025, serum albumin rose from 27 to 33 g/l, and haemoglobin from 99 to 109 g/l. Amoxicillin was extended to September 2025 and then discontinued following sustained clinical and radiological improvement. A further surveillance CT was planned for July 2026, but the patient did not attend; at last contact she remained clinically well and stable.

### *Radiology*

## Discussion

### *Interpretation of findings*

The case discussed above highlights the diagnostic challenge posed by thoracic actinomycosis, which can mimic pulmonary malignancy, while TB must also be kept on the list of differentials. The patient presented with systemic

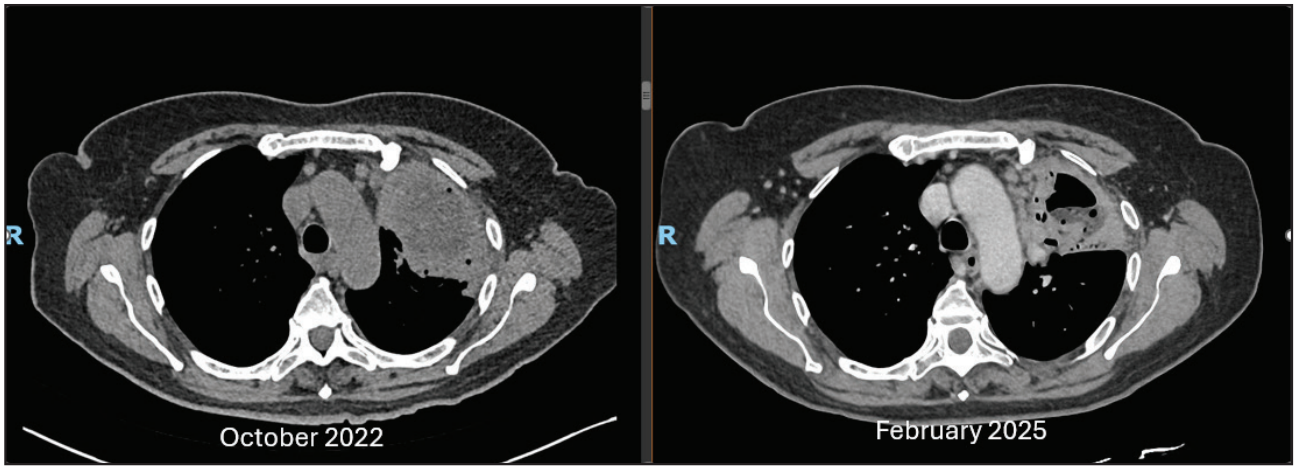


***Figure 3.*** *Axial CT chest comparing October 2022 (radiological progression, shortly after starting empirical amoxicillin) with February 2025, showing interval reduction in the cavitating LUL lesion.*

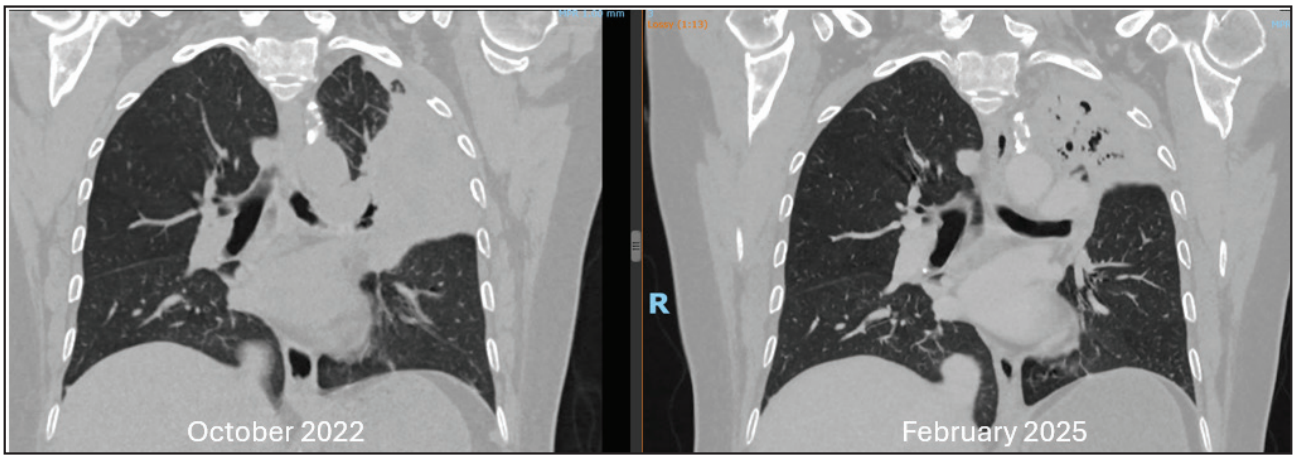


***Figure 4.*** *Coronal CT chest comparing October 2022 with February 2025, demonstrating further reduction of the cavitating lesion to approximately 7.0 cm, with persistent central fluid and no new pathology.*

symptoms (fever, night sweats, and weight loss), a cavitating upper lobe lesion, and no microbiological evidence of TB or malignancy. Initial suspicion for TB was high given the typical presentation; however, this was not supported by repeatedly negative AFB smears and TB PCR, and the lung biopsy - which showed filamentous organisms resembling *Actinomyces* without evidence of malignancy - led to a working, presumed diagnosis of thoracic actinomycosis.

This diagnosis remained presumptive throughout: Gram staining did not confirm the organism, special stains were inconclusive, no sulfur granules were identified, and anaerobic culture of the biopsy specimen was not obtained. Over almost four years of follow-up, the patient's course provided indirect supportive evidence: symptomatic and radiological relapse occurred on two occasions coinciding with interruption or reduction of amoxicillin, with subsequent improvement on re-treatment. While this pattern of relapse and response is consistent with a chronic bacterial infection such as actinomycosis, response to antibiotics is not specific to this organism, and clinical improvement alone cannot be regarded as diagnostic confirmation. The diagnosis in this case is therefore best regarded as a probable or working diagnosis rather than a confirmed one.

## *Comparison with existing literature*

Thoracic actinomycosis accounts for only about 15% of all actinomycosis cases and shows a male predominance, typically affecting individuals with poor dental hygiene, alcohol use, or chronic aspiration risk [1,3]. Our patient lacked these classic risk factors (non-smoker, non-alcoholic, no recent dental procedures), although subclinical aspiration may have predisposed her to infection.

Radiologically, thoracic actinomycosis often mimics malignancy through features such as mass-like consolidation, central necrosis, and cavitation with air-fluid levels, all of which were seen in this case; CT and radiographic findings are rarely pathognomonic and can be misleading [2,4].

Bronchoscopy is reportedly unreliable for diagnosis, with up to 70% of cultures negative in some series, particularly when antibiotics have been previously administered [6]. These findings are consistent with our experience, where neither bronchoscopy nor BAL cultures provided diagnostic clarity.

Management of thoracic actinomycosis mainly involves prolonged antibiotic therapy, typically high-dose amoxicillin for 6–12 months [5]. Our patient's treatment course was considerably longer and more complicated than this, reflecting difficulties encountered in practice rather than a planned extended regimen: symptomatic and radiological relapse on stopping or reducing treatment, challenges with adherence and follow-up related to her social circumstances, and a declined repeat biopsy that might otherwise have supported earlier, confident discontinuation of therapy. Amoxicillin was eventually stopped in September 2025 after sustained improvement, with surveillance imaging planned thereafter.

Intravenous therapy is often favored initially for extensive thoracic actinomycosis, particularly with large cavitating lesions [5]. In this patient, oral amoxicillin was used from the outset because of practical constraints on hospital admission and consistent follow-up, and in the absence of features such as sepsis or empyema that would have mandated parenteral treatment. Radiological progression noted on CT approximately four weeks after starting amoxicillin was discussed at MDT; therapy was continued, rather than escalated or changed, because the patient declined repeat tissue sampling, there was no clinical deterioration, and early radiological progression on treatment has been described in thoracic actinomycosis before later resolution [5,6].

The heavy growth of *Candida* species on BAL culture was interpreted as colonization rather than a contributor to the pulmonary lesion, since the patient's respiratory symptoms and radiological findings improved with amoxicillin therapy alone, without any antifungal treatment directed against Candida.

Malignancy was not re-investigated with PET/CT, repeat cytology, or further tissue sampling, as the patient declined repeat biopsy. In retrospect, the absence of relentless growth and the eventual radiological improvement over more than three years argue against an underlying malignant process, which would typically be expected to progress despite antibacterial therapy; this remains an inference from the clinical course, however, rather than a formal radiological or histological exclusion.

## *Clinical implications*

This case underlines several key clinical lessons:

- Thoracic actinomycosis must be considered in the differential diagnosis of cavitating pulmonary lesions, especially once typical causes (e.g., TB and malignancy) are excluded.
- In the absence of microbiological confirmation, histological suspicion, together with exclusion of more common pathologies, may warrant a trial of empirical antibiotic therapy.
- Clinical improvement under appropriate antibiotic treatment can support, but should not alone be taken to confirm, a presumed diagnosis, particularly when invasive diagnostic options are not feasible.
- The nearly four-year course in this case, including relapse on treatment withdrawal and response on re-treatment, illustrates both the diagnostic uncertainty inherent in managing a presumed infection without histological or microbiological confirmation, and the importance of a sustained, pragmatic partnership between clinician and patient when repeat invasive testing is declined.

### *Patient perspective*

The patient valued a non-invasive management approach and, after an initial diagnostic biopsy, preferred to avoid further invasive procedures. She reported that her symptoms, weight and general well-being improved over the course of treatment, and she remains satisfied with the shared decision to continue empirical amoxicillin therapy, adjusted over time in response to her symptoms, rather than pursue repeat biopsy.

### *Limitations*

Despite clinical and radiological improvement, this case remains limited by:

- Lack of microbiological confirmation: Gram staining and culture did not definitively identify Actinomyces species, and anaerobic culture of the biopsy specimen was not obtained.
- Incomplete histological confirmation: special stains were inconclusive, no sulfur granules were identified, and a repeat biopsy was not performed.
- Malignancy was not formally re-excluded with PET/CT or repeat tissue sampling after the initial biopsy.
- Potential for diagnostic error: alternative diagnoses (e.g., chronic fungal infection or atypical mycobacterial infection) cannot be fully excluded without further invasive testing or fungal serology, which was not performed.
- Response to antibiotics is not exclusive to actinomycosis; the fluctuating course, while suggestive, does not equate to definitive confirmation, and improvement could represent partial treatment of another unconfirmed infectious etiology.

## Conclusion

This case highlights the diagnostic challenges of thoracic actinomycosis, a condition that often mimics more common diseases such as TB or lung cancer. The patient had a non-specific clinical presentation and overlapping radiological findings that made diagnosis difficult. In the absence of microbiological confirmation, a presumed diagnosis was made based on histological suspicion and clinical context. Her fluctuating but ultimately favorable course over almost four years - with relapse on treatment interruption and improvement on re-treatment - is consistent with, and supportive of, this working diagnosis, though it does not equate to definitive confirmation. This experience reinforces the value of maintaining a broad differential and the importance of clinical judgment when managing complex, presumed diagnoses over a prolonged period.

### What Is New

This case illustrates that a working, presumed diagnosis of thoracic actinomycosis - based on histopathological suspicion (filamentous organisms) and exclusion of TB and malignancy - can justify empirical, prolonged amoxicillin therapy even without microbiological or definitive histological confirmation. Over an unusually long, nearly four-year course, symptomatic and radiological relapse on stopping or reducing antibiotics, with improvement on re-treatment, provided further supportive (though not confirmatory) evidence for the diagnosis and allowed repeated invasive biopsy to be avoided in a patient who declined further procedures.

### Acknowledgments

None.

### List of Abbreviations

| | |
|---|---|
| AFB | Acid-fast bacilli |
| BAL | Bronchoalveolar lavage |
| CRP | C-reactive protein |
| CT | Computed tomography |
| Hb | Hemoglobin |
| MDT | Multidisciplinary team |
| PCR | Polymerase chain reaction |
| TB | Tuberculosis |
| TDS | ter die sumendum (three times a day) |
| WBC | White blood cell count |

### Conflict of interest

The authors declare that there is no conflict of interest regarding the publication of this article.

### Funding

None.

### Consent for publication

Written consent was taken from the patient, specifically covering publication of the accompanying clinical and radiological (imaging) material.

### Ethical approval

Ethical approval is not required at our institution to publish an anonymized case report.

### Author details

Aiman Mushir[1], Syed Amad Bukhari[1], Rahul Mukherjee[1]

1. Department of Respiratory Medicine, Heartlands Hospital, Birmingham, B9 5SS, UK

### References

1. Mabeza GF, Macfarlane J. Pulmonary actinomycosis. Eur Respir J. 2003;21(3):545–51. https://doi.org/10.1183/09031936.03.00089103.
2. Heo SH, Shin SS, Kim JW, Lim HS, Seon HJ, Jung SI, et al. Imaging of actinomycosis in various organs: a comprehensive review. Radiographics. 2014;34(1):19–33. https://doi.org/10.1148/rg.341135077.
3. Russo TA, Trivedi GR. Actinomycosis. In: Cunha CB, editor. Schlossberg's clinical infectious disease. 9th ed. Philadelphia, PA: Oxford University Press; 2021. p. 835–9. https://doi.org/10.1093/med/9780190888367.003.0121.
4. Kim TS, Han J, Koh WJ, Choi JC, Chung MJ, Lee JH, et al. Thoracic actinomycosis: CT features with histopathologic correlation. AJR Am J Roentgenol. 2006;186(1):225–31. https://doi.org/10.2214/ajr.04.1749.

5. Choi J, Koh WJ, Kim TS, Lee KS, Han J, Kim H, et al. Optimal duration of IV and oral antibiotics in the treatment of thoracic actinomycosis. Chest. 2005;128(4):2211–7. https://doi.org/10.1016/s0012-3692(15)52624-x.

6. Ferry T, Valour F, Karsenty J, Breton P, Gleizal A, Braun E, et al. Actinomycosis: etiology, clinical features, diagnosis, treatment, and management. Infect Drug Resist. 2014;7:183–97. https://doi.org/10.2147/idr.s39601.

## Summary of the case

| | |
|---|---|
| 1. Patient (gender, age) | Female, 68 years |
| 2. Final diagnosis | Presumed thoracic (pulmonary) actinomycosis (working/probable diagnosis; not microbiologically confirmed) |
| 3. Symptoms | Dry cough, exertional dyspnoea, low-grade fever, night sweats, minor haemoptysis, left-sided pleuritic chest pain, weight loss |
| 4. Medications | Oral amoxicillin 1 g three times daily (prolonged, intermittent course over approximately four years; discontinued September 2025) |
| 5. Clinical Procedure | Bronchoscopy with bronchoalveolar lavage; CT-guided lung biopsy |
| 6. Specialty | Respiratory medicine/infectious diseases |