A rare case report of synchronous occurrence of breast carcinoma and chronic myeloid leukemia: diagnostic and clinical implications

Qamar Javed[1], Warda Ahmad[2*], Saira Zafar[1], Muhammad Babar Imran[2]

European Journal of Medical Case Reports
Volume XX(XX):01–04
DOI: XXXX

OPEN ACCESS

This is an open access article distributed in accordance with the Creative Commons Attribution (CC BY 4.0) license: https://creativecommons.org/licenses/by/4.0/) which permits any use, Share — copy and redistribute the material in any medium or format, Adapt — remix, transform, and build upon the material for any purpose, as long as the authors and the original source are properly cited. © The Author(s) 2025

ABSTRACT

Background: Breast carcinoma is the most common malignancy in females, and while a few cases of second primary solid organ malignancies have been reported, the synchronous occurrence of breast cancer and chronic myeloid leukemia (CML) remains exceedingly rare, particularly in patients without prior cytotoxic treatment. CML, a rare myeloproliferative neoplasm, typically develops following exposure to ionizing radiation or chemotherapy. We present the first reported case from Pakistan of synchronous CML diagnosed during staging workup of breast carcinoma.

Case Presentation: A 67-year-old female presented with a 10-month history of left breast itching and a palpable mass. The trucut biopsy revealed invasive breast cancer with focal lobular growth pattern (grade 2), estrogen receptor (ER) negative/ progesterone receptor (PR) negative and Human Epidermal Growth Factor Receptor 2 (HER2) 3+ (stage IV). Laboratory tests showed leukocytosis and thrombocytosis; peripheral smear indicated increased myeloid precursors. Bone marrow aspiration confirmed myeloid hyperplasia without metastasis, and molecular testing detected BCR-ABL fusion, confirming chronic myeloid leukemia. The patient was started on chemotherapy for breast cancer alongside imatinib for CML and tolerated the treatment well. Cardiac function was monitored with echocardiography during therapy, and a mild dose reduction of chemotherapy was required in subsequent cycles. Overall, no significant side effects or toxicities were observed.

Conclusion: Synchronous breast cancer and CML, though rare, should be considered in differential diagnoses when leukocytosis is observed in cancer patients. Early detection and accurate diagnosis are critical for optimizing treatment and improving survival outcomes.

Keywords: BCR-ABL, CML, Invasive breast cancer, Leukocytosis, Synchronous.

Type of Article: CASE REPORT **Specialty:** Oncology

Correspondence to: Warda Ahmad
*Department of Nuclear medicine, PINUM cancer Hospital, Faisalabad, Pakistan.
Email: warda.ahmad16@outlook.com
Full list of author information is available at the end of the article.

Received: 24 October 2025
Revised (1): 11 December 2025
Accepted: 30 December 2025

Introduction

In Pakistan, breast carcinoma is the most common malignancy affecting females across all age groups, with an estimated 90,000 new cases diagnosed annually, contributing significantly to cancer-related mortality [1]. Although rare, second primary malignancies (SPM) can occur in patients with breast cancer, either synchronously or metachronously. Chronic myeloid leukemia (CML), on the other hand, is relatively uncommon in the Asian population, including Pakistan. The reported incidence of CML in the country is low; however, due to the absence of a national cancer registry, the actual prevalence is likely underestimated. Many CML cases are asymptomatic at diagnosis, and limited access to blood count screening and immunophenotyping, particularly in rural areas, also contributes to underdiagnosis [2].

The synchronous occurrence of CML in a patient already diagnosed with breast cancer is exceptionally rare. Given the rarity of such presentations, we report a unique case of an elderly female diagnosed with CML during the initial staging workup for breast carcinoma. To the best of our knowledge, this represents the first reported case of its kind from Pakistan.

Case Report

A 67-year-old female presented to the breast clinic with a 10-month history of itching in the left breast and a palpable breast mass noted 9 months ago. She also reported

intermittent low-grade fever and generalized weakness for the past 2 months. The trucut biopsy of the mass revealed invasive breast cancer with a focal lobular growth pattern (grade 2) with E-cadherin expression and immunohistochemistry showed tumor cells to be ER-/ PR- and Human epidermal growth factor receptor-2 (HER2) 3+. A contrast-enhanced CT scan of the chest demonstrated multiple lesions in the upper outer quadrant of the left breast, consistent with multifocal disease, the largest measuring 2 cm. Ipsilateral axillary lymphadenopathy was present. Additionally, pleural-based lesions were observed in the right upper and lower lobes, raising suspicion for metastatic involvement. Although the lesions were too small for biopsy, radiologic assessment and multidisciplinary team consensus suggested metastasis, and the disease was staged as stage IV. The remainder of the imaging workup was unremarkable. Laboratory investigations showed anemia (Hemoglobin level of 12.6 g/dl), thrombocytosis (platelets 644 × 10^9/l), and leukocytosis (55.1 × 10^9/l) with a left shift. Differential leukocyte count revealed: neutrophils (polymorphs) 64%, lymphocytes 13%, eosinophils 6%, basophils 2%, myelocytes 7%, metamyelocytes 3%, and monocytes 5%. Peripheral blood smear demonstrated normochromic, normocytic red blood cells, a higher number of platelets, and elevated neutrophils with young myeloid cells. Bone marrow aspiration showed myeloid and megakaryocytic hyperplasia, with no evidence of metastatic deposits (Figure 1). Molecular testing confirmed the diagnosis of CML through BCR-ABL quantification (BCR-ABL1/ABL1 ratio of 55.8%). The patient tolerated the treatment well. Cardiac function was closely monitored with serial echocardiography during therapy, and a mild reduction in chemotherapy dosage was required in subsequent cycles. Overall, no significant adverse effects or toxicities were noted.

Discussion

A synchronous tumor is defined as the occurrence of two distinct primary malignancies within a 6-month period in the same individual, a phenomenon considered rare in clinical oncology. The development of SPMs in cancer patients is increasingly recognized, particularly with improved survival rates. The etiology of SPMs appears to be multifactorial, involving underlying immune dysregulation, shared genetic or environmental risk factors, and possible detection bias due to increased medical surveillance following the initial cancer diagnosis [3].

Epidemiological data indicate that cancer patients have a higher incidence of secondary neoplasms compared to the general population. In women, breast cancer is frequently associated with other malignancies such as ovarian, endometrial, soft tissue sarcomas, salivary gland

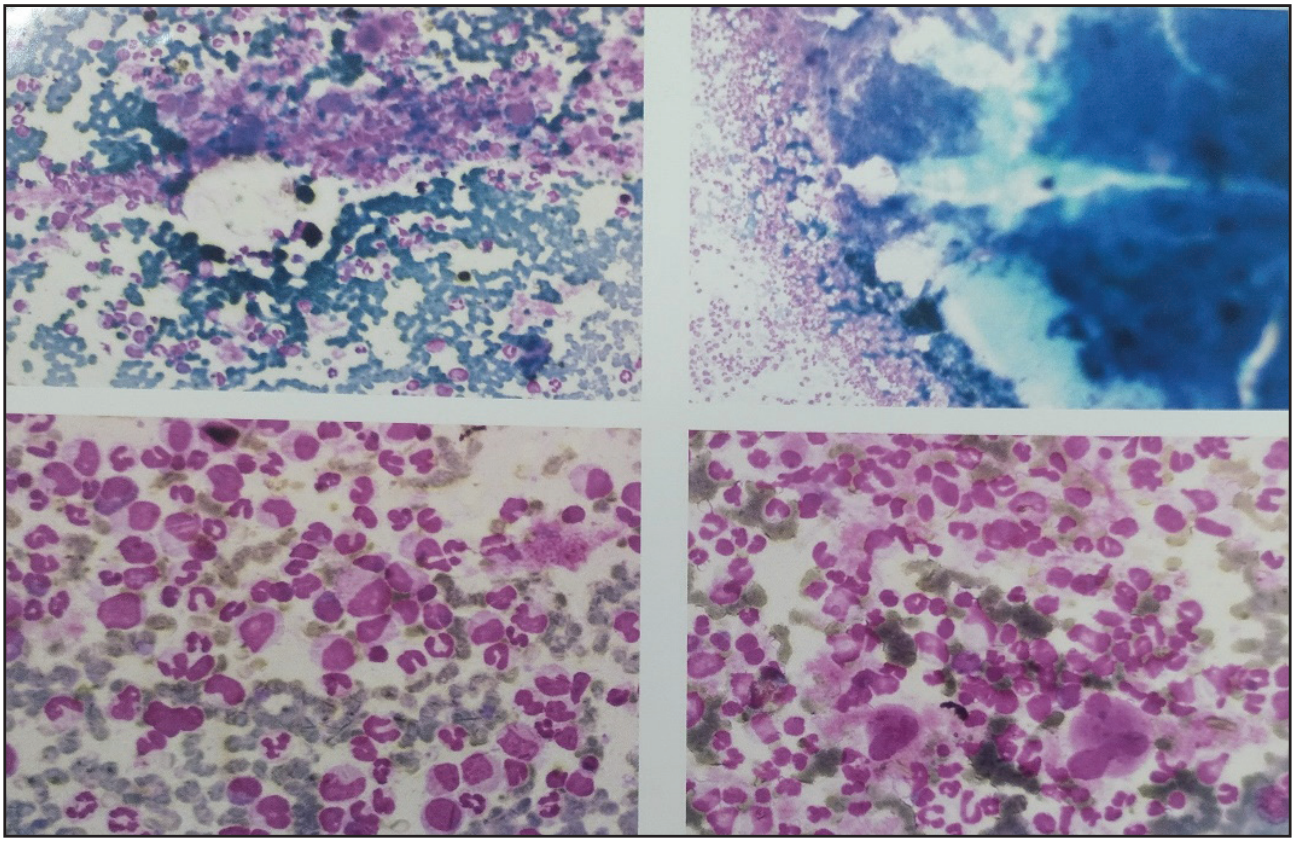

Figure 1. *Myeloid and megakaryocytic hyperplasia on bone marrow aspiration. The marrow is markedly hypercellular with predominance of myeloid precursors, resulting in an increased myeloid-to-erythroid ratio. Numerous small megakaryocytes are seen, consistent with megakaryocytic hyperplasia typical of CML*

tumors, and lung cancers [4]. While therapy-related acute myeloid leukemia and myelodysplastic syndromes are well-recognized complications of breast cancer treatment [3], the synchronous occurrence of CML with breast cancer is exceedingly rare [5]. Although leukocytosis in a known cancer patient often suggests bone marrow metastasis, a thorough evaluation may reveal a second hematological malignancy such as CML, which should be considered in the differential diagnosis, as early detection enables timely treatment and may improve outcomes [6].

CML is a rare myeloproliferative neoplasm, with an incidence of 1-2 per 100,000 annually, characterized by uncontrolled proliferation of myeloid precursors and the presence of the Philadelphia chromosome (BCR-ABL fusion gene) [7,8]. This oncogene drives leukemic growth via constitutive tyrosine kinase activity and is effectively targeted by agents like imatinib. While CML has been reported following adjuvant therapy for cancers such as breast, lymphoma, and testicular cancer, with a latency of around 4.7 years, its synchronous occurrence with breast cancer, prior to cytotoxic treatment, is extremely rare [6]. These cases may suggest an underlying genetic predisposition, warranting further genomic evaluation, as BRCA1 and BRCA2 mutations have been linked to an increased risk of both breast cancer and myeloid neoplasms [9]. BRCA1 and BRCA2 mutations impair homologous recombination repair, leading to chromosomal instability and accumulation of somatic mutations. This not only increases lifetime risk of breast cancer but also predisposes carriers to therapy-related or synchronous myeloid neoplasms [10] and a positive BCR-ABL test confirm.

Howard et al. [11] conducted a study using data from four nationwide, population-based cancer registries in Sweden, Denmark, Finland, and Norway to assess the risk of secondary leukemia in breast cancer survivors. They identified 687 cases of non-chronic lymphocytic leukemia, with an excess absolute risk of 9.05 (95% CI: 7.5-10.7). The risk of developing secondary leukemia, particularly CML and acute lymphoblastic leukemia, was significantly elevated and persisted for more than 25 years after the initial breast cancer diagnosis [11]. A similar case was reported by Bhal et al. involving a 45-year-old woman diagnosed with synchronous CML and breast cancer. She presented with a lump in the left breast, confirmed as infiltrating ductal carcinoma. Investigations showed marked leukocytosis with 5% blasts; bone marrow examination and a positive BCR-ABL test confirmed CML [12].

The rare synchronous occurrence of breast cancer and CML presents a significant diagnostic challenge. The persistent markedly elevated leukocyte counts in patients with an existing malignancy should prompt suspicion for a concurrent hematologic malignancy rather than being attributed solely to bone marrow metastasis [13] or reactive changes [14]. A few important red flags raising suspicion of CML in breast cancer include:

- Unexplained marked leukocytosis
- Left-shifted myeloid series
- Basophilia and eosinophilia
- Lack of response to steroids or antibiotics

The patient's management posed significant challenges due to the complex interplay between the two malignancies and the risk of treatment-related complications. In the current case, the concurrent use of chemotherapy and imatinib was a pragmatic approach to address both advanced breast carcinoma and CML simultaneously. Currently, there are no established clinical guidelines for the management of synchronous primary cancers [15]. Limited evidence from case reports suggests that a multimodal treatment strategy may be both feasible and effective. Close coordination between oncology and hematology teams is essential to optimize care and minimize toxicity. Regular assessment of the patient's clinical status, treatment response, and emerging complications is critical to guide future therapeutic decisions and ensure appropriate management.

Conclusion

Synchronous occurrence of breast cancer and CML is exceptionally rare but clinically significant. With increasing cancer survival, the risk of second primary malignancies, including hematological ones, must be carefully considered. Vigilant assessment of unexplained hematologic abnormalities can lead to early diagnosis, enabling timely intervention and improved outcomes. These cases underscore the potential role of genetic predisposition, the need for individualized long-term surveillance strategies, and the importance of multidisciplinary discussions in their management.

What is new

This is the first case from Pakistan reporting the synchronous occurrence of breast cancer and CML, diagnosed during initial staging workup following incidental detection of leukocytosis. Subsequent detailed evaluation and BCR-ABL fusion testing confirmed the presence of CML in this patient. The persistent markedly elevated leukocyte counts in patients with an existing malignancy should prompt suspicion for a concurrent hematologic malignancy rather than being attributed solely to bone marrow metastasis or reactive changes.

List of abbreviations

CML: Chronic myeloid leukemia
SPM: Second primary malignancies

Acknowledgment

The authors are thankful to their colleagues for their valuable support.

Conflict of interest

The authors declare that there is no conflict of interest regarding the publication of this article.

Funding

None.

Consent for publication

Written informed consent was obtained from the patient for publishing this case report.

Ethical approval

Ethical approval is not required at our institution to publish an anonymous case report.

Author details

Qamar Javed[1], Warda Ahmad[2], Saira Zafar[1], Muhammad Babar Imran[2]

1. Department of Oncology, PINUM Cancer Hospital, Faisalabad, Pakistan
2. Department of Nuclear Medicine, PINUM Cancer Hospital, Faisalabad, Pakistan

References

1. Abid S, Khan AU, Sarwar N, Hamid R. Breast cancer: early detection initiative in Pakistan. Khyber Med Univ J. 2022;14(3):145–6.
2 Ammad Ud Din M, Shahzad M, Ashraf A, Liaqat H, Jaan A, et al. Clinical Research in Chronic Lymphocytic Leukemia in Pakistan; a systematic review. Medicina (Kaunas). 2023;59(8):1483. https://doi.org/10.3390/medicina59081483
3. Khandeparkar SG, Bhatt NC, Deshmukh SV, Joshi A. A rare case of chronic lymphocytic leukemia in a patient with recurrent metastatic breast carcinoma. Med J Dr DY Patil Univ. 2015;8(1):108–10. https://doi.org/10.4103/0975-2870.148871
4. Kishtagari A, Bowman IA, Tallman MS, Douer D, Berman E, Maslak PG, et al. Chronic myeloid leukemia after adjuvant treatment for breast cancer: is it therapy related? Blood. 2013;122(21):2740. https://doi.org/10.1182/blood.V122.21.2740.2740
5. El-Badrawy A. MDCT evaluation of synchronous breast carcinoma and other solid malignancies. Breast Dis. 2021;40(4):275–81. https://doi.org/10.3233/BD-201065
6. Elm'hadi C, Khmamouche MR, Tanz R, Toreis M, Mahtat E, Allaoui M, et al. Successful management of synchronous recurrent breast carcinoma with chronic myelogenous leukemia: a case report. J Med Case Rep. 2017 Jan;11(1):10. https://doi.org/10.1186/s13256-016-1180-4
7. Pamuk GE, Ehrlich LA. An overview of myeloid blast-phase chronic myeloid leukemia. Cancers (Basel). 2024 Oct;16(21):3615. https://doi.org/10.3390/cancers16213615
8. Khan S, Sabar MF, Akbar M, Waris A. Dilemmas in the diagnosis and management of CML in Pakistan. Turk J Haematol. 2024 Dec;41(4):286–7. https://doi.org/10.4274/tjh.galenos.2024.2024.0280
9. Churpek JE, Marquez R, Neistadt B, Claussen K, Lee MK, Churpek MM, et al. Inherited mutations in cancer susceptibility genes are common among survivors of breast cancer who develop therapy-related leukemia. Cancer. 2016;122(2):304–11. https://doi.org/10.1002/cncr.29615
10. Franco S, Godley LA. Myeloid neoplasms in individuals with breast and ovarian cancer and the association with deleterious germline variants. Gynecol Oncol. 2024;187:235–40. https://doi.org/10.1016/j.ygyno.2024.05.026
11. Howard RA, Gilbert ES, Chen BE, Hall P, Storm H, Pukkala E, et al. Leukemia following breast cancer: an international population-based study of 376,825 women. Breast Cancer Res Treat. 2007;105(3):359–68. https://doi.org/10.1007/s10549-006-9460-0
12. Bahl A, Dhiman A, Talwar V, Doval DC. Synchronous carcinoma breast with chronic myelogenous leukemia: a rare presentation. Indian J Cancer. 2010;47(4):477-9. https://doi. org/10.4103/0019-509X.73558
13. Harvey Y, Bleakley S, Blombery P, Bain BJ. Marked leukemoid reaction in a patient with metastatic breast carcinoma. Am J Hematol. 2018;93(2):306–7. https://doi.org/10.1002/ajh.24849
14. Liu Y, Liu J. Male Breast cancer complicated with leukocytosis resembling leukemia reaction after chemotherapy: a case report. Cancer Rep (Hoboken). 2025;8(7):e70280. https://doi.org/10.1002/cnr2.70280
15. Feizi I, Sedigh-Namin A, Kani A, Namin SS, Toularoud AB. A rare case report of triple primary malignancies: synchronous breast ductal invasive carcinoma and lung neuroendocrine tumor, followed by chronic myeloid leukemia. Int J Surg Case Rep. 2025;130:111305. https://doi.org/10.1016/j.ijscr.2025.111305

Summary of the Case

1	Patient (gender, age)	67 years, female
2	Final diagnosis	Invasive breast cancer and chronic myeloid leukemia
3	Symptoms	Palpable breast mass, low-grade fever and generalized weakness
4	Medications	Doxorubicin and cyclophosphamide for breast malignancy, along with imatinib (400 mg OD) for CML
5	Clinical procedure	Chemotherapy, tyrosine kinase inhibitor
6	Specialty	Oncology