

# From community-acquired pneumonia to diagnosis of paraneoplastic myositis with pulmonary involvement - a case report

Joao Diogo Moreira Faustino<sup>1\*</sup>, Daniela Alves<sup>1</sup>, Raquel Vieira<sup>1</sup>, Claudia Rosado<sup>1</sup>

European Journal of Medical Case Reports

Volume 9(4):84–88

DOI: 10.24911/ejmcr.9-1677



This is an open access article distributed in accordance with the Creative Commons Attribution (CC BY 4.0) license: <https://creativecommons.org/licenses/by/4.0/> which permits any use, Share — copy and redistribute the material in any medium or format, Adapt — remix, transform, and build upon the material for any purpose, as long as the authors and the original source are properly cited. © The Author(s) 2025

## ABSTRACT

**Background:** Myositis is characterized by proximal muscle weakness/pain and can affect other organs, with skin involvement being common. Most cases are idiopathic, however, it may be part of an autoimmune disease or paraneoplastic syndrome.

**Case Report:** We present an 82-year-old woman admitted for productive cough, fever, and hypoxemia. Blood tests showed important rhabdomyolysis and mild C-reactive protein increase. Community-acquired pneumonia was assumed, and antibiotic therapy was started. Due to the lack of clinical improvement, thoracic computed tomography was performed, which revealed not only interstitial lung disease, but also a left breast nodule. A breast nodule biopsy showed breast carcinoma. Staging was carried out with the absence of metastases and the diagnosis of Paraneoplastic Myositis with pulmonary involvement was assumed. Hormone therapy was initiated, followed by a left mastectomy. Complete clinical recovery of the patient was obtained.

**Conclusion:** Interstitial lung disease is the most common and serious complication of inflammatory muscle disease, but its occurrence in paraneoplastic myositis is very rare. Complete clinical remission after removal of the neoplasm supported the diagnosis of paraneoplastic syndrome, and the patient continued with hormone therapy after surgery.

**Keywords:** Myositis, interstitial lung disease, paraneoplastic syndrome, breast cancer.

**Type of Article:** CASE REPORT      **Specialty:** Oncology, Internal Medicine, General Surgery

**Received:** 24 January 2025

**Revised (1):** 06 April 2025

**Accepted:** 14 April 2025

**Correspondence to:** Joao Diogo Moreira Faustino

\*Medical Doctor, Internal Medicine, Unidade Local de Saude da Regiao de Aveiro, Aveiro, Portugal.

**Email:** joaodmfaustino@gmail.com

*Full list of author information is available at the end of the article.*

## Background

Myositis is characterized by proximal muscle weakness and pain, eventually with skin involvement and dysphagia. Most cases are idiopathic; however, there is a strong association between myositis and malignancy, first reported in 1916 [1]. Ovarian, lung, pancreatic, stomach, and colorectal cancers are types of malignancies associated with dermatomyositis. On the other hand, cancers most often associated with polymyositis are non-Hodgkin lymphoma, lung and bladder cancer [2]. The presentation of paraneoplastic myositis with neurological symptoms or pulmonary symptoms with dyspnea, in addition to conferring greater severity to the clinical picture, can also lead to a diagnostic delay in an underlying neoplasm, since the focus remains on conducting a study directed at the patient's symptoms and developing differential diagnoses based on neurological and/or pulmonary symptoms.

In paraneoplastic myositis, treatment of cancer usually results in the regression of the myopathy, although it is sometimes difficult to distinguish between primary and paraneoplastic myositis, especially when the malignancy is advanced or resistant to treatment. We present a patient

with paraneoplastic myositis with pulmonary involvement caused by breast carcinoma.

## Case Presentation

We present an 82-year-old woman with a medical history of hypertension, dyslipidemia, obesity, hypertensive chronic heart failure, and ischemic leukoencephalopathy. She was medicated with Furosemide 40 mg id, Azilsartan 20 mg id, and Colecalciferol (Vigantol) 5 drops/day.

The patient was admitted for a productive cough and chest pain of 2 weeks' duration, accompanied by a low-grade fever (37.9°C). She denied weight loss, asthenia, anorexia, or other constitutional symptoms. Blood gas analysis showed hypoxemia, while blood tests indicated neutrophilia, with a C-reactive Protein (CRP) of 2.19 mg/dl and a Creatine-phosphokinase of 813 U/l. Chest radiography had a hypotransparency in the right lung base, thought to be a pneumonic condensation, so community-acquired pneumonia was assumed.

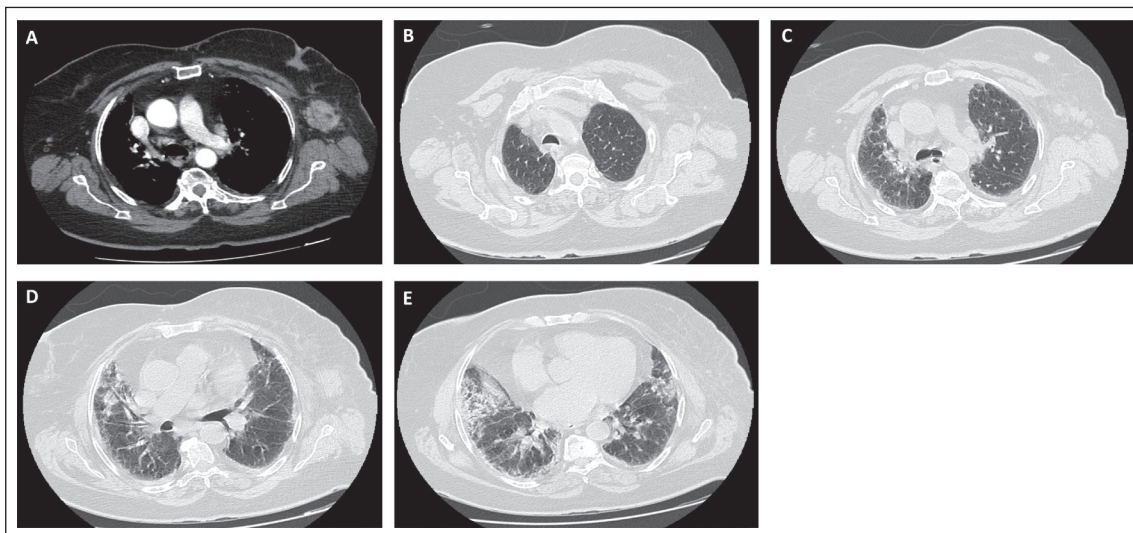
Empirical antibiotics (Azithromycin + Ceftriaxone) were started. Due to a considerable increase in rhabdomyolysis parameters, the autoimmune study was performed,

which was positive for anti-Ro52 antibody. Despite 4 days of antibiotics with no clinical or analytical improvement and no possibility of weaning from oxygen therapy, sputum and blood cultures were taken, and a chest computed tomography (CT) scan was performed. Blood cultures were negative, and the chest CT showed no signs of infectious pulmonary activity but did reveal alterations suggestive of interstitial lung disease, mainly at the lung bases. It also incidentally identified a 3.5 cm spiculated

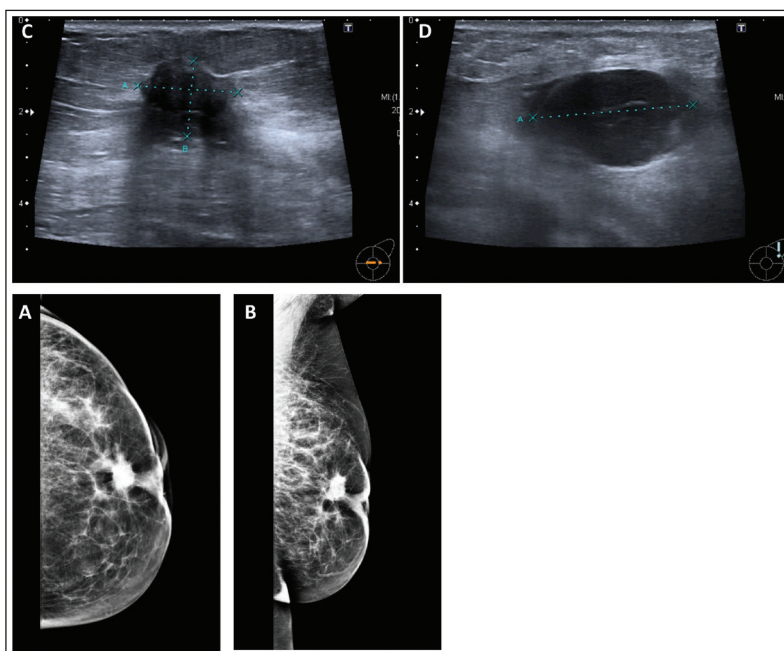
left retroareolar nodule, raising suspicion of a neoplastic lesion (Figure 1).

The breast ultrasound and mammography were categorized as BI-RADS 4/5 (Figure 2).

A breast nodule biopsy was performed and revealed invasive lobular carcinoma ER/RP positive and HER-2 negative. The patient was discharged home on long-term oxygen therapy (0.5 l/minute) with scheduled follow-up appointments in Gynecology, Rheumatology, and



**Figure 1.** (Thoracic CT scan): A. In the left mammary gland, we see retraction of the nipple and spiculated nodule in retroareolar location with characteristics suspected of neoplastic lesion. Several adenopathies are also seen in the left axillary cavity, the largest with 3.5 × 3.6 cm. B/C. Bilateral reduction of pulmonary radiotransparency, visualizing reticular densification across the entire height of both lung fields and D/E. areas of interstitial densification in the lung bases. No consolidation focuses are defined suggesting an infectious process in activity.



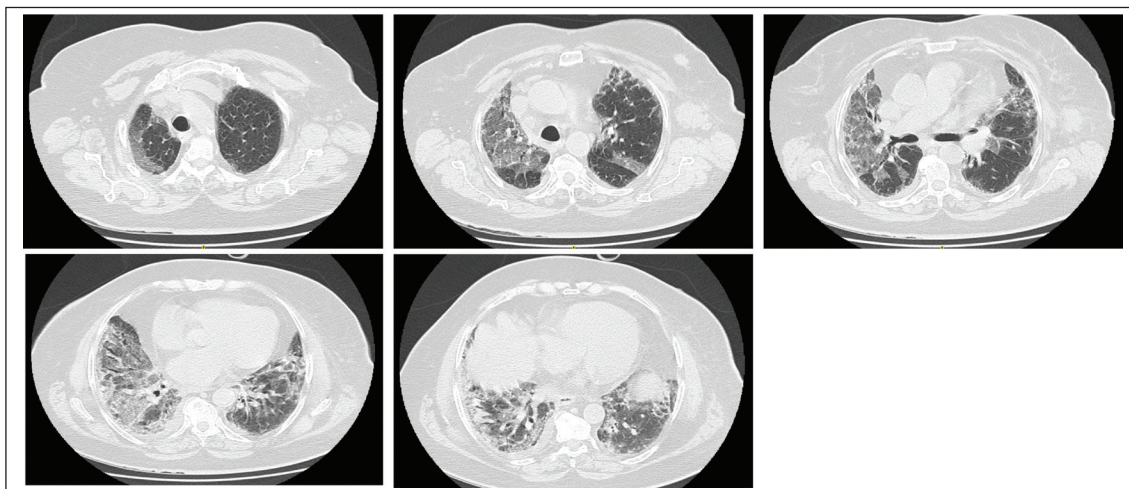
**Figure 2.** (Mammography and breast US – left breast): A/B. We visualize spiculated, dense nodules that condition nipple retraction and measure about 2 cm, corresponding to a neoplastic process C/D. Complementary ultrasound confirms the existence of a solid nodule with irregular contour and attenuation of the ultrasonic beam. Metastatic left axillary adenopathies, the largest with 3.5 cm. Bi-RADS 4/5.

Pneumology. Her discharge diagnoses were breast cancer and myositis, with a probable paraneoplastic etiology.

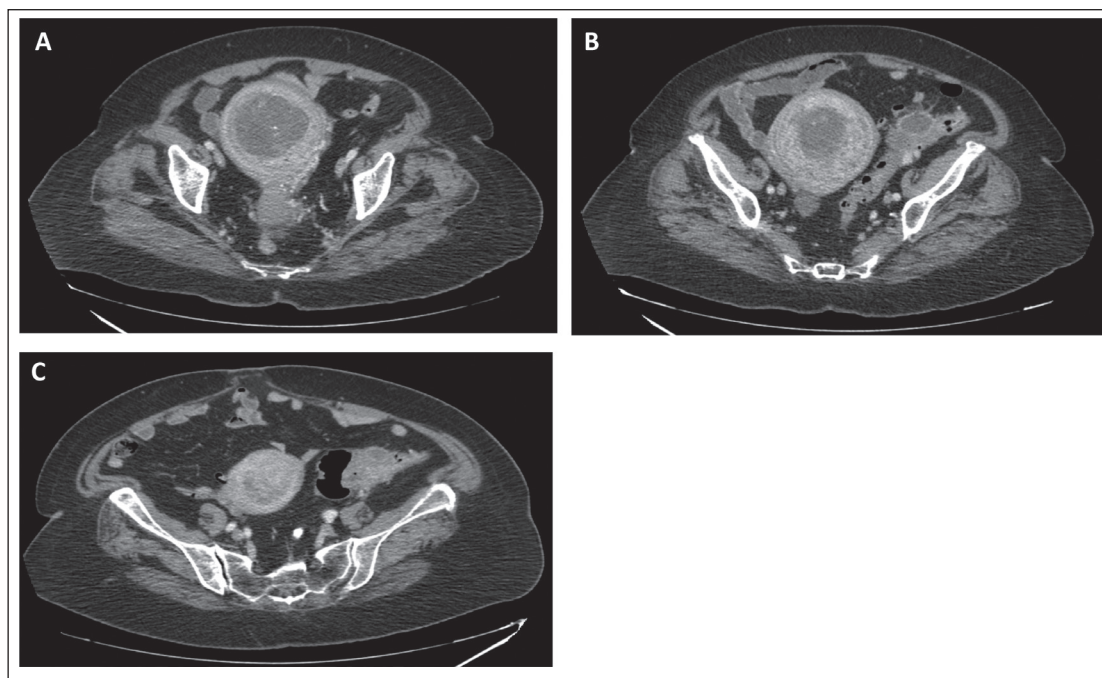
Two weeks after discharge, she was admitted to fever, worsening of dry cough, and exacerbation of hypoxemia. Analytically, she had mild neutrophilia and negative CRP. Chest radiography was similar to previous examinations and the urine examination was innocent. Initially, a fever of neoplastic etiology was assumed, but due to the worsening of the cough pattern, Amoxicillin/Clavulanate was empirically started for a possible respiratory infection.

Bronchofibroscopy excluded infection of the lower respiratory tract. On day 3 of hospitalization, she had sudden desaturation after an episode of vomiting. While aspiration pneumonitis was the initial suspicion, the positive D-dimer result prompted an investigation for pulmonary embolism (PE). A chest angio-CT scan excluded PE and an infectious etiology but revealed a progression of interstitial lung disease (Figure 3).

Due to the imaging findings and clinical deterioration, a high-dose corticosteroid course was initiated



**Figure 3.** (Thoracic CT scan): No evident signs of EP in the EP window. In the pulmonary parenchyma, bilateral reduction of pulmonary radio transparency is maintained with areas of reticular densification and interstitial densification with aggravated dispersed areas of ground glass in relation to the last CT scan performed.



**Figure 4.** (Abdomino-pelvic CT scan): A. A globous uterus is seen mainly at the fundus level, with significant distension of the fundus cavity, about 5.3 cm thick, and intracavitary hypodensity associated with calcification images (submucosal myoma / neoplasia?). B. Larger gauge sigmoid segment with enhanced wall, defining a liquid collection with gas inclusions suggestive of abscess - probable complication of diverticulitis. C. Re-evaluation CT scan after 10 days Piperacilin/ Tazobactam treatment, showing no improvements.

(Methylprednisolone 500 mg) for 3 days, followed by a maintenance dose of 0.6 mg/kg/day (40 mg Prednisolone). The rationale for using corticosteroid therapy was based on the attempt to reduce inflammation and fibrosis in interstitial lung disease associated with paraneoplastic connective tissue disease. After 7 days of 40 mg prednisolone, she started a weaning regimen (5 mg reduction every 10 days). Following the start of corticosteroid treatment, there was a significant improvement in respiratory symptoms within 1 week, and the patient returned to their baseline oxygen requirement of 0.5l/minute. At the same time, through a consultation with Gynecology, an abdominopelvic staging CT was performed, showing both an abscess in the sigmoid colon wall, probably secondary to diverticulitis, and an intracavitary uterine hypodensity raising suspicion for a submucosal myoma or neoplasm (Figure 4A/B). Following the evaluation of these uterine findings via transvaginal ultrasound and an endometrial biopsy, the histopathological analysis confirmed the absence of a neoplastic lesion. The reported abscess was discussed with general surgery and was decided to start treatment with Piperacillin/Tazobactam for 10 days and re-evaluate it by CT. Upon re-evaluation by CT scan, the abscess had not regressed (Figure 4C), and the radiologist reported that the image could be consistent with a potential neoplasm of the colon.

After re-discussing the images with general surgery, who maintained their opinion of an abscess, the decision was made to prolong therapy with Piperacillin/Tazobactam and add Metronidazole. A total colonoscopy was performed and revealed sigmoid lumen stenosis more compatible with previous diverticulitis than with neoplasia.

Meanwhile, hormone therapy with tamoxifen was initiated, followed by a left mastectomy a few days later. Five days post-surgery, she continued prednisolone on a weaning dose and required no oxygen therapy or presented with respiratory symptoms. Outpatient follow-up was arranged for recurrence of myositis or malignancy surveillance.

## Discussion

Upon readmission, paraneoplastic myositis was presumed, despite the lack of a confirmed diagnosis via muscle biopsy, alongside ongoing interstitial lung disease. Initially, it was difficult to exclude idiopathic autoimmune myositis; however, the simultaneous presence of an active neoplasm and myositis led us to prioritize the investigation of paraneoplastic syndrome, which was indeed confirmed after mastectomy.

In fact, interstitial lung disease is the most common and serious complication of inflammatory muscle diseases [3]. Anti-Ro52 antibodies are the most common immunological markers detected in the idiopathic inflammatory myopathies and their positivity helped to infer the diagnosis of paraneoplastic myositis, as it is also commonly seen in non-autoimmune/paraneoplastic disorders. The

presence of isolated anti-Ro52 antibody is associated with pulmonary involvement and it may represent the primary site for loss of tolerance and generation of auto-antibodies [4]. Although the patient had no muscle pain/weakness and had an electromyography suggesting no myopathy, she had a cough and dyspnea compatible with pulmonary involvement. This often precedes muscular involvement onset [3]. As we assumed, in interstitial lung disease, we attributed the desaturation episodes to disease progression. We also hypothesized aspiration pneumonitis, given the dysphagia in patients with myositis or PE, although the pre-test probability was low. Since the patient had moderate interstitial lung disease, induction therapy with oral corticosteroid may have been sufficient; however, mycophenolate-mofetil or azathioprine could be added for maintenance therapy [5], but meanwhile, the patient underwent surgery. Regarding the fever of unknown origin, and having ruled out a respiratory source, we were uncertain whether the etiology was neoplastic or secondary to complicated abscess diverticulitis.

During hospitalization, we initially suspected a synchronous neoplasm affecting the breast, uterus, and colon. Ultimately, only breast cancer was confirmed. Tamoxifen was used before surgery as an alternative to neoadjuvant chemotherapy in a hormone receptor-positive breast cancer in a postmenopausal woman. Early mastectomy was ultimately performed due to interstitial lung disease causing hypoxemia. After her mastectomy and while on Tamoxifen, the patient recovered well and remained free of respiratory symptoms. Chest CT showed mild regression of interstitial densification, but even more importantly, did not show its progression of it, keeping us believing in paraneoplastic myositis.

## Conclusion

In a patient presenting with fever, respiratory symptoms, and hypoxemia, the initial presumed diagnosis is a respiratory infection, and empirical antibiotic therapy is legitimate. Incidental findings obtained in imaging studies guided possible diagnoses and treatment. Due to clinical and imaging improvement after breast cancer treatment, the definitive diagnosis was assumed as paraneoplastic myositis rather than idiopathic autoimmune myositis. This complex case highlights the importance of a multidisciplinary approach in patient treatment, involving internal medicine, general surgery, gynecology, rheumatology, oncology, and pulmonology.

### What is new?

An initial suspected diagnosis of community-acquired pneumonia quickly develops into a breast neoplasm with suspected synchronous uterine neoplasm, along with advanced interstitial lung disease and complicated diverticulitis with abscesses all at once.

### Conflict of interest

The authors declare that they have no conflict of interest regarding the publication of this case report.

### Funding

None.

### Consent for publication

Written informed consent was obtained from the patient for publication of this case report and any accompanying images.

### Ethical approval

Ethical approval is not required at our institution to publish an anonymous case report.

### Author details

Joao Diogo Moreira Faustino<sup>1</sup>, Daniela Alves<sup>1</sup>, Raquel Vieira<sup>1</sup>, Claudia Rosado<sup>1</sup>

1. Internal Medicine, Unidade Local de Saúde da Região de Aveiro, Aveiro, Portugal

### References

1. Stertz G. Polymyositis. *Berl Klin Wochenschr*. 1916;53:489.
2. Hill CL, Zhang Y, Sigurgeirsson B, Pukkala E, Mellemkjaer L, Airio A, et al. Frequency of specific cancer types in dermatomyositis and polymyositis: a population-based study. *Lancet*. 2001 Jan;357(9250):96–100. [https://doi.org/10.1016/S0140-6736\(00\)03540-6](https://doi.org/10.1016/S0140-6736(00)03540-6)
3. myositis.org. The Myositis Association: Interstitial Lung Disease. VA: The Myositis Association. Available from: <https://www.myositis.org/about-myositis/complications/interstitial-lung-disease/>
4. Singh Y, Patil P, Longhurst H, Clarke G, Dasgupta B. Isolated anti-Ro52 antibody - significance and clinical association. *Am Coll Rheumatol* 2013.
5. Oddis CV, Aggarwal R. Treatment in myositis. *Nat Rev Rheumatol*. 2018 May;14(5):279–89. <https://doi.org/10.1038/nrrheum.2018.42>

### Summary of the case

1	Patient (gender, age)	82 years, female
2	Final diagnosis	Paraneoplastic myositis
3	Symptoms	productive cough, associated with chest pain with 2 weeks of evolution and subfebrile
4	Medications	Antibiotics, corticosteroids, oxygen, hormone therapy
5	Clinical procedure	Mastectomy
6	Specialty	Internal medicine, General surgery, Gynecology, Rheumatology, Oncology and Pulmonology