

somatostatin receptors [10]. Specifically, it has many advantages including fast clearance, easy labeling, rapid tissue penetration, and lesser time to scan the patient. In the clinical set up where patients flow is limited and clinical indications are few, the tracer is not always readily available at many institutes. Moreover, the relatively higher price also hinders its frequent use, particularly in a low socio-economic country like Pakistan, which ultimately delays the imaging procedures.

Alternatively, $^{99m}\text{Tc}(\text{V})\text{-DMSA}$ has a crucial role in the pre-operative evaluation, assessment of residual disease or recurrence of MTC, and other related soft tissue tumors [9,11]. But now the use of this agent is going to be abandoned in most countries due to the introduction of newer alternatives like $^{68}\text{Ga}\text{-DOTATOC}$ or $^{68}\text{Ga}\text{-DOTATATE}$. Albeit, $^{99m}\text{Tc}(\text{V})\text{-DMSA}$ is considered as cost effective and time efficient, a comprehensive cohort of studies are essential to establish such and other favorable characteristics [6,12]. Previously published work from our institute also suggests $^{99m}\text{Tc}(\text{V})\text{-DMSA}$ as a good tumor seeking agent for visualization of MTC and its involved lymph nodes in the mediastinum [6]. As $^{99m}\text{Tc}(\text{V})\text{-DMSA}$ can be easily formulated from the renal DMSA kit and has comparable results with $^{99m}\text{Tc}\text{-EDDA/HYNIC-Tyr}^3\text{-octreotide}$ (Tektrotyd), we successfully imaged a patient with MTC with locally formulated $^{99m}\text{Tc}(\text{V})\text{-DMSA}$ and then, made its comparison with the results of $^{99m}\text{Tc}\text{-EDDA/HYNIC-Tyr}^3\text{-octreotide}$ (Tektrotyd) scintigraphy for lesion detection sensitivities.

Case Presentation

A 35 years old male was diagnosed 1 year ago as a case of MTC after excision biopsy from neck swelling. He was referred to nuclear medicine department from oncology section for somatostatin receptor scintigraphy. At the time of presentation, his serum calcitonin level was 6,324 pg/ml (normal range is <8.4). However, due to non-availability of this radiopharmaceutical, it was decided to perform $^{99m}\text{Tc}(\text{V})\text{-DMSA}$ scan for this patient. The radiopharmaceutical was locally prepared using renal DMSA kit, as previously described [6,9]. More specifically, the commercial DMSA kit supplied by Isotope Production Division, PINSTECH, Islamabad, Pakistan that contains 1 mg DMSA, 0.35 mg of $\text{SnCl}_2 \cdot 2\text{H}_2\text{O}$, 0.35 mg of ascorbic acid, and 20 mg of mannitol were taken and were mixed with 1 ml of 0.167 M sodium bicarbonate solution to make the medium alkaline. The pH of the reaction mixture was (8.4–8.5) determined by pH indicator strips. Then 20 mCi (740 MBq) of freshly eluted sodium pertechnetate ($\text{Na}^{99m}\text{TcO}_4$) from $\text{Mo}^{99}/\text{Tc}^{99m}$ generator was added to the vial. The vial was incubated for 15 minutes at room temperature for reaction to complete. Quality control tests were carried out by thin-layer chromatography and the radiochemical purity was found to be $95.6\% \pm 0.5\%$. The whole process was carried out under aseptic condition.

The radiopharmaceutical was then injected into the median cubital vein of the patient through an indwelling IV cannula. Early 1 hour [Figure 1 (a,b)] and delayed 24 hours (Figure 1c) anterior spot images of the cervico-thoracic region and abdomen were acquired using Siemens Orbitor gamma camera with low energy all purpose collimator and energy window of 15% centered at 140 KeV photopeak.

After 1 month of the $^{99m}\text{Tc}(\text{V})\text{-DMSA}$ scan, the same patient underwent $^{99m}\text{Tc}\text{-EDDA/HYNIC-Tyr}^3\text{-octreotide}$ scintigraphy. The cold kit (brand name: Tektrotyd) was obtained from PARS, Isotope Company, Iran. The kit was reconstituted with 30 mCi (1,110 MBq) of ^{99m}Tc and the labeling yield was found at $98.2\% \pm 0.2\%$. Then, 20 mCi (740 MBq) of the radiopharmaceutical was slowly injected into the median cubital vein. Whole body imaging was performed on the same institutional protocols after 2 and 4 hours post injection [Figure 2 (a,b)].

All the images were compared and interpreted by the nuclear physician in view of the clinical presentation of the patient. The images were very sharp with excellent resolution and the lesion detection potentials were common in both the cases. Marked uptake of both the radiotracer was

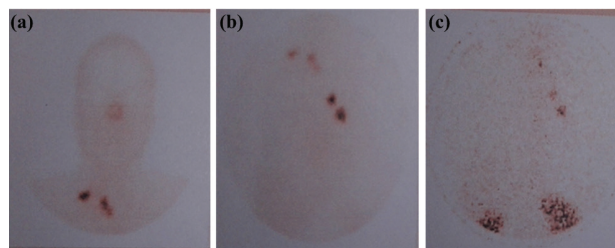


Figure 1. Illustrative $^{99m}\text{Tc}(\text{V})\text{-DMSA}$ scintigraphy images; (a) 1-hour post injection image of the anterior head and neck region, (b) 1-hour post injection image of the anterior thoracic region, and (c) 24-hour post injection image of the anterior chest region.

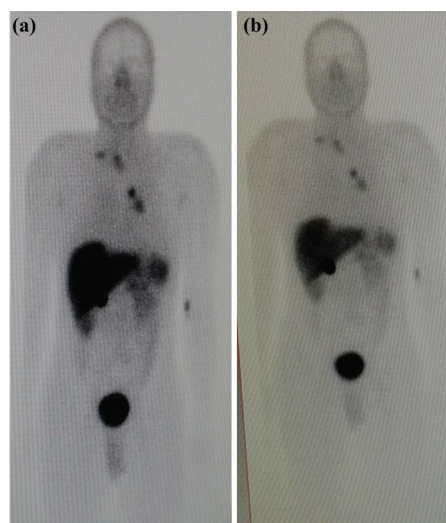


Figure 2. (a) Two and (b) four hour post injection illustrative whole body imaging of $^{99m}\text{Tc}\text{-EDDA/HYNIC-Tyr}^3\text{-octreotide}$ scan.

seen in four foci of the neck thoracic region and showed good radiotracers avidity by the lesions. The number of lesions detected by the $^{99m}\text{Tc}(\text{V})\text{-DMSA}$ on the initial scan in the neck and thorax region were found to be the same as detected later by $^{99m}\text{Tc}\text{-EDDA/HYNIC-Tyr}^3\text{-octreotide}$ scintigraphy. No additional focus was detected by the Octreoscan. The 24-hour post-injection images were additionally acquired to see the redistribution of the tracers over a long period of time. It may be noted that the Ethical Committee of The Institute approved this study for publication.

Discussion

MTC is a rare neuroendocrine tumor and octreotide scan is considered as a specific imaging agent for detection of primary and metastatic MTC with higher sensitivity than ^{99m}Tc tetrofosmin and ^{201}Tl scintigraphy [13]. Somatostatin receptor scintigraphy is used to detect the primary tumor focus for staging, the decision of therapy protocol, and evaluation of therapy response in neuroendocrine tumors and other related cancers [14]. It has proved to be better than other diagnostic tools for the detection of cervical and mediastinal lymph node metastases in MTC or other somatostatin receptor-positive tumors [15]. Several studies support that the sensitivity and specificity of Octreoscan are higher than that of $^{99m}\text{Tc}(\text{V})\text{-DMSA}$ in the work up of MTC. However, limitations are associated with this radiotracer like availability and high prices. In most developing and under developed countries, it is imported from other developed countries and patients have to wait for a prolonged duration. Patient's affordability is another major hurdle in its routine use. In such conditions, $^{99m}\text{Tc}(\text{V})\text{-DMSA}$ scanning is an affordable and a reasonably sensitive imaging agent for localization of recurrent or metastatic disease.

$^{99m}\text{Tc}(\text{V})\text{-DMSA}$ is a non specific multifunctional imaging agent that commonly accumulates in MTC [12]. Its role in the evaluation of MTC has already been compared with other functional imaging tools like ^{131}I MIBG, ^{99m}Tc tetrofosmin, ^{201}Tl scintigraphy, etc [13]. $^{99m}\text{Tc}(\text{V})\text{-DMSA}$ plays a crucial role in the assessment of residual tumor or metastatic disease in patients with medullary thyroid cancer, especially with high postoperative calcitonin levels. The ease of preparation of $^{99m}\text{Tc}(\text{V})\text{-DMSA}$ and good imaging characteristics of the radiopharmaceutical make it an alternative imaging tool in patients having proven MCT [6,9].

MTC is an uncommon NET and patients are neither readily available nor always compliant for the tedious procedures of research. Nevertheless, our experience of avid and persistent $^{99m}\text{Tc}(\text{V})\text{-DMSA}$ uptake in all the tumor deposits in the thoracic region has encouraged us to explore its potentials where EDDA/HYNIC-Tyr³-octreotide and $^{68}\text{Ga}\text{-DOTATOC}$ or $^{68}\text{Ga}\text{-DOTATATE}$ are not available. Moreover, $^{99m}\text{Tc}(\text{V})\text{-DMSA}$ shows low

uptake in the liver and spleen as compared to octreotide scan, hence, the uptake in these regions will be clearly appreciated where it will be overshadowed with octreotide. The prolonged residence of the of $^{99m}\text{Tc}(\text{V})\text{-DMSA}$ can also be utilized for an alternate therapeutic option when tagged with β -emitting radionuclides like ^{188}Re , ^{186}Re , and others.

Conclusion

Locally formulated $^{99m}\text{Tc}(\text{V})\text{-DMSA}$ scintigraphy is an easy, economical, and promising imaging modality in MTC patients with high levels of calcitonin. In comparison with $^{99m}\text{Tc}\text{-EDDA/HYNIC-Tyr}^3\text{-octreotide}$ scintigraphy, its availability and application is easier. It can be used as an alternative imaging method when $^{99m}\text{Tc}\text{-EDDA/HYNIC-Tyr}^3\text{-octreotide}$ and $^{68}\text{Ga}\text{-DOTATOC}$ or $^{68}\text{Ga}\text{-DOTATATE}$ are not available.

Acknowledgement

None

List of abbreviations

$^{99m}\text{Tc}(\text{V})\text{-DMSA}$	Technetium-99m pentavalent dimercaptosuccinic acid
MTC	Medullary thyroid carcinoma
PET	Positron emission tomography

Consent for publication

Written Informed Consent was taken from the participants of the study.

Ethical approval

Ethical Committee of The Institute approved this study for publication.

Author details

Hameed Ullah¹, Aakif Ullah Khan², Muhammad Rauf Khattak¹, Shakil Ahmad¹, Shaheen Iqbal¹

1. Institute of Radiotherapy and Nuclear Medicine (IRNUM), Peshawar, Pakistan.
2. Swat Institute of Nuclear Medicine, Oncology and Radiotherapy (SINOR), Swat, Pakistan.

References

1. Skoura E. Depicting medullary thyroid cancer recurrence: the past and the future of nuclear medicine imaging. *Int J Endocrinol Metab* 2013. 11(4):e8156. <https://doi.org/10.5812/ijem.8156>
2. American Thyroid Association Guidelines Task Force; Kloos RT, Eng C, Evans DB, Francis GL, Gagel RF, et al. Medullary thyroid cancer: management guidelines of the American Thyroid Association. *Thyroid* 2009; 19:565–612. <https://doi.org/10.1089/thy.2008.0403>
3. Laverman P, Sosabowski JK, Boerman OC, Oyen WJ. Radiolabelled peptides for oncological diagnosis. *Eur J Nucl Med Mol Imaging* 2012; 39(Suppl 1):S78–92. <https://doi.org/10.1007/s00259-011-2014-7>
4. Ha EJ, Baek JH, Na DG, Kim JH, Kim JK, Min HS, et al. The role of core needle biopsy and its impact on surgical management in patients with medullary thyroid cancer: clinical experience at 3 medical institutions. *Am J Neuroradiol* 2015; 36:1512–7. <https://doi.org/10.3174/ajnr.A4317>

5. Kapur S, Xiao H, Zakowski MF, Hameed MR, Levin MB. Metastatic medullary thyroid carcinoma and cabozantinib: case series and review of literature. *World J Oncol* 2014; 5:81–9. <https://doi.org/10.14740/wjon779w>
6. Khan AU, Bahadur A, Khattak MR, Shah AS. Mediastinal spread of medullary thyroid carcinoma imaged by locally formulated ^{99m}Tc-DMSA(V). *Pak J of Nucl Med* 2013; 3:73–7.
7. Nicolini S, Ambrosini V, Fantini L, Fanti S. 68Ga DOTANOC PET/CT detects medullary thyroid cancer relapse at bone level. *Clin Nucl Med* 2012; 37:591–2. <https://doi.org/10.1097/RLU.0b013e31824c5eab>
8. Evangelia S, Maria P, Ioannis DE. The role of nuclear medicine in imaging and therapy of neuroendocrine tumors. *Hosp Chron* 2012; 7(2):81–90.
9. Krishnamurthy A, Kumar RK, Ravishankaran P, Ramshankar V, Balkis Begum AS, Rangarajan GK. Exploring the role of technetium-99m dimercaptosuccinyl acid (V) scan in medullary carcinoma thyroid patients with postoperative persistent hypercalcitoninemia in the era of positron emission tomography-computerized tomography. *Indian J Nucl Med* 2014; 29:146–50. <https://doi.org/10.4103/0972-3919.136562>
10. Shah S, Purandare N, Agrawal A, Rangarajan V. A pictorial review on somatostatin receptor scintigraphy in neuroendocrine tumors: the role of multimodality imaging with SRS and GLUT receptor imaging with FDG PET-CT. *Indian J Radiol Imaging* 2012; 22:267–75. <https://doi.org/10.4103/0971-3026.111478>
11. Abdullah MM, Almohanadi S, Abulhuda F, Usmani S. Pentavalent [^{99m}Tc] DMSA and Serum Calcitonin in Evaluation of patients with Medullary Carcinoma of the Thyroid. *AAMJ* 2008; 6:116–27.
12. Shukla J, Mittal BR. Dimercaptosuccinic acid: a multifunctional cost effective agent for imaging and therapy. *Indian J Nucl Med* 2015; 30:295–302. <https://doi.org/10.4103/0972-3919.164015>
13. Adalet I, Demirkale P, Unal S, Ouz H, Alagöl F, Cantez S. Disappointing results with Tc-99m tetrofosmin for detecting medullary thyroid carcinoma metastases comparison with Tc-99m (V)DMSA and Tl-201. *Clin Nucl Med* 1999; 24:678–83. <https://doi.org/10.1097/00003072-199909000-00008>
14. Kulkarni HR, Singh A, Baum RP. Advances in the diagnosis of neuroendocrine neoplasms. *Semin Nucl Med* 2016; 46:395–404. <https://doi.org/10.1053/j.semnuclmed.2016.06.001>
15. Prasad V, Fetscher S, Baum RP. Changing role of somatostatin receptor targeted drugs in NET: nuclear medicine's view. *J Pharm Pharmaceut Sci* 2007; 10(Suppl 1):321s–37s.

Summary of the case

Patient (gender, age)	1	Male, 35 years
Final Diagnosis	2	MTC on fine needle aspiration cytology of anterior neck swelling, Thyroidectomy with level II lymph nodes dissection
Symptoms	3	Chest tightness, dyspnoea
Medications (generic)	4	Post surgery has not been started on any treatment
Clinical Procedure	5	Blood chemistry investigation (substantially raised serum calcitonin level), magnetic resonance imaging, computed tomography scan
Specialty	6	Thyroid clinic, nuclear medicine