

CASE REPORT

Buccal Monomorphic Adenoma: a case report

Bharat Bhushan Sharma^{1*}, Naveen Bhardwaj¹, Shweta Sharma²,
Mir Rizwan Aziz¹, Sakshi Dewan¹, Seema Nagger³

ABSTRACT

Background: Minor salivary gland benign tumors constitute a very small fraction of salivary gland tumors. The majority of monomorphic adenomas arise from the main salivary glands but rarely these can arise from the minor salivary glands of the buccal mucosa.

Case presentation: We present 60-years old female who reported for the slow growing swelling on her right cheek for over three years. She was diagnosed of having monomorphic adenoma of the minor salivary gland after ultrasound (US), contrast enhanced computerized tomography (CECT) and magnetic resonance imaging (MRI) studies with additional confirmation by fine needle aspiration cytology (FNAC).

Conclusion: Dynamic contrast MRI played a key role in assessment of the mass for its benign nature before the surgical contemplation. This was also confirmed subsequently by the histopathology examination.

Keywords: Minor salivary glands, monomorphic adenoma, US, CECT, MRI, FNAC.

Background

Monomorphic adenomas are epithelial tumors which are not pleomorphic. These have now been placed in a separate group because of the different morphological characters than pleomorphic adenoma. Minor salivary gland tumors form 15% of the salivary gland neoplasms. These are located at different locations [1]. Monomorphic adenomas are rare among minor salivary glands. These monomorphic adenomas show strong association of hamartomatous deviation from the normal organogenesis. There is some predilection for the upper lip and parotid glands. These are encapsulated slow growing masses which remain asymptomatic for a long duration. These have been mistaken as adenoid cystic carcinomas. The oral cavity contains 600 to 1000 minor salivary glands. The incidence is more noticed in the older age group. Monomorphic adenomas of basal cell type are uniform in cellularity without any myxoid or chondroid features. These are multicentric in nature and can be present at different sites. The incidence of occurrence

at different locations can be as follow:

- Palate 50%
- Lips 15%
- Buccal cheek mucosa 12%
- Tongue 5%
- Floor of the mouth 5%

There are two classes of the lesions as one from the single layer and other from the two layers of cells. The former forms the group of monomorphic adenomas. Isomorphic adenomas are strictly formed by luminal epithelial cells. These are encapsulated tumors and shows partially cystic nature. These may be mistaken as adenoid cystic carcinomas as per the histological picture. There is a lot of expansion and remain monolobular in nature. The main differentiation is done from the pleomorphic masses on the grounds of cytology, histomorphology and peripheral growth

Correspondence to:

Dr. Bharat Bhushan Sharma,

* Department of Radiodiagnosis, Faculty of Medical and Health Sciences,
SGT University Gurgaon (Haryana) India.

Email: bbhushan986@gmail.com

Full list of author information is available at the end of the article.

pattern. Ultrasonography will define the contents of the mass and the internal necrotic contents. CECT and MRI play a pivot role in the extension and relationship with the adjacent structures. The level of enhancement can indirectly highlight the vascularity of the tumor [2]. The differentiation of the tumors for benign and malignant nature can be done by the dynamic scan in MR imaging. The calculations were made against time-signal intensity curve for the time of peak enhancement and wash out ratio. This has got 91% each sensitivity and specificity in differentiation [3].

Case presentation

A sixty years old female reported to the outpatient department of otorhinology with swelling on right side of the face. There was a gradual increase in the size of the swelling. The swelling was asymptomatic in the beginning but became slightly painful as the size enlarged (Figure 1). There were some socio-cosmetic reasons for which she reported for the treatment of this swelling.

She was of averagely physical built. Her systemic examination was unremarkable. Locally, on examination, this swelling was present on the right cheek and measured 5.0 × 5.5 cm. This was soft and non tender. There was no

skin discoloration over the swelling. On examination, the buccal mucosa was of red color without any ulceration. All the biochemical parameters were within normal limits. Ultrasound examination had revealed this as soft tissue mass which was slightly echogenic with a few areas of necrosis. No calcification was seen (Figure 2a).

On color flow imaging (CFI) there was no blood flow noticed in the swelling (2b and c). Contrast-enhanced computerized tomography was done and this revealed enhancing encapsulated mass with a small region of non-enhancement representing necrosis (Figure 3a and b). Magnetic resonance imaging revealed hypo- to isointense mass which was encapsulated and had shown enhancement with few regions of intense enhancement. There was no extension to the adjoining bone or the muscle components (Figure 4a, b and c). Fine needle aspiration cytology was carried out which confirmed the diagnosis (Figure 5).

The patient underwent total surgical excision in one of our associated hospitals and had been followed up after one month without any complaint. Further follow-up had been advised at three and five months. Histopathological specimen confirmed the diagnosis.

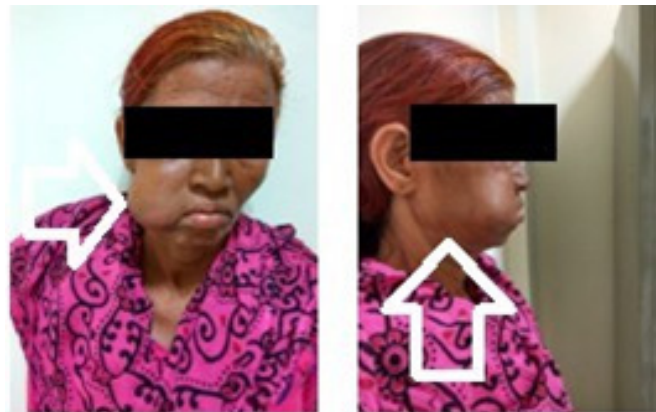

Figure 1: Sixty years old female with swelling on right cheek (white arrows).

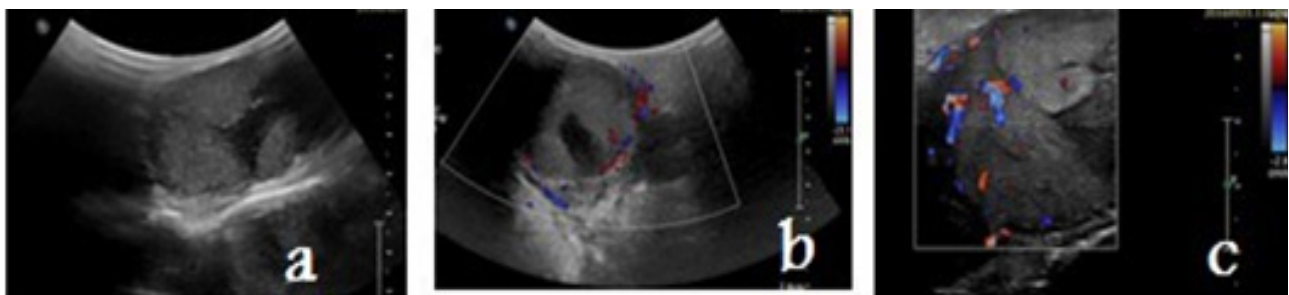


Figure 2: Ultrasonography of the left cheek, (a) Grey scale images shows an oval shaped well encapsulated heteroechoic lesion in right buccal mucosa adjacent to right parotid gland with no obvious invasion of adjacent structures. The lesion had shown a few internal necrotic anechoic areas, (b and c) Color flow imaging had shown the peripheral vascularity around the lesion with a few foci of internal vascularity.

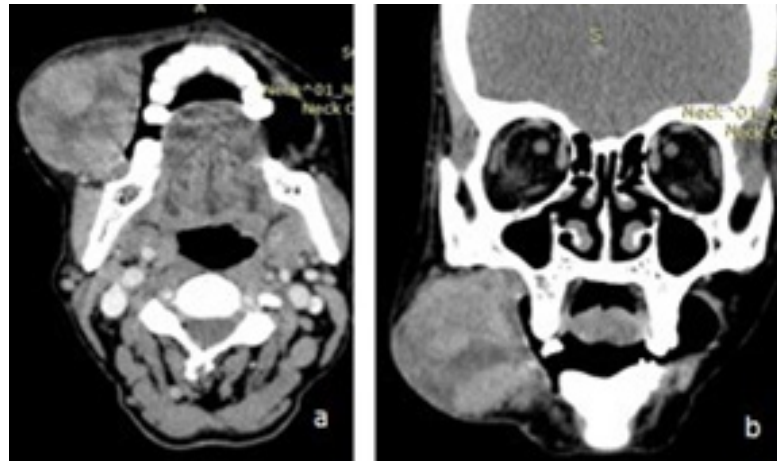

Figure 3: Contrast enhanced computerized tomography (CECT) of face, **(a)** axial section shows well demarcated lesion on the right cheek originating from the buccal mucosa. There is subtle enhancement with a few regions of necrosis, **(b)** coronal section of the same lesion highlights non – involvement of the underlying bone and overlying skin.

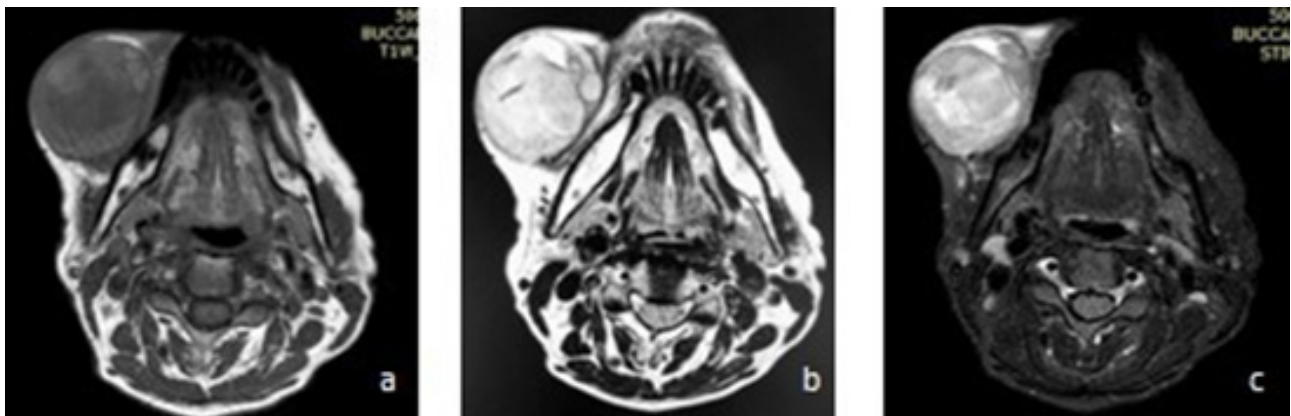


Figure 4: Magnetic resonance of the same patient, **(a)** T1W axial image shows well defined hypointense lesion, **(b)** T2W image shows the lesion as hyperintense with well margined hypointense capsule, **(c)** Short tau inversion recovery (STIR) image show the same lesion stands out as hyperintense with the suppression of fat in the background. A few regions of hyperintensities are seen within the pathology representing as necrosis.

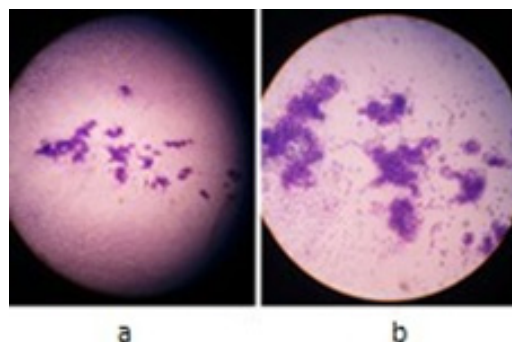


Figure 5: Photomicrograph of the cytology picture, **(a)** smear shows high cellularity, showing epithelial cells arranged in clusters and singly dispersed at places, Individual cells are showing round to oval nuclei, scant amount of cytoplasm and scant stroma in the background of blood and blood components suggestive of monomorphic adenoma, **(b)** Magnified image of the same pathology.

Discussion

Salivary tumors are slightly uncommon and monomorphic adenomas lists among still less common. Batsakis and Brannon [4] have classified the entity on the histological grounds into the following groups:

- arising from terminal duct as basal cell adenoma and canalicular adenoma
- arising from terminal or striated duct as sebaceous adenoma and sebaceous lymphadenoma.
- arising from striated duct as oncocytoma, papillary cystadenoma and lymphomatosum
- excretory duct origin tumors as sialadenoma papillefrum or inverted duct papilloma

Though the exact etiology of these tumors is not known but smoking, vitamin A deficiency and genetic predisposition are considered as the associated factors [5]. The diagnosis of these tumors remains elusive because of their slow growing as well as asymptomatic nature. Ultrasound-guided core needle biopsy is radiation free and safe method for the pathological diagnosis with almost 97% accuracy. This can be performed as outpatient procedure avoiding any hospital stay [6]. The management is for the wider excision of the tumor as there are chances of relapse. The periodic follow-up is necessary in the post-operative period. In malignant pathology, there is role of post-operative radiotherapy with a dose of 60 Gy and of non resectable tumors with 66 Gy [7].

Conclusion

The swelling on the cheek can raise various diagnostic dilemmas as the site for epicenter of the origin of tumor becomes difficult. The presenting features of the swelling are delayed because of the painless nature of the entity. The cytopathological features after cross section imaging confirms the diagnosis to unveil the mystery. The proper management can be undertaken if the nature of the tumor and the staging are confirmed. The surgical wide excision is the answer for these tumors with regular follow as these have got tendency for relapse.

Acknowledgements

None

List of Abbreviations

CECT	contrast enhanced computerized tomography
CFI	Color flow imaging
FNAC	fine needle aspiration cytology
MRI	magnetic resonance imaging
US	Ultrasound

Conflict of Interests

None

Funding

None

Consent for publication

Informed consent was obtained from the patient to present and publish this case.

Ethical approval

Ethical approval is not required at our institution for publishing a case report in a medical journal.

Authors' contribution

NB conducted cross-sectional imaging study, SS conducted the clinical examination and wrote the manuscript, MRA designed the manuscript and collected the references, SD provided the images, SN conducted the Histopathological Study.

All authors contributed in the management of the patient. All of them approved the final version of the manuscript.

Author details

Bharat Bhushan Sharma¹, Naveen Bhardwaj¹, Shweta Sharma², Mir Rizwan Aziz¹, Sakshi Dewan¹, Seema Nagger³

1. Department of Radio-diagnosis, SGT Medical College Budhera (Gurgaon), India.
2. Department of ENT & Head & Neck Surgery, SGT Medical College Budhera (Gurgaon), India.
3. Department of Pathology, SGT Medical College Budhera (Gurgaon), India.

Received: 27 November 2016

Accepted: 11 January 2017

Published online: 17 January 2017

References

1. Batsakis JG, Brannon RB, Sciubba JJ. Monomorphic adenomas of major salivary glands: a histologic study of 96 tumours. *Clin Otolaryngol Allied Sci.* 1981;6:129–43.
2. Koyuncu M, Seşen T, Akan H, Ismailoglu AA, Tanyeri Y, Tekat A, et al. Comparison of computed tomography and magnetic resonance imaging in the diagnosis of parotid tumors. *Otolaryngol Head Neck Surg.* 2003;129:726–32. doi:10.1016/j.otohns.2003.07.009.
3. Pinkston JA, Cole P. Cigarette smoking and Warthin's tumor. *Am J Epidemiol.* 1996;144:183–7.
4. Terhaard CHJ, Lubsen H, Rasch CRN, Levendag PC, Kaanders HHAM, Tjho-Heslinga RE, et al. The role of radiotherapy in the treatment of malignant salivary gland tumors. *Int J Radiat Oncol Biol Phys.* 2005;61:103–11. doi:10.1016/j.ijrobp.2004.03.018.
5. Wan Y-L, Chan S-C, Chen Y-L, Cheung Y-C, Lui K-W, Wong H-F, et al. Ultrasonography-guided core-needle biopsy of parotid gland masses. *AJNR Am J Neuroradiol.* 2004;25:1608–12.
6. Yabuuchi H, Fukuya T, Tajima T, Hachitanda Y, Tomita K, Koga M. Salivary gland tumors: diagnostic value

of gadolinium-enhanced dynamic MR imaging with histopathologic correlation. *Radiology*. 2003;226:345–54. doi:10.1148/radiol.2262011486.

7. Yih W-Y, Kratochvil FJ, Stewart JCB. Intraoral minor salivary gland neoplasms: review of 213 cases. *J Oral Maxillofac Surg*. 2005;63:805–10. doi:10.1016/j.joms.2005.02.021.

Summary of the case

Patient (gender, age)	1	Female, 60 year old
Final Diagnosis	2	Buccal Monomorphic Adenoma
Symptoms	3	Swelling over right cheek
Medications (Generic)	4	N/A
Clinical Procedure	5	Fine needle aspiration cytology
Specialty	6	Otorhinolaryngology
Objective	7	To diagnose the swelling over right cheek
Background	8	Elderly female with swelling of right cheek
Case Report	9	Role of cross-sectional imaging in Cheek swelling
Conclusions	10	Sensitivity of Monomorphic adenoma of minor salivary gland
MeSH Keywords	11	Minor salivary glands, monomorphic adenoma, US, CECT, MRI, FNAC