

## CASE REPORT

# Adolescent fibroadenoma (Breast “Mouse”) – role of Radiology in assisting diagnosis: a case report

B B Sharma<sup>1\*</sup>, Naveen Bhardwaj<sup>1</sup>, Sakshi Dewan<sup>1</sup>, Mir Rizwan Aziz<sup>1</sup>

### ABSTRACT

**Background:** Fibroadenomas are quite common benign lesions in the adolescent age group but it is a cause of concern for the individual and the family. These may remain asymptomatic or may present with pain. Aesthetic distortion of the breast symmetry may lead to psychosocial morbidity in adolescent females. The diagnosis is initially made by the ultrasound. Magnetic Resonance Imaging is done in some cases where the underlying pathology is in doubt.

**Case presentation:** We present a 21 years old young female, university student who reported with complaints of a tender mass in the left breast. Ultrasound (US) of breast showed well circumscribed focus indicating benign nature of the lump. Patient was very anxious. Magnetic resonance imaging (MRI) examinations proved the lesions as fibroadenomas.

**Conclusion:** There is always dilemma for the correct evaluation of the breast lumps but with the help of available cross sectional radiological armamentarium, it is possible to come closer to the diagnosis.

**Keywords:** fibroadenoma, case report, palpable mass, US, MRI.

### Background

Fibroadenomas are benign lesions in the breast and occurs around 2% in adolescent females. This is found in 68% of all the breast masses and 10-15% may be multiple in nature [1]. Though these masses remain asymptomatic but these can cause pain as the size increases. 25 to 40 years of age is the peak incidence period of their occurrence. The entity may be associated with Cowden syndrome where multiple hamartomas are present.

### Case presentation

A 21-years old female presented with palpable mass in the left breast for over one year duration. This became slightly painful off and on, and more during monthly cycles. There was no increase in size of the lump did not increase in this period. Patient was having anxiety for

having this lump in the breast. There was no family history of this disease. There was no history of any previous interventional procedure. The examination of the breast revealed palpable mass on the outer quadrant of left breast which was slightly tender and measured approximate 3 cm x 2.5 cm. Rest of the systemic examination was within normal limits. Biochemical parameters were also within normal limits. Ultrasonography of left breast revealed a hypoechoic mass in left breast. These masses did not have any cystic component and there was no evidence of any calcification (Figure 1). Color flow imaging did not reveal much vascularity (Figure 2). Color doppler spectrum was normal. Ultrasonography of right breast was unremarkable.

---

### Correspondence to:

Dr. Bharat Bhushan Sharma,

\*Department of Radiodiagnosis, Faculty of Medical and Health Sciences,  
SGT University Gurgaon (Haryana) India.

Email: bbhushan986@gmail.com

Full list of author information is available at the end of the article.

© EJMCR

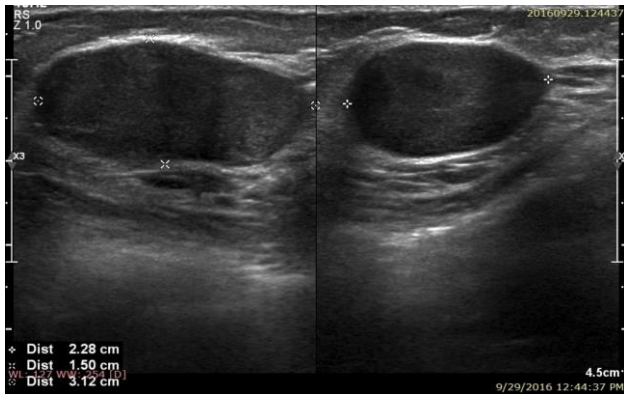<http://www.ejmcr.com>

*Adolescent fibroadenoma (Breast "Mouse")*

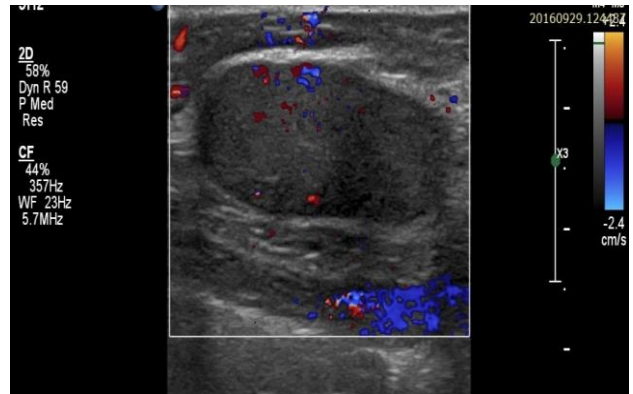
Magnetic resonance study has shown two lesions in the left as well as one lesion in the right breast. These were hypointense on T1W and hyperintense on STIR (short tau inversion recovery) sequences (Figure 3 and Figure 4). Dynamic contrast study was carried out which revealed classical delayed wash out pattern denoting Type 1 enhancement curve (Figure 5 and Figure 6).

Histopathological biopsy confirmed the diagnosis of

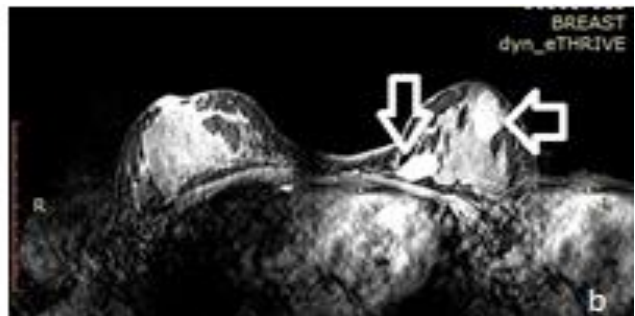
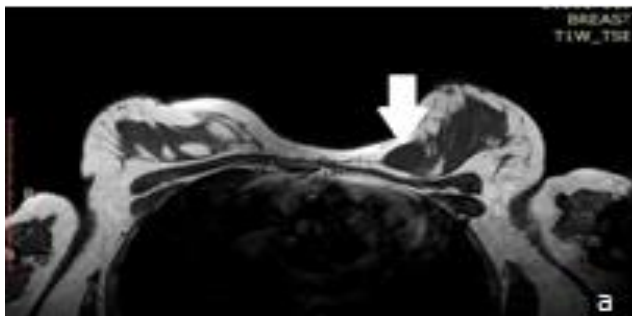
benign fibroadenomas. The specimen had fibroblastic stroma having glandular and cystic spaces lined with luminal epithelial and outer myoepithelial cells. The patient has been put on regular three months monitoring and follow up as the patient is young without any complications. The decision for surgical management will be taken if the tumor increases in size on the grounds of psycho-social-cosmetic reasons.



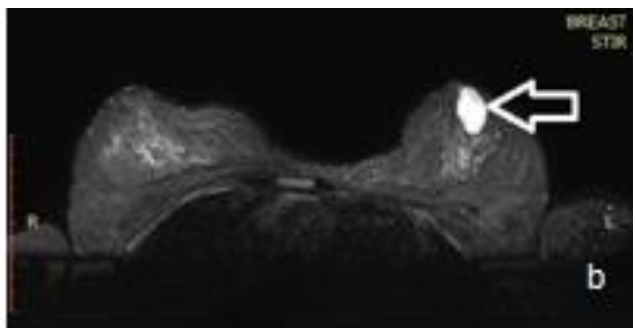
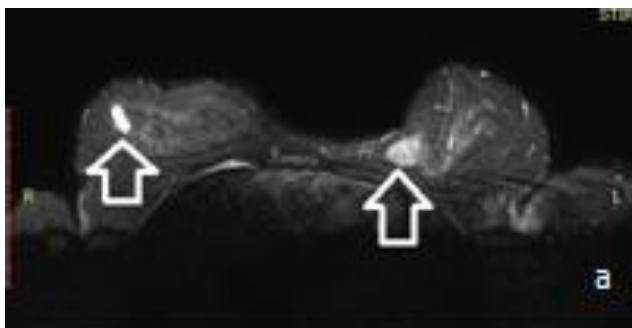
**Figure 1:** Ultrasonographic image of the left breast. There is well defined hypoechoic lesion in the outer upper quadrant which measures 3.12 x 2.28 x 1.5 cm. There is no calcification or necrosis seen.



**Figure 2:** Color flow imaging of the left breast lesion. There was very less vascularity observed in the lesion. The margins were also well defined without any abnormal vessels.



**Figure 3:** MR of both breasts T1W sequences. (a) plain image shows isointense (white solid arrow) lesion in the left breast indistinguishable from the surrounding tissue. (b) T1W image shows moderate enhancement (white horizontal halo arrows) after gadolinium injection. The outer lesion shows a few septations.



**Figure 4:** STIR sequences. (a) Both the breasts show well defined hyperintense lesions (white hollow vertical arrows). (b) Left breast shows another anterior lesion with the same morphological features.

Adolescent fibroadenoma (Breast “Mouse”)

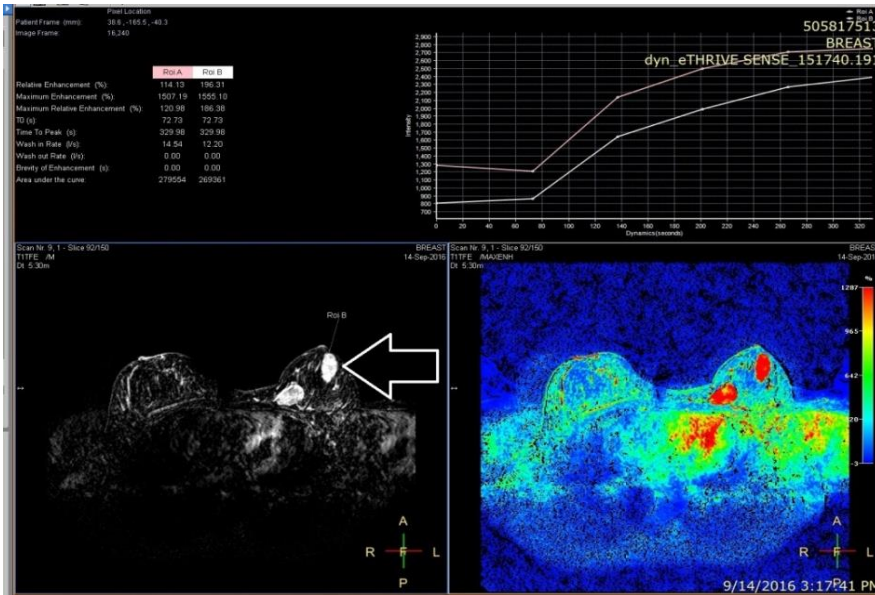


Figure 5: Dynamic contrast study shows the pattern of the contrast enhancement graph in the superficial lesion (horizontal arrow) of the left breast. This shows slow initial enhancement but delayed wash out (Type 1 curve). The curve is drawn as the ratio of maximum intensity change divided by the time interval.

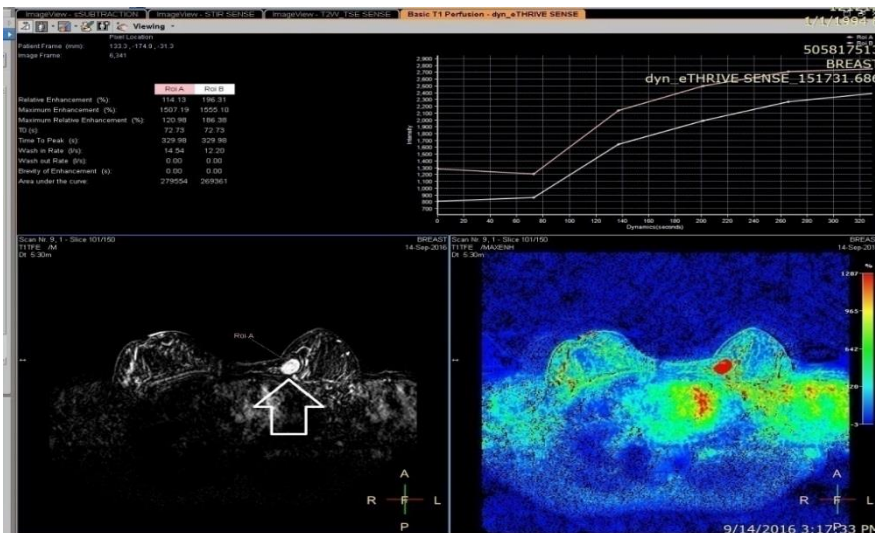


Figure 6: Dynamic contrast study shows the pattern of the contrast enhancement graph in the deeper lesion (vertical arrow) of the left breast with the similar pattern as seen in superficial lesion.

Discussion

Fibroadenoma of the breast is an admixture of epithelial and stromal tissues. These tumors are often called as breast mice because of their mobility in the breast tissue [2]. This should not be confused with fibroadenosis. The entity has to be differentiated from other lumps as the carcinoma can also present in the similar fashion. These are divided into two categories as per their stroma and epithelial cell components as pericanalicular and intracanalicular. These have got intact and compressed glandular spaces respectively. There is proliferation of the stroma in the latter category. Fibroadenoma masses are easy to be removed as compare to the malignant pathologies. These present as solitary firm, mobile, painless, rubbery and slowly growing mass. Sometimes these can be of large size representing as giant fibroadenoma [3]. These occur during the child bearing period and may regress after menopause.

These can be of multiple in nature and can occur bilaterally [4]. This is less prevalent in males because of the hormonal reasons. These arise from lobular stroma of the terminal duct lobular unit. These can be confused with phyllodes tumor as the site of occurrence is same. The exact etiopathology and causative factors of fibroadenomas are not known. Their occurrence is partially related to the sensitivity to the female estrogen hormone [5]. There is some evidence of genetically related to the family history for the occurrence. These are more common during fertility period of females and may regress after menopause [6]. The choice of investigating modality is as per age. Dynamic contrast MR study shows classical delayed wash out graph. This had been depicted in our case also in both the superficial as well as deep lesions. The younger age group can undergo ultrasound and Magnetic

resonance imaging examinations but the patients older than 35 years Mammography is advised in addition to other choices [7]. Contrast MR studies are able to distinguish the benign and malignant masses on the basis of shape, outline, lobulation and internal septation. Benign and malignant pathologies were differentiated by the ratio of maximum intensity change divided by the time interval during which the first occurred. There is so much overlap which requires histopathological confirmation [8]. Regular follow-up and monitoring is best advised [9,10]. In some cases, surgical excision is required and the resection is not that difficult as the margins are very clear. If phyllodes tumor is there, then the margins have to include some part of the breast tissue [11]. Cryotherapy and radiofrequency ablation are the alternative management methods if the patients are young. Regular follow-up at different intervals is done for the evaluation [12, 13].

### Conclusion

Solitary or multiple adolescent fibroadenomas are not uncommon. The diagnosis is very important and great accuracy is achieved with ultrasound coupled with mammography. Mammography should be avoided in adolescent patients. Contrast enhanced dynamic MRI scanning provides strong tool to differentiate fibroadenoma from the malignant pathologies as was in our present case. In majority of cases, monitoring and follow up is done rather than contemplating surgical approach. If the lesion is very big and painful then surgical excision is the answer.

### Acknowledgements

We are thankful to Mrs. Shilpa Singh and Mr. Nitish Virmani of Faculty of Allied Health Sciences of SGT University for assisting in conducting the MR and US studies and acquiring the images.

### List of Abbreviations

MRI	Magnetic Resonance Imaging
USG	Ultrasonography
STIR	Short Tau Inversion Recovery

### Conflict of Interests

The authors declare that there are no conflicts of interest.

### Funding

None

### Consent for publication

Informed consent of the patient was obtained to present and publish this case.

### Ethical approval

The permission from the ethical committee of the institute was taken.

### Authors detail

<sup>1</sup>Dept. of Radio-diagnosis, SGT Medical College, Budhera (Gurgaon), Haryana 122505, India.

### Authors' contributions

BBS wrote the case report and supervised the project. NB Helped in carrying out the USG guided Biopsy and in writing the final manuscript. SD assisted in carrying out investigations, MRA helped in writing the manuscript

---

Received: 10 November 2016

Accepted: 19 December 2016

Published on line: 25 December 2016

---

### References:

1. Santen RJ, Mansel R. Benign breast disorders. *N Engl J Med.* 2005;353(3):275–85.
2. Song BS, Kim E-K, Seol H, Seo J-H, Lee JA, Kim DH, et al. Giant juvenile fibroadenoma of the breast: a case report and brief literature review. *Ann Pediatr Endocrinol Metab.* 2014;19(1):45–8.
3. Gobbi D, Dall'Igna P, Alaggio R, Nitti D, Cecchetto G. Giant fibroadenoma of the breast in adolescents: report of 2 cases. *J Pediatr Surg.* 2009;44(2):e39-41.
4. Williamson ME, Lyons K, Hughes LE. Multiple fibroadenomas of the breast: a problem of uncertain incidence and management. *Ann R Coll Surg Engl.* 1993;75(3):161–3.
5. Sitruk-Ware R, Thalabard JC, Benotmane A, Mauvais-Jarvis P. Risk factors for breast fibroadenoma in young women. *Contraception.* 1989;40(3):251–68.
6. Jayasinghe Y, Simmons PS. Fibroadenomas in adolescence. *Curr Opin Obstet Gynecol.* 2009;21(5):402–6.
7. García CJ, Espinoza A, Dinamarca V, Navarro O, Daneman A, García H, et al. Breast US in children and adolescents. *Radiographics.* 2000;20(6):1605–12.
8. Hochman MG, Orel SG, Powell CM, Schnall MD, Reynolds CA, White LN. Fibroadenomas: MR imaging appearances with radiologic-histopathologic correlation. *Radiology.* 1997;204(1):123–9.

### Adolescent fibroadenoma (Breast “Mouse”)

9. Cerrato F, Labow BI. Diagnosis and management of fibroadenomas in the adolescent breast. *Semin Plast Surg.* 2013;27(1):23–5.
10. Chang DS, McGrath MH. Management of benign tumors of the adolescent breast. *Plast Reconstr Surg.* 2007;120(1):13e–19e.
11. Lakoma A, Kim ES. Minimally invasive surgical management of benign breast lesions. *Gland Surg.* 2014;3(2):142–8.
12. Littrup PJ, Freeman-Gibb L, Andea A, White M, Amerikia KC, Bouwman D, et al. Cryotherapy for breast fibroadenomas. *Radiology.* 2005;234(1):63–72.
13. Dowlatshahi K, Wadhvani S, Alvarado R, Valadez C, Dieschbourg J. Interstitial laser therapy of breast fibroadenomas with 6 and 8 year follow-up. *Breast J.* 2010;16(1):73–6.

#### Summary of the case

<b>Patient (gender, age)</b>	1	Female, 21 year old
<b>Final Diagnosis</b>	2	Adolescent Fibroadenomas
<b>Symptoms</b>	3	Lumps in both breasts
<b>Medications (Generic)</b>	4	Conservative and regular follow up
<b>Clinical Procedure</b>	5	Fine needle aspiration cytology
<b>Specialty</b>	6	Surgery
<b>Objective</b>	7	To diagnose the lump in breast
<b>Background</b>	8	Young female patient with lump in breast
<b>Case Report</b>	9	Role of Radiology in Fibroadenoma
<b>Conclusions</b>	10	Sensitivity of Adolescent Fibroadenoma with dynamic MRI
<b>MeSH Keywords</b>	11	Fibroadenoma, case report, palpable mass, US, MRI.