

CASE REPORT

Accidental ingestion of the endodontic instrument: a case report

Muthhin Almuthhin^{1*}, Abdullah Aljahdali², Mohammad Alzahrani³,
Bader Alhusain⁴, Yousef Algamdi⁵

ABSTRACT

Background: Ingestion of the endodontic instrument during root canal treatment is rare but can result in serious complications.

Case presentation: A 22 year old patient visited ER with complain of something sticking in the throat. He had history of ingestion of endodontic file while undergoing root canal therapy earlier the same day. Through endoscopy the file was found to be in the stomach, and was removed with forceps through over-tube without any complications.

Conclusion: Handling of dental objects requires usage of a rubber dam which is mandatory in modern endodontic practice that protects the patient from inhalation or ingestion of endodontic instruments.

KEYWORDS: Accidental, needle, root canal treatment, swallowing, Endodontic instrument, case report

Background

Ingestion of foreign body is a common clinical problem in children. Ingestion occurs in adults too but is most of the times accidental; or it occurs in psychiatric patients or iatrogenic reasons when rubber dam is not used. In dental operator, the ingested foreign body may include teeth, restorations, restorative materials, instruments, rubber dam clamps, gauze packs, and so forth [1–3]. Similar case studies have also been reported previously [4]. Grossman [5] determined that 87% of the ingested foreign bodies enter the gastrointestinal tract, and 13% enter the respiratory tract. Most of the foreign bodies that enter the gastrointestinal tract pass spontaneously. There are both surgical and non-surgical interventions available to remove the ingested foreign body. This paper discusses a case report of accidental ingestion of endodontic file and its management.

Case Presentation

A 22-years-old Saudi male came to ER with a recent history of foreign body ingestion. The patient was in good health and had no history of bowel disease. The patient had visited his dentist that morning for root canal. The dentist used endodontic file without rubber dam, it had accidentally fallen down at the back of the throat of the patient. The patient was asked to check his throat at that very instant but nothing was found. Chest x-ray was done in a private hospital, which showed a foreign body at the lower chest. So the patient was advised to go to a higher center. He came to National Guard Hospital and got X-ray done (Figure 1&2) which showed the foreign body at the upper abdomen.

Urgent endoscopy was done finally (Figure 3), which revealed a sharp object (endodontic file) at the fundus of the stomach. It was removed smoothly using forceps through over-tube without any complications.

Correspondence to:

Muthhin Almuthhin,

*Alzammami Dental Center, Riyadh, Saudi Arabia.

Email: almodhen.m@gmail.com

Full list of author information is available at the end of the article.

©EJMCR

<http://www.ejmcr.com>

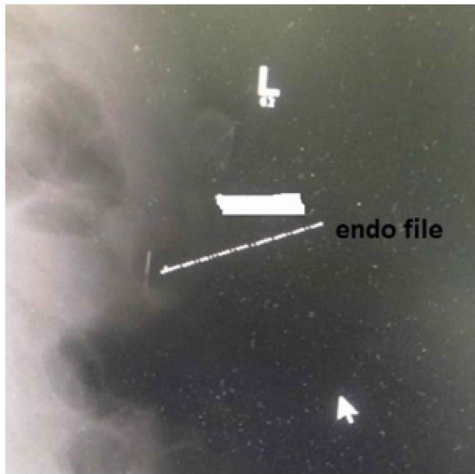


Figure 1: Shows endodontic file at the lower chest.

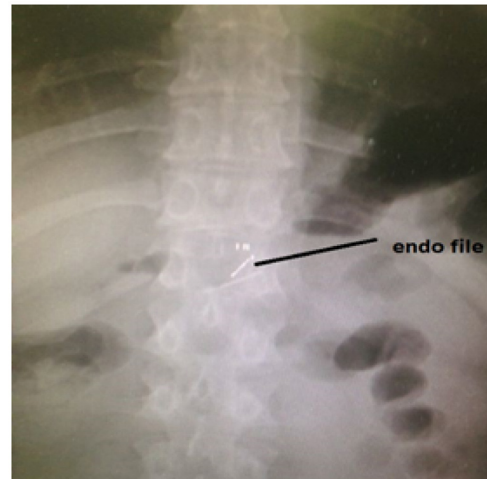

Figure 2: Shows endodontic file inside body.

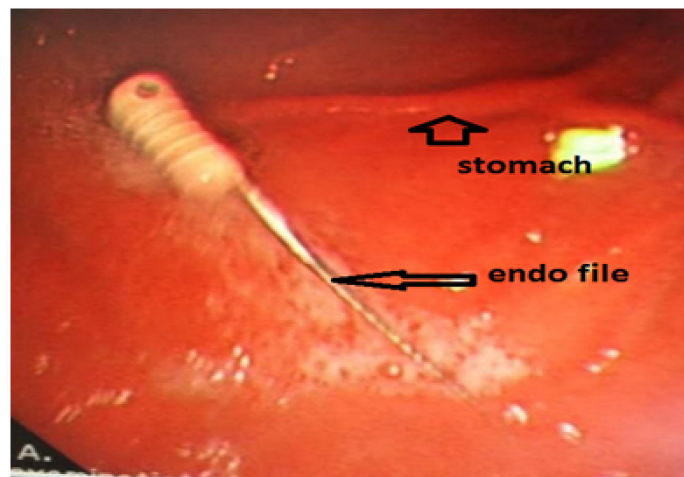


Figure 3: Shows endoscopy results.

Discussion

Ingested foreign bodies that lodge into gastrointestinal tract pass through the gastrointestinal tract within a few days to a month [6]. When such cases are not diagnosed or treated appropriately, it may cause serious complications. Owing to the shape and sharpness of the instrument, there are chances of perforation. Once the instrument is lost in the oropharynx, it is very important to determine whether the instrument has entered the digestive tract or the respiratory tract. Radiographic examination with posteroanterior and lateral chest radiograph, abdominal radiograph is mandatory for determining the location, size, and nature of the foreign body. In the reported case chest and abdomen, radiographs were advised as the patient was complaining of something sticking in throat. In case of foreign body that is radiolucent, other diagnostic methods are suggested that include computed tomography, magnetic resonance imaging, and endoscopy.

Ninety percent of the ingested foreign bodies pass through the gastrointestinal tract uneventfully. Similar to the present case endodontic file has been previously reported to pass out through the gastrointestinal system within 3 days without incident [7]. If the foreign body that has passed into the stomach and is less than 6 cm in length and 2 cm in diameter, there is 90% chance of passage through pylorus and ileocaecal valve [8]. With sharp object, the most common sites of perforation are the lower esophagus and terminal ileum [9]. Abdominal pain and/or a positive stool occult blood test may indicate signs of intestinal perforation, impaction, or obstruction; medical or surgical intervention for removal is required in such cases. Entry of a foreign body into the respiratory tract is potentially life threatening. Ingestion or aspiration of foreign bodies can be easily prevented by the universal use of rubber dam isolation [10]. Flexible rubber dam

frames are available, which can facilitate radiographs during treatment without removal of frame. It offers effective protection against aspiration or swallowing of endodontic instruments, broken burs, restorative materials, and pins. While the rubber dam reduces the risk of aspiration during restorative procedures, it is possible for the dam clamp itself to be aspirated. To reduce this risk, dental floss should be tied to secure rubber dam clamp [11]. Electronic apex locators can also be useful for working length determination avoiding rubber dam frame removal. Many dental techniques preclude the use of the rubber dam, particularly during routine oral surgery and prosthodontic procedures. An alternative is to place a 4 × 4-inch gauze protective barrier in the oral cavity distal to the area. The dentist may also prevent cast restoration being aspirated by using dental floss. Dentist should also instruct patients that if an object falls on the tongue, they should try to suppress the swallowing reflex and turn their heads to the side. An impression procedure may put a patient at a risk of aspirating the impression material if a large amount of material and/or low viscosity material is introduced to the posterior oral cavity. Therefore, use of the most viscous material that will achieve the desired level of accuracy for the impression procedure is recommended [12].

Other strategies to prevent aspiration of foreign bodies include use of high-velocity evacuation, Washfield technique, use of a custom tray, with an open palate design for maxillary arch impression, a more upright position if possible and provision of thorough instructions to the patients. Tooth isolation using the dental dam is the standard of care; it is integral and essential for any nonsurgical endodontic treatment [13].

Conclusion

Handling of dental objects requires usage of a rubber dam that is mandatory in modern endodontic practice, which is to protect the patient from the inhalation or ingestion of endodontic instruments. Tooth isolation using the dental dam is the standard of care; it is integral and essential for any nonsurgical endodontic treatment. More safety precautions and care should be provided to the patient.

Acknowledgements

None

List of Abbreviations

None

Conflict of Interests

None

Funding

None

Consent for publication

Informed consent has been obtained from the patient to publish this case.

Ethical approval

Ethical approval is not required at our institution for publishing a case report in a medical journal while not revealing the identity of the subject.

Author details

Muthhin Almuthhin¹, Abdullah Aljahdali², Mohammad Alzahrani³, Bader Alhusain⁴, Yousef Algamdi⁵

1. Alzammami Dental Center
2. GI Consultant in national guard hospital
3. General Dentist at military hospital
4. Consultant in restorative dental department at military hospital
5. Consultant in prosthodontic dental department at Ministry of Health

Authors' contribution

All author contributed substantially in managing the patient and writing this case report. All authors approved the final version.

Received: 22 May 2017

Accepted: 21 June 2017

Published online: 25 June 2017

References

1. Holan G, Ram D. Aspiration of an avulsed primary incisor. A case report. *Int J Paediatr Dent.* 2000;10:150–2.
2. Tiwana KK, Morton T, Tiwana PS. Aspiration and ingestion in dental practice: a 10-year institutional review. *J Am Dent Assoc.* 2004;135:1287–91.
3. Hill EE, Rubel B. A practical review of prevention and management of ingested/aspirated dental items. *Gen Dent.* 2008;56:691–4.
4. Hashmi S, Walter J, Smith W, Latis S. Swallowed partial dentures. *J R Soc Med.* 2004;97:72–5.
5. Grossman LI. Prevention in endodontic practice. *J Am Dent Assoc.* 1971;82:395–6.
6. Leith R, Fleming P, Redahan S, Doherty P. Aspiration of an avulsed primary incisor: a case report. *Dent Traumatol.* 2008;24:e24–26. doi:10.1111/j.1600-9657.2008.00593.x.
7. Kuo S-C, Chen Y-L. Accidental swallowing of an endodontic file. *Int Endod J.* 2008;41:617–22. doi:10.1111/j.1365-2591.2008.01392.x.
8. Govila CP. Accidental swallowing of an endodontic instrument. A report of two cases. *Oral Surg Oral Med Oral Pathol.* 1979;48:269–71.
9. Weiland ST, Schurr MJ. Conservative management of ingested foreign bodies. *J Gastrointest Surg.* 2002;6:496–500.
10. Saraf HP, Nikhade PP, Chandak MG. Accidental Ingestion of Endodontic File: A Case Report. *Case Reports in Dentistry.* 2012;2012:e278134. doi:10.1155/2012/278134.

11. Cameron SM, Whitlock WL, Tabor MS. Foreign body aspiration in dentistry: a review. *J Am Dent Assoc.* 1996;127:1224–9.
12. Kimberly DR. Unrecognized aspiration of a mandibular incisor. *J Oral Maxillofac Surg.* 2001;59:350–2. doi:10.1053/joms.2001.21012.
13. American Association of Endodontists. AAE Position Statement. 2010. Available at: http://www.aae.org/uploadedfiles/publications_and_research/guidelines_and_position_statements/dentaldamstatement.pdf (accessed January 2017).

Summary of the case

Patient (gender, age)	1	A 22-years-old Saudi male
Final Diagnosis	2	Ingestion of endodontic instrument
Symptoms	3	Complain of something sticking in the throat.
Medications (Generic)	4	none.
Clinical Procedure	5	chest x ray, endoscopy
Specialty	6	Gastro, dentistry
Objective	7	Removing the endodontic instrument
Background	8	Ingestion of the endodontic instrument during root canal treatment is rare but can result in serious complications.
Case Report	9	The present paper reports a case in which endodontic file was accidentally swallowed by the patient undergoing root canal therapy, which entered into the stomach and the dentist did not use the rubber dam in his private clinic which is mandatory in root canal treatment.
Conclusions	10	Handling of dental objects requires for using of a rubber dam is almost mandatory in modern endodontic practice which is to protect the patient from the inhalation or ingestion of endodontic instruments.
MeSH Keywords	11	needle; root canal treatment; swallowing; Endodontic instrument, case report