

Synchronous genital and facial hematohidrosis in adult female: first case report from Egypt

Mosaad Soliman^{1*}, Khaled Mowafy¹, Rana Soliman², Reem Soliman¹

European Journal of
Medical Case Reports

Volume 3(1):28–32

© EJMCr. <https://www.ejmcr.com/>

Reprints and permissions:

<https://www.discoverpublish.com/>

<https://doi.org/10.24911/ejmcr/>

173-1538850634



ABSTRACT

Background: Hematohidrosis, also known as hematidrosis or bloody sweat, is a rare condition manifested by sweaty spotty bleeding out of the skin and mucous membranes. Apart from sporadic case reports from around the world, there is a lack of formal study that describes the exact incidence. There is uncertainty of the etiopathogenesis. However, rupture of the capillary ramification around the sweat glands due to severe physical or mental stress has been proposed as an explanation, in addition to some other disorders as a systemic disease and vicarious menstruation. Diagnosis is being confirmed by testing the secretions for blood components.

Case Presentation: Herein, we report a case of hematohidrosis in a 28-year-old female with repeated episodes of bloody sweating from all over the face, the genitalia, and the fingertips that have been responding to propranolol and topical timolol.

Conclusion: Being a rare disorder, the diagnosis is substantially dependent on high clinical suspicion and physician awareness, which is of paramount importance in patient's assurance that helps in the alleviation of psychological stress. We assume that the sympathetic overactivity is pivotal in provoking these events and that beta blockers might be an effective treatment.

Keywords: Hematidrosis, stress, propranolol, timolol, case report.

Received: 12 October 2018

Accepted: 21 January 2019

Correspondence to: Mosaad Soliman

*Head of Vascular Surgery Department, Mansoura University Hospitals, Mansoura, Egypt.

Type of Article: CASE REPORT

Funding: None

Email: Soliman_mosaad@hotmail.com

Declaration of conflicting interests: None

Full list of author information is available at the end of the article.

Background

This is a rare phenomenon characterized by blood oozing from normal skin and intact mucosa. By definition, it refers to bloody sweat where blood is mixed with sweat like material. It is a condition in which the capillary blood vessels feeding the sweat glands rupture, causing exudation of blood. It is sometimes described as “hematofolliculohidrosis” because of blood appearing along with sweat like fluid and exuding through the follicular canals [1]. Historically, this condition was reported in a soldier under extreme stress by Da Vinci and also in Jesus Christ at the time of the crucifixion. It is attributed to a variety of etiological factors as a part of systemic disorders, vicarious menstruation, blood disorders, excessive exertion, and psychogenic or idiopathic causes [2]. It is inferred that the treatment of the underlying etiology partly helps in the remission of symptoms.

Case Description

A 28-year-old female presented with recurrent episodes of bleeding from all over the face, vulva, perineum, and fingertips for 6 months. Each bleeding episode lasted for about 30 seconds, happening any time by day and night, but never at sleep. Attacks always subside spontaneously without pain, itching, or residual stains on the skin after cleaning up. The consistency of blood was, however,

thinner and it appeared as blood-stained fluid. Several years ago, the patient reported bouts of a headache, shortness of breath, palpitation, dizziness, and sometimes syncope. Clinical examination during the episodes revealed tachycardia (pulse above 140), tachypnea, and hypotension (blood pressure 80/60). Sexual remarks were boisterous as the patient reported itchy bloody edematous introitus following regular relationship despite the intensive use of lubricants and soothing agents. The patient does not give a history of anticoagulants intake, topical application of medication, or exposure to dyes. There is no history of any chronic medical condition or similar history in the family.

The bleeding episodes were intermittent rather than periodic and unrelated to menstrual cycles excluding vicarious menstruation. Routine clinical examination did not show any abnormality. We witnessed two episodes of bleeding from the face (Figures 1–3) and fingertips (Figures 4 and 5) and both were by night and preceded by an intense headache. On examination, the extruded secretion was bright red, more fluidly than blood. The skin over the face was intact with no sign of injury.

The secretion was wiped for the benzidine test, blood grouping and histological examination, and following mopping, no more bleeding was noticed.

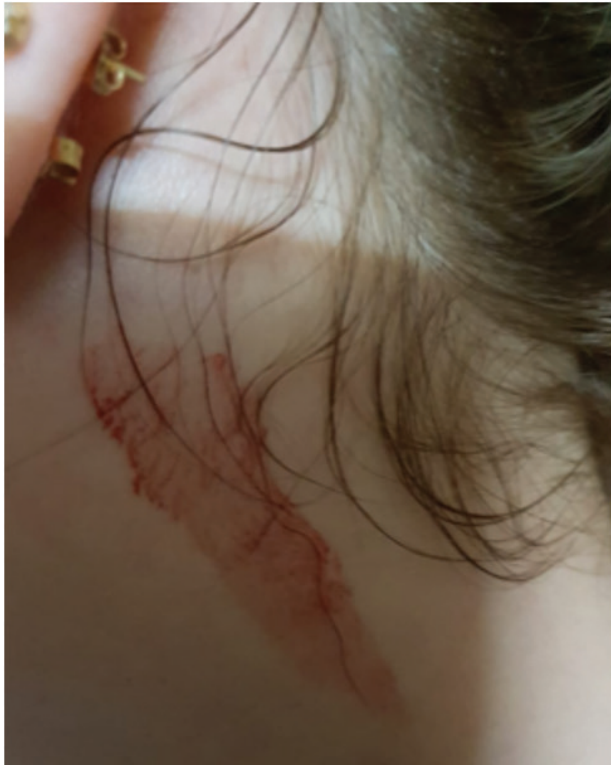

Figure 1. A photograph showing hematidrosis from the neck.

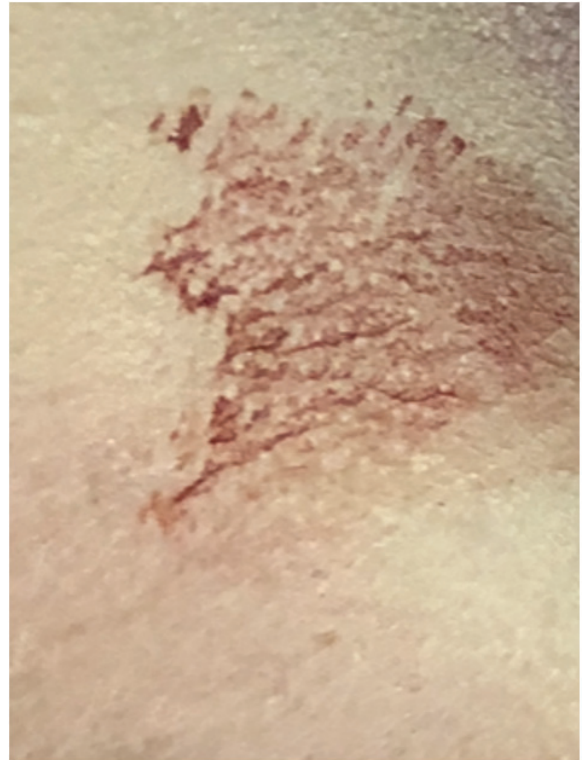

Figure 2. A magnified photograph of hematidrosis of the skin of the face.

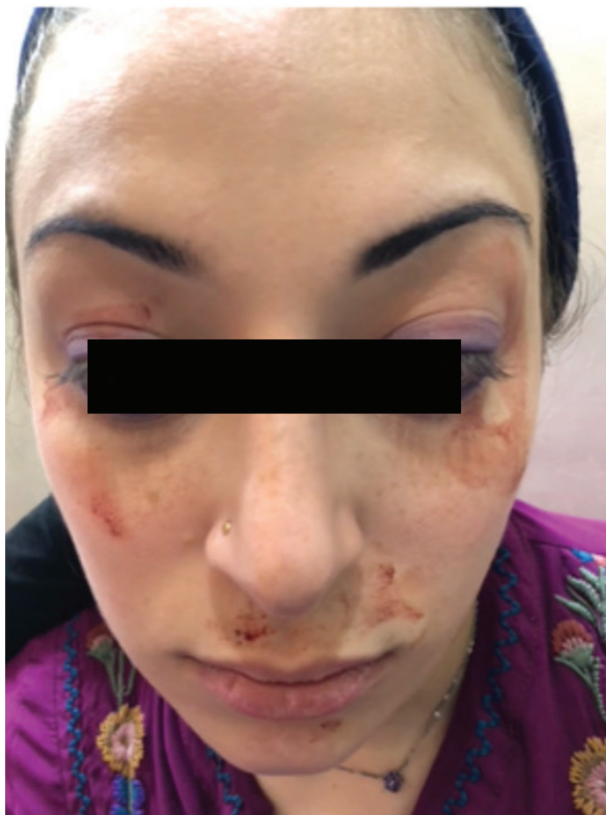

Figure 3. (a) A photograph showing hematidrosis from all over the face. (b) A photograph following subsidence of the episode.

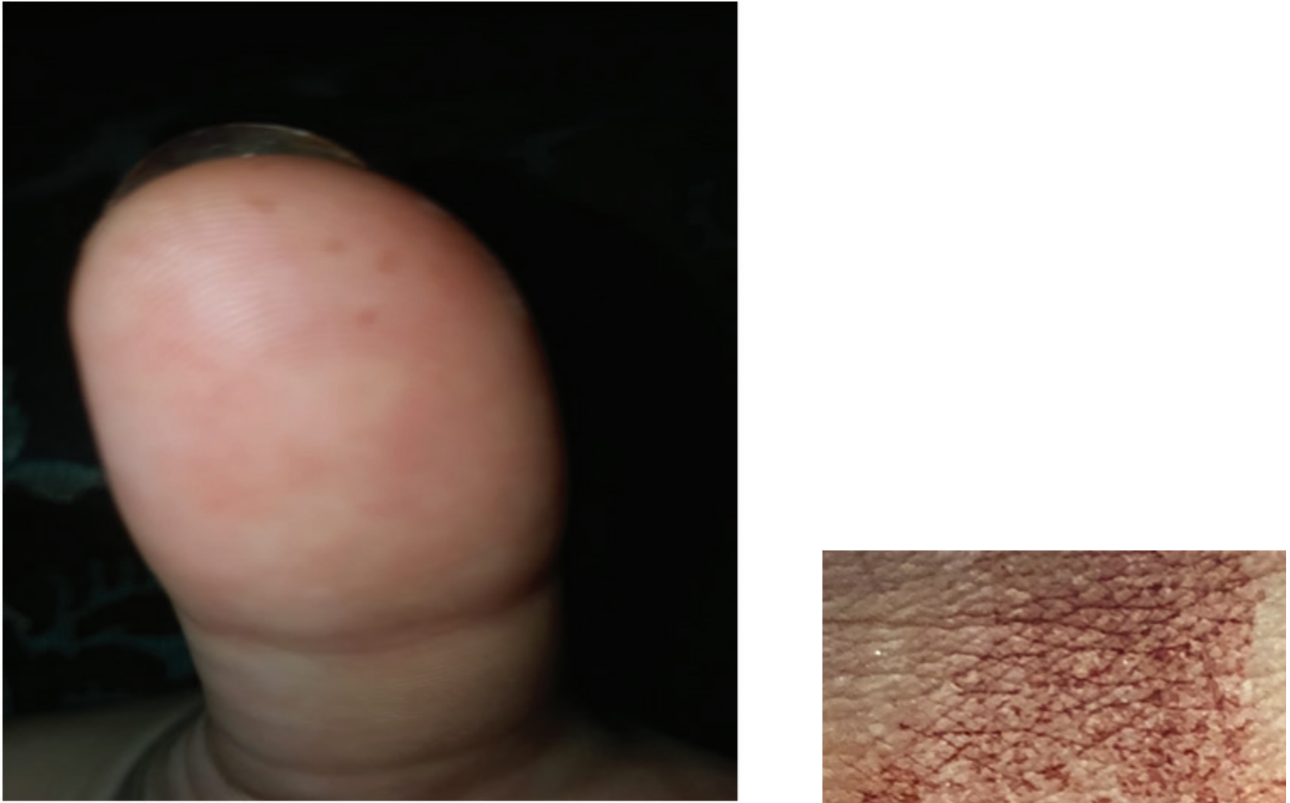

Figure 4. (a) A photograph showing hematohidrosis of the fingertip. (b) A magnified photograph of the fingertip.

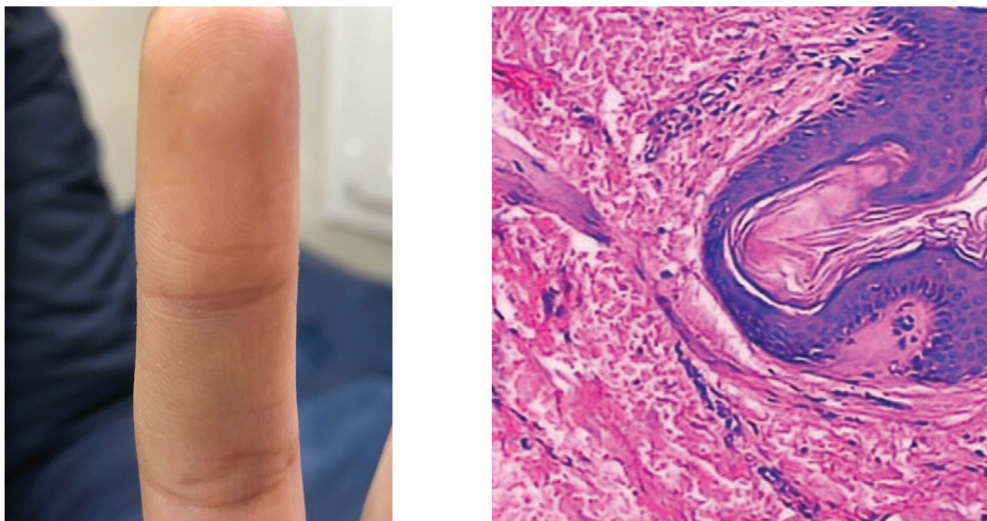


Figure 5. Healthy skin of fingertip following remission. Microscopic picture of skin biopsy showing normal sweat gland structure (hematoxylin and eosin stain, magnification hi. 2).

Examination of the blood-stained fluid under microscopy revealed peripheral blood components as red blood cell (RBC), leucocytes, platelets, and epithelial cells but no abnormal cells.

The collected skin blood was matching with the patient's blood group. Complete blood count, routine blood biochemistry, immunological tests, thyroid function tests, hepatitis markers, chromogranin A and 5-hydroxyindolacetic acid were within normal

limits. Prothrombin time (PT), activated partial thromboplastin time (APTT), and thrombin time were normal. Abdominal ultrasound revealed no abnormality.

Skin biopsy was performed during the time of active bleeding. A diagnosis of hematohidrosis was considered and psychological support, as well as propranolol was given systemically at a dose of 2 mg/kg in two-divided doses in addition to timolol gel applied topically to the perineal area did ameliorate the symptoms and ceased the episodes.

Discussion

Hematohidrosis is an enigmatic clinical condition that manifests as recurrent self-limiting episodes of bloody secretion through intact skin [3]. Several mechanisms have been postulated to explain the phenomenon, including elevation of capillary pressure due to mental or physical stress leading to extravasation of blood cells into the sweat glands, vasculitis of dermal vessels, and sympathetic overactivity leading to vasospasm followed by vasodilation of the periglandular vessels that end in extrusion of blood contents into ducts [1].

The observation of intradermal bleeding and obstructed capillaries but otherwise normal skin appendages favors the underlying vasculitis [4]. The disease can affect any territory and may occur at several points at the same time with brisk self-controlled bleeding.

The face is the commonest site of affection; however, other sites of involvement have been reported including the eyes, ears, limbs, trunk, and less frequently the palm and sole [5]. In the current case, the simultaneous bleeding from face, genitalia, and perineum raises the question of the selectivity of sites of involvement and the possibility of autonomic triggering of these sites controlled by overwhelming stress leading to sympathetic overflow to the dermal structures with repetitive vasoconstriction and dilatation ending in rupture of exceptionally fragile periglandular capillaries.

This mechanism is similar to the issue of induction of excessive sweating in hyperhidrosis in response to stress but in an exaggerated fluctuating way. Several criteria have been proposed to make the diagnosis of hematohidrosis, including bloody sweat through intact skin containing cellular blood components and witnessed by health provider [6].

The aforementioned criteria were fulfilled in our case but to our knowledge, the genital and perineal sites were unusual sites of involvement. Skin biopsy showed some misty abnormalities, with normal sweat gland containing no blood, and bloody exudate also observed in some areas that do not contain sweat glands. This observation was confirmed in a similar report [7] and concluded that the blood was mixed with a sweat-like fluid, rather than real sweat.

The patient presented with bouts of a headache, tachypnea, and abdominal colic before each episode of skin exudation, which invokes a similarity to carcinoid syndrome; nevertheless, the specific laboratory work up turned-out to be normal. Other conditions that demand differentiation from this phenomenon are chromhidrosis and hemorrhagic dyscrasias with the absence of blood cells in the red sweat in the former and absence of laboratory abnormalities in hemostatic function in the later [8].

As the pathoetiology is enigmatic, management remains a dilemma with no known definitive therapy apart

from partial success using anxiolytics [1] atropine transdermal patch [9] and several reports of good response to propranolol [4,7]. In the present case, we prescribed both anxiolytic and propranolol medication in addition to psychological and social support that succeeded in the alleviation of the stressful insults that triggers the episodes that ameliorate totally apart from the bouts of headache but without hematohidrosis.

Conclusion

Hematohidrosis is a very rare and inscrutable disorder with evasive triggers, causes, mechanism, and histopathology. Although both affected individuals and their peers panic at the sight of blood, especially in the face, it seems of little impact on the general health. We report an unusual site of involvement in the genital and perineal area that evoked simultaneously with the face. The dramatic response achieved in this case emphasizes on the value of psychological and social factors as a correctable entity in the disorder management; moreover, the role of propranolol as a target blocker of sympathetic overactivity cannot be overlooked.

List of Abbreviations

APTT	Activated partial thromboplastin time
PT	Prothrombin time
RBC	Red blood cell

Consent for publication

The authors certify that they have obtained the needed patient consent forms. This entailed consent that her images and the clinical scenario will be published in the journal with the reservation that her name and initials will not be revealed.

Ethical approval

There is no ethical approval required by the institute.

Author details

Mosaad Soliman¹, Khaled Mowafy¹, Rana Soliman², Reem Soliman¹

1. Department of vascular surgery, Mansoura University, Egypt
2. Department of dermatology. Mansoura University, Egypt

References

1. Manonukul J, Wisuthsarewong W, Chantorn R, Vongirad A, Omeapinyan P. Hematidrosis: a pathologic process or stigmata. A case report with comprehensive histopathologic and immunoperoxidase studies. *Am J Dermatopathol*. 2008;30(2):135–9. <https://doi.org/10.1097/DAD.0b013e318164cf4b>
2. Holoubek JE, Holoubek AB. Blood, sweat and fear. A classification of hematidrosis. *J Med*. 1996;27:115–33.
3. Patel RM, Mahajan S. Hematohidrosis: a rare clinical entity. *Indian Dermatol Online J*. 2010;1(1):30–2. <https://doi.org/10.4103/2229-5178.73256>
4. Zhang FK, Zheng YL, Liu JH, et al. Clinical and laboratory study of a case of hematidrosis. *Zhonghua Xue Ye Xue Za Zhi*. 2004;25(3):147–50.
5. Arakkal GK, Poojari S, Netha GN, Kumar BU. Hematohidrosis: a rare case of a female child who

- sweat blood. *Indian J Paediatr.* 2017;18:327–9. <https://doi.org/10.4103/2319-7250.193031>
6. Tshifularo M. Blood otorrhea: blood stained sweaty eardischarges: hematohidrosis; four case series (2001–2013). *Am J Otolaryngol.* 2014;35:271–3. <https://doi.org/10.1016/j.amjoto.2013.09.006>
 7. Wang Z, Yu Z, Su J, Cao L, Zhao X, Bai X, et al. A case of hematohidrosis successfully treated with propranolol. *Am J Clin Dermatol.* 2010;11(6):440–3. <https://doi.org/10.2165/11531690-000000000-00000>
 8. de Moerloose P, Levrat E, Fontana P, Boehlen F. Diagnosis of mild bleeding disorders. *Swiss Med Wkly.* 2009;139:327–32.
 9. Biswas S, Surana T, De A, Nag F. A curious case of sweating blood. *Indian J Dermatol.* 2013;58:478–80. <https://doi.org/10.4103/0019-5154.119964>

Summary of the case

Patient (gender and age)	1	28 years-female
Final diagnosis	2	Hematohidrosis
Symptoms	3	Episodes of bloody sweating from the face and genitalia
Medications	4	Psychotherapy, propranolol, and timolol
Clinical procedure	5	Medical and psychotherapy
Specialty	6	Vascular surgery and vascular medicine