

Trans-sphenoidal endoscopic endonasal surgery is a safe, effective, and the first-line treatment for pituitary adenomas, especially in elderly patients for both symptom control and better functional outcomes [9]. With the use of improved peri-operative care, the technique used in trans-sphenoidal surgery is associated with good outcomes, minimal morbidity, and generally well tolerated by patients of all age groups [10]. A wait-and-see approach may be adopted in non-functioning pituitary macroadenomas not encroaching or involving the optic chiasm. Post-operative radiotherapy should be individualized according to patients after a surgical procedure but can be considered in patients having large post-operative remnants of the tumor. Careful examination, laboratory evaluation, and replacement of pituitary insufficiencies should be considered during follow-up of the patient. Magnetic resonance imaging of the brain is advised with an interval of 1–3 years [6].

While comparing endoscopic endonasal and microscopic trans-sphenoidal surgery, endoscopic endonasal surgery has a better outcome and complete cure on follow-up [11].

We present one such case where it was challenging to diagnose pituitary adenoma in a patient who presents simply with hyponatremia.

Case Report

A 61-year-old female who was diagnosed 1 year back as hypothyroid was on thyroxine for 4 months but she left her medication without consulting her endocrinologist. This time she presented in Hospital Emergency Department with the history of vomiting, drowsiness, and fatigue for the last 2 days before presentation. There was no history

of fever, headache, loss of consciousness, fits, or diarrhea. On examining the patient, she was drowsy but arousable and maintaining her vitals i.e.: Bp 125/82 mmHg, pulse 79/minute, afebrile, oxygen saturation 98% at room air, R/R 16/minute, jugular venous pressure (JVP) not raised, no signs of dehydration, or pedal edema. On central nervous system (CNS) examination, Glasgow coma scale (GCS) was 14/15 with no neurological deficit or signs of meningeal irritation, all other systemic examination was unremarkable. On investigating, complete blood picture, liver function test, renal function tests, urine R/E, and chest X-rays were normal. Serum electrolytes showed sodium levels of 112 mEq/l, potassium and chloride were normal. We made the impression of euvoletic hyponatremia in the presence of a background of untreated hypothyroidism. We started counting the differentials of the syndrome of inappropriate ADH secretion, untreated hypothyroidism or hypopituitarism and requested her following labs:

Tests requested	Values	Impression
ft3	1.04 nmol/l	Low
ft4	11.01 pmol/l	Low
TSH	3.44 mIU/l	Low
Serum osmolarity	259 mOsm/kg	Low
Urine osmolarity	288 mOsm/kg	Normal
Urinary sodium	88 mEq/day	Normal
FSH	3.33 mIU/ml	Low
LH	0.59 mIU/ml	Low
Prolactin	544 mIU/l	Normal
Estrogen	10 pg/ml	Low
Progesterone	0.01 ng/ml	Low

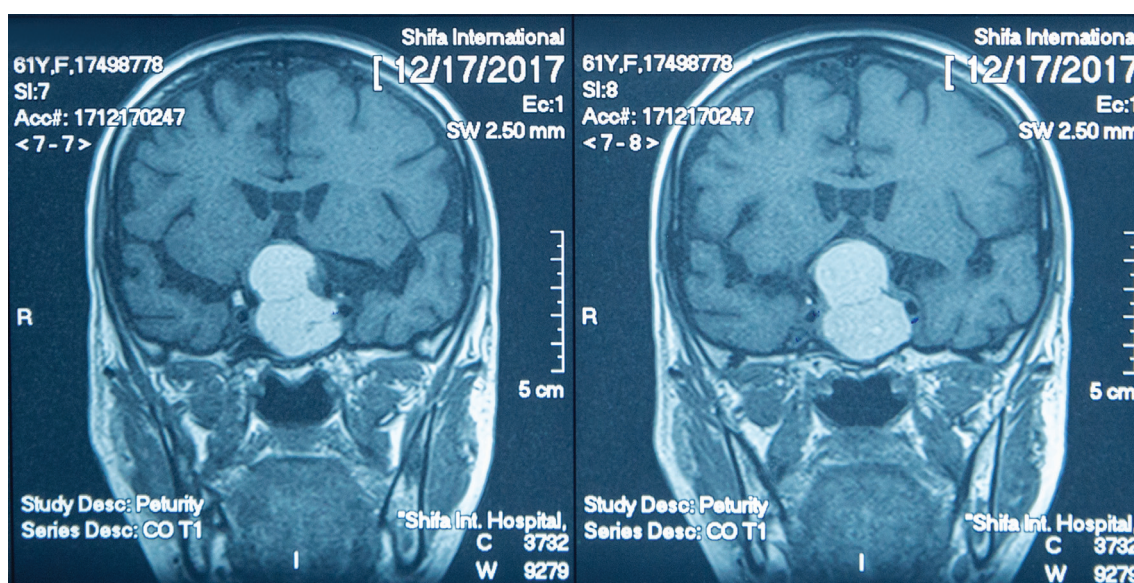

Figure 1. Post-contrast T1 brain MRI image, coronal view, showing a pituitary adenoma, showing suprasellar extension. The indent at diaphragm sellae is giving it a “snow-man” configuration, which is a differentiation between pituitary macroadenoma and meningioma.

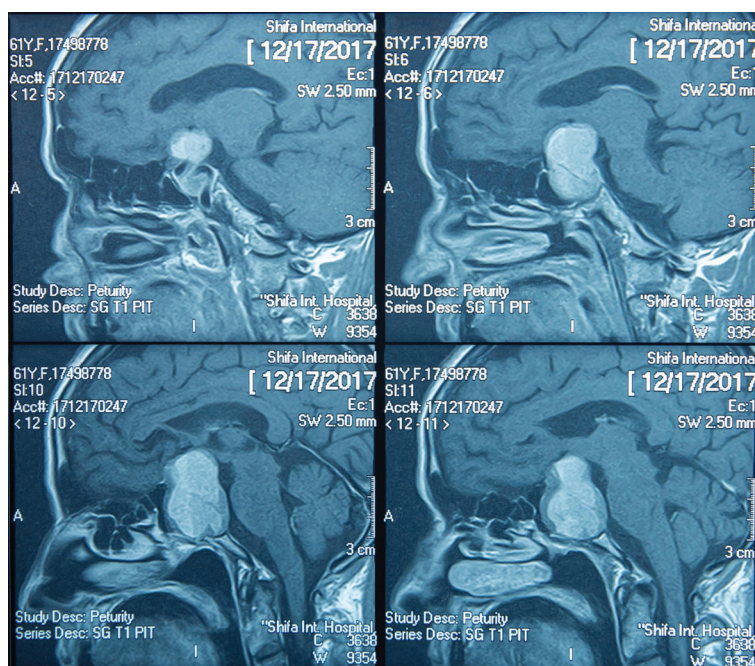


Figure 2. Post-contrast T1 brain MRI images, sagittal view showing pituitary macroadenoma, suprasellar component of this lesion is elevating optic nerves and optic chiasm with stretching.

In view of these labs, we made the impression of secondary hypothyroidism or adrenal insufficiency and both coming under the umbrella of hypopituitarism. We gave her 3% saline and intravenous steroids and after that gave her thyroxine 100 µg once daily. Patient dramatically responded to this treatment within 24 hours and her GCS became 15/15. Serum sodium came up to 135 mEq/l. we further wanted to explore the cause of hypopituitarism and did the MRI brain with contrast which showed that sella was markedly enlarged and expanded, pre- and post-contrast dynamic thin section study of sella and pituitary shows sella to be occupied by 4.0 × 4.2 × 3.3 cm [transverse view (TR) × cranio-caudal view (CC) × antero-posterior view (AP)], intra- and supra-sellar mass lesion. Suprasellar component of this lesion is elevating optic nerves and optic chiasm with stretching. Pituitary stalk is not well delineated and is elevated and stretched.

In short, we would like to conclude our case as a non-functioning pituitary macroadenoma, which presented with hypopituitarism complicated by hyponatremia and was treated with hormone replacement therapy and hypertonic saline.

Discussion

Our patient was finally diagnosed as having a non-functional pituitary adenoma revealing itself as hyponatremia. The diagnosis was based on a high index of suspicion, laboratory investigations, and tapering off our differentials. She was a middle-aged lady in her early sixties, having no established pre-morbid and presented with hyponatremia.

All pituitary hormonal assays were low and MRI brain gave us confirmation of our diagnosis. Most of the cases published, to date, showed that the patients were in their seventh decade of their life [3,5,9]. Also, they presented mostly with common symptoms like headache, visual impairments, or with symptoms of panhypopituitarism [4,5,7]. Our patient had certain distinct clinical features, including her age of early 60s, no clinical signs of panhypopituitarism, and presented with hyponatremia which is a very rare entity of this disease. So far, very few cases have been reported in the literature in which hyponatremia is the only presenting feature which leads to the diagnosis [3,8,12].

She was treated successfully with 3% saline, intravenous steroids, and hormone replacement therapy. Treatment response was obtained after 24 hours. In most of the cases, the patient needs the only treatment with steroids and hormone replacement [1,8,12]. Surgical intervention is needed only in those cases, in whom adenoma compresses the optic chiasm and causing distressing symptoms.

Conclusion

Hyponatremia can be the leading manifestation of hypopituitarism. It can be the first presenting feature before other common symptoms of pituitary macroadenoma appear, but it is rare and can be life-threatening.

Our patient was diagnosed as having NFPA depending on the high index of suspicion for clinical presentation and she was successfully treated with steroids and hormonal replacement therapy. Hypopituitarism can be easily

diagnosed but the key to diagnosis is strong clinical suspicion. Hormone assays should be included in the initial diagnostic workup of hyponatremia, especially in elderly people.

Acknowledgment

The authors wish to thank the staff of Pakistan Atomic Energy Commission General Hospital.

List of Abbreviations

- CNS central nervous system
- GCS Glasgow coma scale
- JVP jugular venous pressure
- MRI Magnetic resonance imaging
- NFPA non-functioning pituitary adenoma

Consent for publication

Informed consent was obtained to publish this case report.

Ethical approval

Institutional approval was obtained in compliance with the regulation of our institution and generally accepted guidelines governing such work.

Author details

Faryal Mehmood¹, Anum Ashfaq², Muhammad Atif Beg³

1. Consultant Endocrinologist, Pakistan Atomic Energy Commission General Hospital, Islamabad, Pakistan
2. Post-Graduate Resident, Department of Medicine, Pakistan Atomic Energy Commission General Hospital, Islamabad, Pakistan
3. Head of the Department of Medicine, Pakistan Atomic Energy Commission General Hospital, Islamabad, Pakistan

References

1. Rajput R, Jain D, Pathak V. Recurrent hyponatremia as presenting manifestation of pituitary macroadenoma. *Acta Medica Bulgarica* 2017; 44(1):46–9; <https://doi.org/10.1515/amb-2017-0008>
2. Miljic D, Doknic M, Stojanovic M, Nikolic-Djurovic M, Petakov M, Popovic V, et al. Impact of etiology, age and gender on onset and severity of hyponatremia in patients with hypopituitarism: retrospective analysis in a

- specialised endocrine unit. *Endocrine* 2017; 58(2):312–9; <https://doi.org/10.1007/s12020-017-1415-1>
3. Vega J, Goecke H, Carrasco A, Jensen D, Avilés C, Brusco F, et al. Hyponatremia associated to pituitary adenomas. Report of three patients. *Rev Med Chil* 2009; 137(12):1607–12; <https://doi.org/10.4067/S0034-98872009001200010>
4. Vicente A, Val FD, Cortés C, Lamas C, Aguirre M, Silva J, et al. Clinical features of pituitary adenomas in elderly patients in Castilla La Mancha (Spain) compared with younger age group; a retrospective multicentre study. *Endocr Abstr.* 2015;37.
5. Djurdjevic SP, Doknic M, Miljic D, Stojanovic M, Petakov M, Popovic V. Pituitary adenoma in the elderly: a 10 years experience. *Endocr Abstr.* 2015;37.
6. Dekkers OM, Pereira AM, Romijn JA. Treatment and follow-up of clinically nonfunctioning pituitary macroadenomas. *J Clin Endocrinol Metab* 2008; 93(10):3717–26; <https://doi.org/10.1210/jc.2008-0643>
7. Ntali G, Wass JA. Epidemiology, clinical presentation and diagnosis of non-functioning pituitary adenomas. *Pituitary* 2018; 21(2):111–8; <https://doi.org/10.1007/s11102-018-0869-3>
8. Lin SH, Hung YH, Lin YF. Severe hyponatremia as the presenting feature of clinically non-functional pituitary adenoma with hypopituitarism. *Clin Nephrol* 2002; 57(1):85–8; <https://doi.org/10.5414/CNP57085>
9. Pereira EA, Plaha P, Chari A, Paranathala M, Haslam N, Rogers A, et al. Transsphenoidal pituitary surgery in the elderly is safe and effective. *Br J Neurosurg* 2014; 28(5):616–21; <https://doi.org/10.3109/02688697.2013.872225>
10. Hong J, Ding X, Lu Y. Clinical analysis of 103 elderly patients with pituitary adenomas: transsphenoidal surgery and follow-up. *J Clin Neurosci* 2008; 15(10):1091–5; <https://doi.org/10.1016/j.jocn.2007.11.003>
11. Iglesias P, Arcano K, Trivi-o V, García-Sancho P, Díez JJ, Cordido F, et al. Non-functioning pituitary adenoma underwent surgery: A multicenter retrospective study over the last four decades (1977–2015). *J Intern Med* 2017; 41:62–7; <https://doi.org/10.1016/j.jejim.2017.03.023>
12. Catalano A, Basile G, Ferro C, Scarcella C, Bellone F, Benvenega S, et al. Hyponatremia as a leading sign of hypopituitarism. *J Clin Transl Endocrinol* 2017; 5:1–3; <https://doi.org/10.1016/j.jecr.2017.05.001>

Summary of the case

Patient (gender, age)	1	Female, 61 years old
Final diagnosis	2	Non-functioning pituitary macroadenoma
Symptoms	3	Vomiting, drowsiness, and fatigue
Medications	4	3% normal saline, intravenous steroids, and hormone replacement
Clinical Procedure	5	Nil
Specialty	6	Medicine, Endocrinology