

Hodgkin Lymphoma presenting as a complex paraneoplastic neurological syndrome in an eventually diagnosed case of Klinefelter Syndrome

Arnab Ghosh^{1*}, Manish Bhartiya², Salil Gupta³,
Shashindran VK⁴, Puneet Saxena⁵

ABSTRACT

Background: Klinefelter-syndrome (KS) is recognized as 47, XXY or XYY, two or more X chromosome in males giving rise to a set of clinical signs and symptoms. These individuals are predisposed to certain malignancies. The association of Hodgkin-lymphoma (HL) with KS is very rare and reported only in a single case in literature. Moreover, it is extremely rare to have Chronic-Demyelinating-Inflammatory-Polyneuropathy (CIDP) as initial presentation of HL. The association of CIDP in HL in a case of Klinefelter-syndrome has never reported together.

Case Presentation: We report a case of 47-year old Indian male who presented with CIDP and was eventually diagnosed with Nodular sclerosis variant of HL. Karyotyping revealed KS. Institution of treatment of HL improved his neurological symptoms. However, administration of androgens was deferred till the completion of chemotherapy. Unfortunately, he could not tolerate Chemotherapy and died of Renal Failure during the fourth cycle.

Conclusion: This case report depicts an extremely rare combination of CIDP, HL with KS. It also signifies that all CIDP cases should be evaluated for occult malignancy and if malignancy is found patient should undergo karyotyping for under-diagnosed chromosomal abnormalities such as KS as in this case.

Keywords: Case report, Hodgkin Lymphoma, CIDP, Klinefelter syndrome, para-neoplastic syndrome.

Received: 27 July 2019

Accepted: 10 December 2019

Type of Article: CASE REPORT

Specialty: Oncology

Funding: None

Correspondence to: Arnab Ghosh

*Assistant Professor, Armed Forces Medical College, Pune, India.

Email: afmc.arnab@gmail.com

Full list of author information is available at the end of the article.

Declaration of conflicting interests: None

Background

Klinefelter-syndrome (KS) is seen in men with an extra X chromosome. Reported first time in 1942 and with an incidence being 1:600, it is the most common chromosomal anomalies in man [1,2]. Literature mentions about the correlation of various malignancies, such as lymphoma, leukemia, male breast cancer, prostate cancer, extragonadal germ-cell tumor, and lung cancer with KS. There is increased mortality reported in patients of Non-Hodgkin-Lymphoma with Klinefelter syndrome [3]. However, Hodgkin-Lymphoma (HL) was reported with KS in only a single case report [4]. Moreover, HL presenting as a complex paraneoplastic syndrome at the initial course of disease without any other symptoms or signs is even rarer. This case report highlights two interrelated rare things, one is the rare occurrence of HL in KS and the other is Chronic-Demyelinating-Inflammatory-Polyneuropathy (CIDP) as initial presentation of HL. The combination of three entities (CIDP-HL-KS) in a single patient has never been reported in literature.

Case Presentation

Our patient, a 47-year old Indian male, a crane driver in Middle East country, presented to local doctor near his workplace in Dubai with constitutional symptoms,

generalized weakness, dyspnea [modified Medical Research council (MMRC) Grade-III] & significant weight loss of 1 month duration. Initial evaluation revealed ascites, pleural effusion with polymerase chain reaction positive for non-tubercular mycobacteria. He was started on anti-tubercular treatment. After 3 months, he developed insidious onset flaccid quadriparesis and pan-sensory loss in all four limbs. After 1 month, he returned to India and presented to us with worsening of his weakness and dyspnea. A thorough, meticulous interview with the patient and his family members revealed that he had primary infertility, history of surgical excision of gynecomastia in 2006 and a positive family history of primary infertility and gynecomastia in his younger brother. He was obese with a “heavy and flabby” built (BMI: 29.045 kg/m²). On examination, he was found to have impaired secondary sexual characters, atrophied testes, bilateral pitting pedal edema, ascites, two palpable non-tender 2 × 2cm² lymph nodes in the left axilla, quadriparesis, bilateral pan-sensory loss without any definite sensory levels, and sensory ataxia. All reflexes except ankle jerks were absent. His appearance and clinical features created a strong suspicion of gonadal dysfunction like Klinefelter syndrome.

Investigations

Hormonal assay showed low testosterone and high follicle-stimulating hormone (FSH) & Luteinizing hormone (LH). Thyroid function was normal. The relevant investigations pertaining to his primary complaints ruled out disseminated tuberculosis, multiple myeloma, and connective tissue disorders. Nerve conduction study and cerebrospinal fluid analysis corroborated with the diagnosis of CIDP. Contrast enhanced computed topography chest and abdomen (Figure 1) revealed multiple mediastinal, axillary, and retroperitoneal lymph nodes. Fine needle aspiration and cytology from left axillary lymph node were done. It showed cluster of granulomatous cells and atypical cells, immunohistochemistry of which revealed Reid Sternberg cells (Figure 2) which were positive for CD15, CD30, and CD 20. Karyotyping of peripheral smear revealed 47, XXY (Figure 3).

Final Diagnosis

Hodgkin lymphoma nodular sclerosis type stage iii/bs.
CIDP as paraneoplastic syndrome.
Klinefelter syndrome.

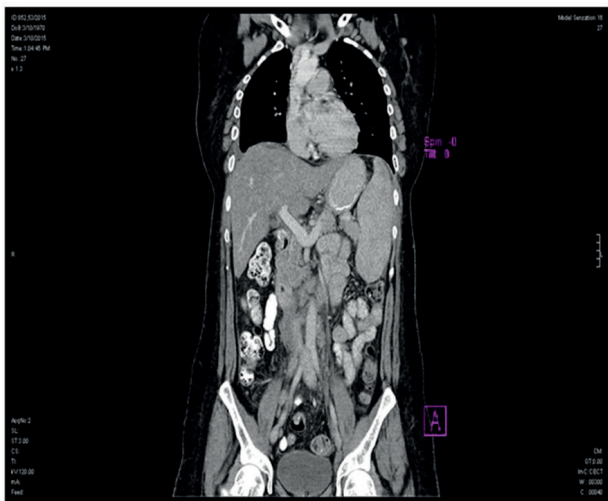


Figure 1. CECT abdomen showing multiple retroperitoneal and mesenteric lymph nodes.

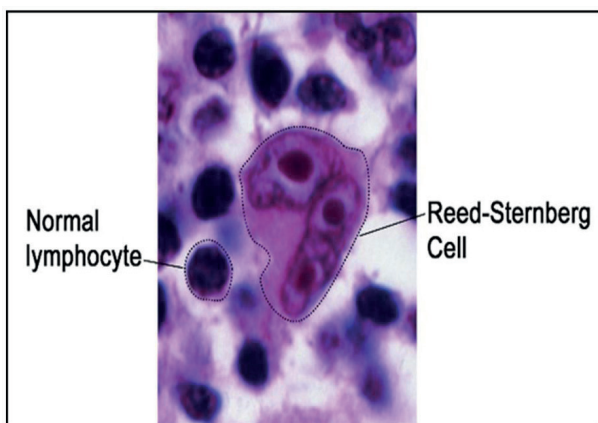


Figure 2. Lymph-node excision biopsy showing Reed-Sternberg Cells.

Management

Patient was diagnosed to have CIDP possibly as a paraneoplastic syndrome to Hodgkin Lymphoma (Nodular sclerosis) associated with Klinefelter syndrome. He was started on chemotherapy (Adriamycin, Bleomycin, Vinblastine, and Dacarbazine) for Hodgkin lymphoma and given methyl Prednisolone pulse. However, Testosterone therapy was deferred till completion of chemotherapy. His neurologic symptoms drastically improved. Unfortunately, after receiving fourth cycle of chemotherapy he presented to Emergency Department with acute renal failure and volume overload state. Despite all efforts he could not be salvaged.

Discussion

Klinefelter syndrome, though a rare disorder, is reportedly diagnosed late in life or underdiagnosed possibly due to mild phenotypes. As in our case, it was picked up so late in life. A meticulous history and examination are thus key factors for clinical suspicion of KS. The association of KS with lymphoma is rare and less reported in literature due to its low diagnosis rate. Hardly, 10 odd cases have been reported so far mentioning the association of mainly non-Hodgkin lymphoma with KS [4]. Only one case of HL associated with KS was reported so far [4]. As a consensus lymphoproliferative malignancy are considered coincidental occurrence with KS. Recent studies attribute this to genetic instability, a characteristic feature of the malignant cells. It is classified into numerical aberrations (chromosomal instability), structural aberrations (translocation instability), distinct gains and losses of chromosomal regions and DNA mutations (micro satellite instability) [5] all of which can be associated with aneuploidy which is a vital mechanism of inactivating tumor suppressor genes. Chromosomal instability is closely associated with aneuploidy which can attribute to abnormal mitotic segregation in malignant cells [6]. In a study of genetic instability in Hodgkin lymphoma, using

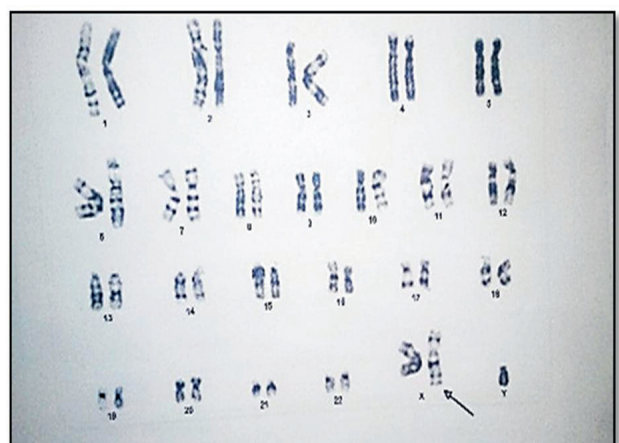


Figure 3. Karyotype showing XXY.

the classical cytogenetic approach, mostly chromosome 12 & X were detected to have gain (hyperdiploidy) in every other Hodgkin's lymphoma cell [5]. The suspicion of chromosomal abnormality with such malignancy and reporting of such cases will lead to the enhancement of limited database on incidence of such association. This case is unique for its primary presentation of CIDP as a paraneoplastic syndrome in Hodgkin lymphoma. The most common neurological syndrome, described in the literature, associated with Hodgkin lymphoma is sub-acute cortical cerebellar degeneration [7,8] and demyelinating neuropathies are very rare [9,10]. Paraneoplastic neuropathies are associated with 4% to 5% of all malignancies [7]. The pathogenesis of paraneoplastic demyelinating neuropathies is thought to have autoimmune mechanisms. Therefore, there was a dramatic response to chemotherapy and methyl Prednisolone pulse.

Conclusion

This case report adds to the limited data base on association of Hodgkin lymphoma with KS. It also signifies that all CIDP cases should be evaluated for occult malignancy and if malignancy is found patient should undergo karyotyping for under-diagnosed chromosomal abnormalities such as KS as in this case.

List of Abbreviations

CIDP	Chronic Inflammatory Demyelinating Polyneuropathy,
HL	Hodgkin Lymphoma,
KS	Klinefelter Syndrome.

Consent for publication

Informed consent was obtained from the next kin of the patient.

Ethical approval

Ethical approval is not required for publishing case reports in our institution.

Author details

Arnab Ghosh, Manish Bhartiya, Salil Gupta, Shashindran VK, Puneet Saxena

1. Assistant Professor, Armed Forces Medical College, Pune, India
2. Senior Resident (DM), Neurology, All India Institute of Medical Sciences, New Delhi, India

3. Professor & HoD (Medicine & Neurology), Army Hospital (R&R), New Delhi, India
4. Former Professor & HoD (Medicine), Armed Forces Medical College, Pune, India
5. Associate Professor, Respiratory & Critical Care Medicine CH (WC), Chandimandir, India

References

1. Klinefelter Jr HF, Reifenstein Jr EC, Albright JR F. Syndrome characterized by gynecomastia, aspermatogenesis without A-Leydigism, and increased excretion of follicle-stimulating hormone 1. *J Clin Endocrinol Metab.* 1942;2(11):615–27. <https://doi.org/10.1210/jcem-2-11-615>
2. Jacobs PA. A case of human intersexuality having a possible XXY sexdetermining mechanism. *Nature.* 1959;183:302–3. <https://doi.org/10.1038/183302a0>
3. Swerdlow AJ, Schoemaker MJ, Higgins CD, Wright AF, Jacobs PA. Cancer incidence and mortality in men with Klinefelter syndrome: a cohort study. *J Natl Cancer Inst.* 2005;97(16):1204–10. <https://doi.org/10.1093/jnci/dji240>
4. de Cytogénétique Hématologique GF. Cytogenetic findings in leukemic cells of 56 patients with constitutional chromosome abnormalities: a cooperative study. *Cancer Genet Cytogenet.* 1988;35(2):243–52. [https://doi.org/10.1016/0165-4608\(88\)90247-6](https://doi.org/10.1016/0165-4608(88)90247-6)
5. Re D, Zander T, Diehl V, Wolf J. Genetic instability in Hodgkin's lymphoma. *Ann Oncol.* 2002;13 Suppl 1:19–22. <https://doi.org/10.1093/annonc/13.S1.19>
6. Rajagopalan H, Lengauer C. Aneuploidy and cancer. *Nature.* 2004;432(7015):338–41. <https://doi.org/10.1038/nature03099>
7. Maslovsky I, Volchek L, Blumental R, Ducach A, Lugassy G. Persistent paraneoplastic neurologic syndrome after successful therapy of Hodgkin's disease. *Eur J Haematol.* 2001;66(1):63–5. <https://doi.org/10.1034/j.1600-0609.2001.00240.x>
8. Brazis PW, Biller J, Fine M, Palacios E, Pagano RJ. Cerebellar degeneration with Hodgkin's disease: computed tomographic correlation and literature review. *Arch Neurol.* 1981;38(4):253–6. <https://doi.org/10.1001/archneur.1981.00510040079015>
9. Mallecourt C, Delattre J. [Paraneoplastic neuropathies]. *Presse Med.* 2000;29(8):447–52.
10. Julien J, Vital C, Aupy G, Lagueny A, Darriet D, Brechenmacher C. Guillain-Barré syndrome and Hodgkin's disease: Ultrastructural study of a peripheral nerve. *J Neurol Sci.* 1980;45(1):23–7. [https://doi.org/10.1016/S0022-510X\(80\)80003-7](https://doi.org/10.1016/S0022-510X(80)80003-7)

Summary of the case

1	Patient (gender, age)	Male, 47 years old
2	Final diagnosis	Hodgkin lymphoma nodular sclerosis type stage III/Bs. CIDP as paraneoplastic syndrome. Klinefelter syndrome.
3	Symptoms	Flaccid Quadripareisis with Pan-sensory loss, Fatigability, Weight-loss, primary infertility and impaired secondary sexual characters
4	Medications	Chemotherapy (AVBD) for Hodgkin lymphoma, Methyl Prednisolone for CIDP & Androgen for Klinefelter syndrome
5	Clinical procedure	Chemotherapy given 4 cycles → demise of the patient, Methyl prednisolone given IV 02 pulses 2 months apart and androgen could not be given because patient could not finish all 06 cycles of the chemotherapy protocol.
6	Specialty	Oncology, Endocrinology and Neurology