

# Inguinal lymph node metastasis as the only manifestation of recurrent ovarian cancer: a case report

Queena Sheryl Dsouza<sup>1\*</sup>, Kadri Yogesh Bangera<sup>2</sup>

European Journal of  
Medical Case Reports

Volume 4(1):01–03

© EJMCR. <https://www.ejmcr.com/>  
Reprints and permissions:  
<https://www.discoverpublish.com/>  
[https://doi.org/10.24911/ejmcr/  
173-1536740674](https://doi.org/10.24911/ejmcr/173-1536740674)

## ABSTRACT

**Background:** Ovarian cancer has emerged as one of the most common malignancies affecting women in India. Despite optimal surgery and appropriate first-line chemotherapy, almost 70%–80% of patients with epithelial ovarian cancer will develop recurrence. Inguinal lymph node metastasis is a rare site of involvement in recurrent epithelial ovarian cancer.

**Case Presentation:** Herein, we report the case of a 54-year-old female who presented to us with painless left inguinal lymphadenopathy. She gave history of being diagnosed with malignant ovarian cancer 2 years ago, for which she underwent debulking surgery. She received only one cycle of chemotherapy after which she defaulted. Cytological examination of the inguinal nodes revealed metastatic ovarian cancer. CA-125 levels were elevated despite the lack of any foci of metabolically active tissue on imaging.

**Conclusion:** Inguinal lymphadenopathy is a rare presentation of recurrent ovarian cancer. Despite that, it is essential to examine the inguinal region in the follow up of all the cases of ovarian cancer. It is also necessary to consider ovarian cancer in the differential diagnosis for inguinal lymphadenopathy in a female patient.

**Keywords:** Case report, ovarian carcinoma, recurrence, inguinal lymphadenopathy.

Received: 22 November 2018

Accepted: 04 November 2018

Type of Article: CASE REPORT

Specialty: Gynecological Oncology

Funding: None

**Declaration of conflicting interests:** The authors declare that there is no conflict of interest regarding the publication of this article.

**Correspondence to:** Queena Sheryl Dsouza

\*M.S Obstetrics and Gynaecology, Senior Resident, Department of Obstetrics and Gynaecology, Kanachur Institute of Medical Sciences, Mangalore, India.

**Email:** queena20049@hotmail.com

Full list of author information is available at the end of the article.

## Background

Gynecologic cancers represent a major burden to the health system in India. Among them, ovarian cancer is a major cause for concern because of nonspecific symptoms and scarcity of a cost effective screening test. The result is that most of the females with ovarian cancer are diagnosed with advanced disease.

According to most of the population-based cancer registries in India, ovarian cancer is the third most common cancer among women, trailing behind cervix and breast cancer. The age adjusted incidence rates of ovarian cancer vary between 2.3 and 15.2 per 100,000 population in different parts of the country [1]. Despite optimal surgery and appropriate first-line chemotherapy, almost 70%–80% of patients with epithelial ovarian cancer will develop recurrence [2]. The pelvic, abdominal, and retroperitoneal cavities represent the most common sites of recurrence, but inguinal lymph node involvement is rarely reported [3].

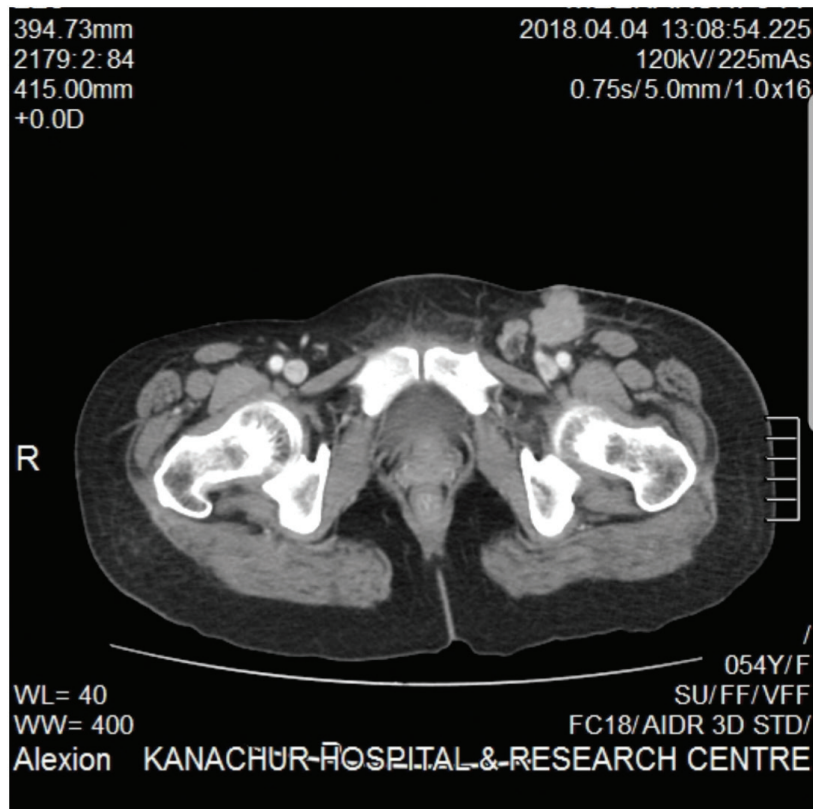
## Case Presentation

A 54-year-old multiparous patient, presented to us with a mass in the left inguinal region. The patient noticed the mass 1 year ago and it gradually increased to the present size. The patient further added that the mass did not disappear on lying down and was not painful. She gave history of undergoing a total abdominal hysterectomy with

bilateral salpingo-oophorectomy and infracolic omentectomy for a malignant ovarian tumor stage 2, 2 years ago in the district Government hospital. Following this surgery, the histopathological report revealed serous papillary adenocarcinoma of right ovary. She was advised six cycles of Platinum-based chemotherapy, but only received one cycle of chemotherapy after which she defaulted.

The patient was thoroughly examined. She was well oriented to time, place, and person. Her body mass index was 18.76 kg/m<sup>2</sup>. Her vitals were stable. No abnormality was detected on the examination of cardiovascular system, respiratory system, and central nervous system. Abdominal examination revealed a healthy midline vertical scar. In the left inguinal region, an irregular mass of approximately 3 × 2 cm was seen. On palpation, the mass was firm in consistency and immobile. The surface was irregular. There was no tenderness and the skin over the mass was intact. No mass was palpable in the right inguinal region. On per speculum and per vaginal examination, the vault appeared intact. No abnormality was detected on per rectal examination.

Computed tomography (CT) of the abdomen revealed a 4 × 4 × 2.8 cm nodular soft tissue focus at the left inguinal region with moderate enhancement (Figure 1). CT also showed a 1 × 1 × 1.2 cm nodular focus adjacent to the left distal iliac vessels. Cancer antigen 125 (CA125) was elevated



**Figure 1.** CT scan image showing the enlarged left inguinal lymph nodes.

(65.91 U/ml). Fine needle aspiration cytology of the inguinal mass was done. Cytological examination showed features suggestive of metastatic adenocarcinoma, thus confirming a diagnosis of metastatic recurrent ovarian carcinoma.

After an extensive discussion, we decided to do a left inguinal and pelvic lymphadenectomy followed by adjuvant Platinum-based chemotherapy. Patient recovered well from the surgery. She received six cycles of chemotherapy and is currently in remission.

### Discussion

Lymphatic spread is reported in about 14%–70% of patients with ovarian carcinoma and is mainly distributed in the pelvic and aortic region [4]. Inguinal lymph node involvement is a rare sign. Due to its rarity very few case reports have been published in the English literature.

Emerson et al. [5] reported a case series of six patients with isolated inguinal lymph node recurrences of ovarian cancer which were diagnosed up to 4 years after the primary diagnosis. Mirrakhimov et al. [3] reported the case of a 48-year-old Caucasian female who underwent successful surgical and chemotherapy treatment for ovarian epithelial cancer. Two years later, the patient was found to have painless left inguinal adenopathy, which was subsequently found to be metastatic ovarian cancer. Santillan et al. [6] reported five cases of inguinal lymph node recurrence of ovarian cancer over a period of 16 months after the primary diagnosis. All the five cases had received a complete course of Platinum based chemotherapy after a primary surgery.

In contrast to the above cases, our patient did not receive a successful primary treatment for ovarian cancer as she defaulted after the first cycle of chemotherapy. As a result, she was certainly more prone for a recurrence.

### Conclusion

Optimal debulking surgery and a complete course of chemotherapy can reduce recurrences in ovarian cancer. Despite that, all the patients who are successfully treated for ovarian cancer should be followed up regularly. Examination of the inguinal region is essential during these follow-up sessions. It is also necessary to consider ovarian cancer in the differential diagnosis for inguinal lymphadenopathy in a female patient.

### List of Abbreviations

CT Computed Tomography

### Consent for publication

Informed consent was obtained from the participant.

### Ethical approval

Ethical approval is not required at our institution to publish an anonymous case report.

### Author details

Queena Sheryl Dsouza<sup>1</sup>, Kadri Yogesh Bangera<sup>2</sup>

1. M.S Obstetrics and Gynaecology, Senior Resident, Department of Obstetrics and Gynaecology, Kanachur Institute of Medical Sciences, Mangalore, India

2. Head of the Department of Obstetrics and Gynaecology, Kanachur Institute of Medical Sciences, Mangalore, India

**References**

1. Three year report of population based cancer registries: 2012–2014. NCDIR-NCRP; 2016.
2. Pignata S, Cecere SC, Du Bois A, Harter P, Heitz F. Treatment of recurrent ovarian cancer. *Ann Oncol.* 2017;28(8):51–6. <https://doi.org/10.1093/annonc/mdx441>
3. Mirrakhimov AE, Nwankwo N, Barbaryan A, Saba R, Ali AM, Kwatra SG, et al. Left inguinal adenopathy two years after cytoreductive surgery: a rare sign of recurrence. *Case Rep Oncol.* 2013;6(1):31–5. <https://doi.org/10.1159/000346615>
4. Metwally IH, Zuhdy M, Hassan A, Alghandour R, Megahe N. Ovarian cancer with metastatic inguinal lymphadenopathy: a case series and literature review. *J Egypt Natl Cancer Inst.* 2017;29(2):109–14. <https://doi.org/10.1016/j.jnci.2017.01.003>
5. Emerson J, Rojas K, Lokich E, Granai C, Robison K. Isolated inguinal node recurrences of ovarian cancer: a case series study. *Gynecol Oncol.* 2015;139(3):584. <https://doi.org/10.1016/j.ygyno.2015.09.022>
6. Santillan A, Karam AK, Li AJ, Giuntoli R, Gardner GJ, Cass I, et al. Secondary cytoreductive surgery for isolated nodal recurrence in patients with epithelial ovarian cancer. *Gynecol Oncol.* 2007;104(3):686–90. Epub 2006 Dec 1. <https://doi.org/10.1016/j.ygyno.2006.10.020>

**Summary of the case**

1	<b>Patient (gender, age)</b>	Female, 54 years
2	<b>Final diagnosis</b>	Metastatic recurrent ovarian adenocarcinoma
3	<b>Symptoms</b>	Mass in the left inguinal region
4	<b>Medications</b>	6 cycles of platinum based adjuvant chemotherapy
5	<b>Clinical procedure</b>	Left inguinal and pelvic lymphadenectomy
6	<b>Specialty</b>	Gynecological oncology