

Adrenal myelolipoma case presentation, approach, and management

Mohsen Ali Ezzy^{1*}, Stefan Schopf², Thomas Kraus³, Peter Heinz³

European Journal of
Medical Case Reports

Volume 4(2):79–83

© EJMCR. <https://www.ejmcr.com/>

Reprints and permissions:

<https://www.discoverpublish.com/>

<https://doi.org/10.24911/ejmcr/>

173-1577510395

ABSTRACT

Background: Adrenal myelolipomas are a type of benign tumors of hematopoietic nature that is non-functional and considered as a mature adipose tissue.

Case Presentation: In this study, two cases of symptomatic myelolipoma were presented. One suffered from nausea and vomiting combined with pain and feeling of postprandial pressure causing weight loss with a minimum body mass index below 18 kg/m². While, symptoms of postprandial pressure with pain in the right upper abdomen was present in another case. Both patients were selected for surgery. An open conventional surgery via abdominal access for the giant myelolipoma with a maximum diameter of 14 cm and minimal-invasive surgery for the 8 cm myelolipoma in a cachectic patient with 45 kg body weight was indicated. Patients recovered from their symptoms quickly.

Conclusion: Surgery was indicated for symptomatic myelolipomas. The resection could be performed minimal-invasive up to 10 cm in specialized centers and via open surgery in every other case.

Keywords: Adrenal myelolipomas, adrenal incidentalomas, giant myelolipomas, conventional surgery, minimal-invasive surgery, case report.

Received: 28 December 2019

Accepted: 29 February 2020

Correspondence to: Mohsen Ali Ezzy

Krankenhaus Nordwest, Frankfurt, Germany.

Email: dr.ezzy@hotmail.com

Full list of author information is available at the end of the article.

Type of Article: CASE REPORT

Specialty: Oncology

Funding: None

Declaration of conflicting interests: The authors declare that there is no conflict of interests regarding the publication of this case report.

Background

Adrenal myelolipoma is characterized by a certain type of lesion, benign tumor (2%–4% of adrenal type) [1] and considered the major type of adrenal incidentalomas [2]. These types of tumor sometimes known as asymptomatic, unilateral, or bilateral that might cause symptoms [3]. A stimulus (necrosis, stress or infection, and inflammation) was found to increase the prevalence of adrenocortical metaplasia that considered the most type of theories [4]. Adrenal myelolipoma has a very tiny diameter size (< 5 mm). Performing surgery for cases was rare, while the rate of detection increased recently due to the use of imaging modalities [5]. Adrenal myelolipoma also named incidentaloma when the cases were detected as asymptomatic incidental imaging findings [6]. It commonly seen in a population of age that ranged between 40 and 60 years and similarly distributed between males and females [5]. This study reported two patients with incidentally detected myelolipoma and was selected for surgery according to their clinical symptoms. Both patients recovered quickly without postoperative complications.

Case Presentation

A 58-year-old male was presented with discomfort in the right upper abdomen and a palpable mass in physical examination caused by a giant adrenal myelolipoma. Abdominal ultrasound showed a large hyperechoic mass in

the right upper quadrant measuring 14 cm. Routine hematological parameters were normal. Serum catecholamine, cortisol, and urinary, vanillylmandelic acid were within a normal range. Contrast-enhanced computed tomography (CT) scan of the abdomen revealed a well-defined, large, round lesion in the right adrenal region measuring about 14 cm with heterogeneous attenuation suggested the possibility of myelolipoma. The diagnosis of symptomatic myelolipoma was made and the patient was scheduled for trans-abdominal right adrenalectomy through the right subcostal incision and his postoperative course was uneventful. The histopathological evaluation of the mass revealed a characteristic mixture of mature adipose tissue with a hematopoietic element without malignancy, confirmed the initial diagnosis of adrenal myelolipoma.

Another case of a 43-year-old female with a known sickle cell anemia presented with weight loss and chronic abdominal pain in the right upper abdomen without a history of fever. Physical examination revealed a cachectic patient (body mass index was 18) with known splenomegaly and a palpable mass in the right upper abdomen. The abdominal ultrasound examination showed splenomegaly as well as a hyperechoic mass in the right upper quadrant measuring 8 cm in diameter. Routine laboratory parameters were normal except for an elevated iron-level secondary to previous multiple transfusion. Serum

catecholamine, cortisol, plasma-metanephrine, and urinary vanillylmandelic acid levels were within a normal range. The patient was scheduled for endoscopic right adrenalectomy through a minimally invasive retroperitoneal approach. The postoperative course was uneventful. The histopathological evaluation of the mass revealed a characteristic mixture of mature adipose tissue with a hematopoietic element without malignancy, confirmed the initial diagnosis of adrenal myelolipoma.

CT appearance of myelolipoma showed the heterogeneous mass covering upper right retroperitoneal space with variable central and peripheral attenuation. Homogenous, sharply circumscribed, the hyperechoic tumor was adjacent to the right kidney (Figure 1).

Magnetic resonance imaging (MRI) appearance of myelolipoma showed a large hyperintense right adrenal mass with central hypointense areas as well as signal drop suggested fat content in the mass (Figure 2A–C).

Gross appearance of an Adrenal myelolipoma showed a large capsulated mass with adipose tissue and hemorrhagic areas within it (Figure 3A–C).

Both symptomatic and hormone active myelolipomas were indicated for surgery (Figure 4).

Furthermore, management approaches for adrenal incidentalomas were also reviewed (Figure 5).

Discussion

Adrenal myelolipomas are a type of benign tumors of hematopoietic that are non-functional and considered as a mature adipose tissue. It is usually small, mono-lateral, and asymptomatic tumor; it represents almost 1.9% of adrenal incidentalomas [7]. They are also called “incidentalomas” since their diagnosis is based on autopsy or imaging modalities which are performed for reasons usually unrelated to adrenal diseases. The incidence ranges from 0.08% to 0.4%, and less than 300 cases were reported in

the literature before 2000 [8]. However, their prevalence appears to be increased by up to 10%, due to the increased use of noninvasive and enhanced imaging techniques [9].

In this case report, both patients suffered from symptoms caused by the mass effect of their myelolipomas. The patients were scheduled for conventional trans-abdominal and minimal-invasive retroperitoneal surgery according to their tumor size. Conventional approaches, including midline, subcostal, lumbar, or posterior access laparotomy, had been described in the literature. An extra-peritoneal approach was preferable as it led to quicker recovery of the patient and lesser postoperative complications [10]. After excision, adrenal myelolipoma generally does not recur, with recurrence-free survival rates of up to 12 years being reported. There was no evidence of malignant transformation in the literature. German guidelines recommended 6 cm diameter as a limit to minimally invasive surgery [11]. In the institutions with expertise in adrenal surgery, benign tumors below 10 cm diameter could be resected minimally invasive by retroperitoneal access, first described by Liu et al. [12]. In minimally invasive adrenal surgery, malignancy has to be excluded preoperatively, because retrieved specimen had to be morcellated intracorporeally. A variety of differential diagnosis of adrenal masses has to be noted, important was to rule out malignancy before the surgical intervention.

In the present study, after excluding adrenal metastases and adrenocortical carcinoma by its low proportion of fatty tissue on CT, there was still retroperitoneal liposarcoma and renal angiomyolipoma to be considered. Retroperitoneal liposarcoma is a slow-growing ill-defined tumor of the retroperitoneal region which is composed of adipocytes and radiologically appears similar to an adrenal myelolipoma with an invasion of the adjacent structure. Renal angiomyolipomas are tumors arising from the kidney, they consist of fat, blood vessels, and

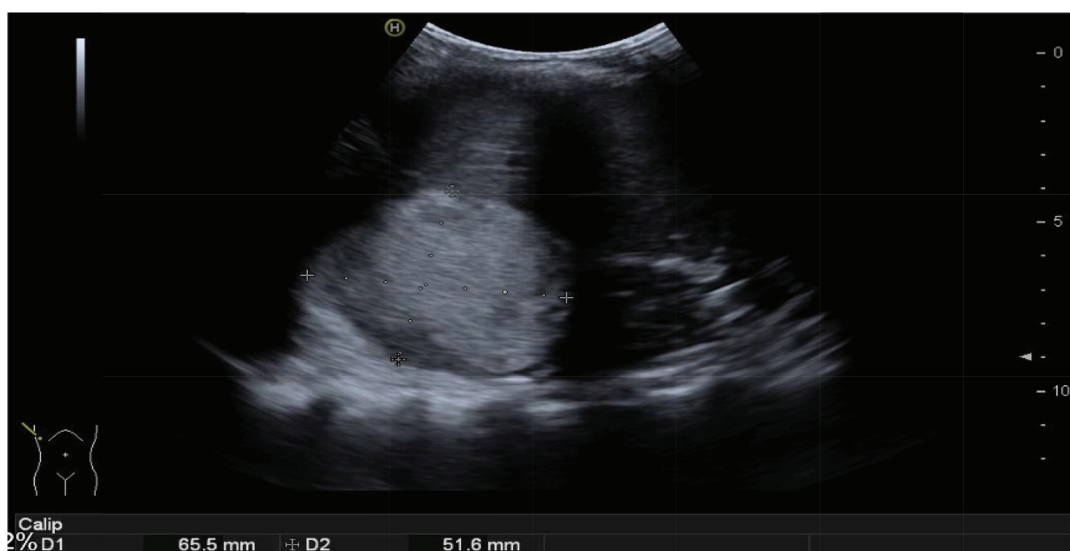


Figure 1. CT appearance of myelolipomas.

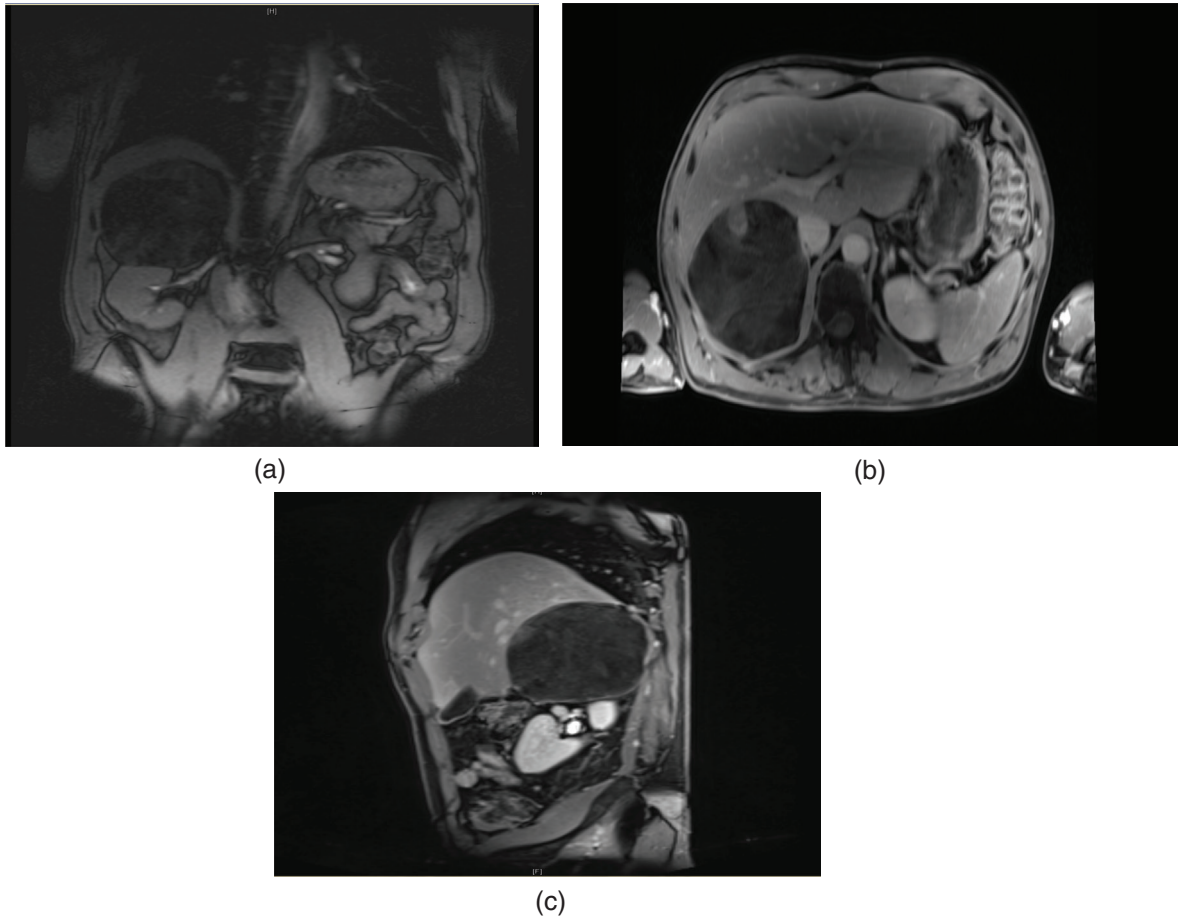


Figure 2. (A) MRI appearance of myelolipoma. (B) MRI appearance of myelolipoma. (C) MRI appearance of myelolipoma.

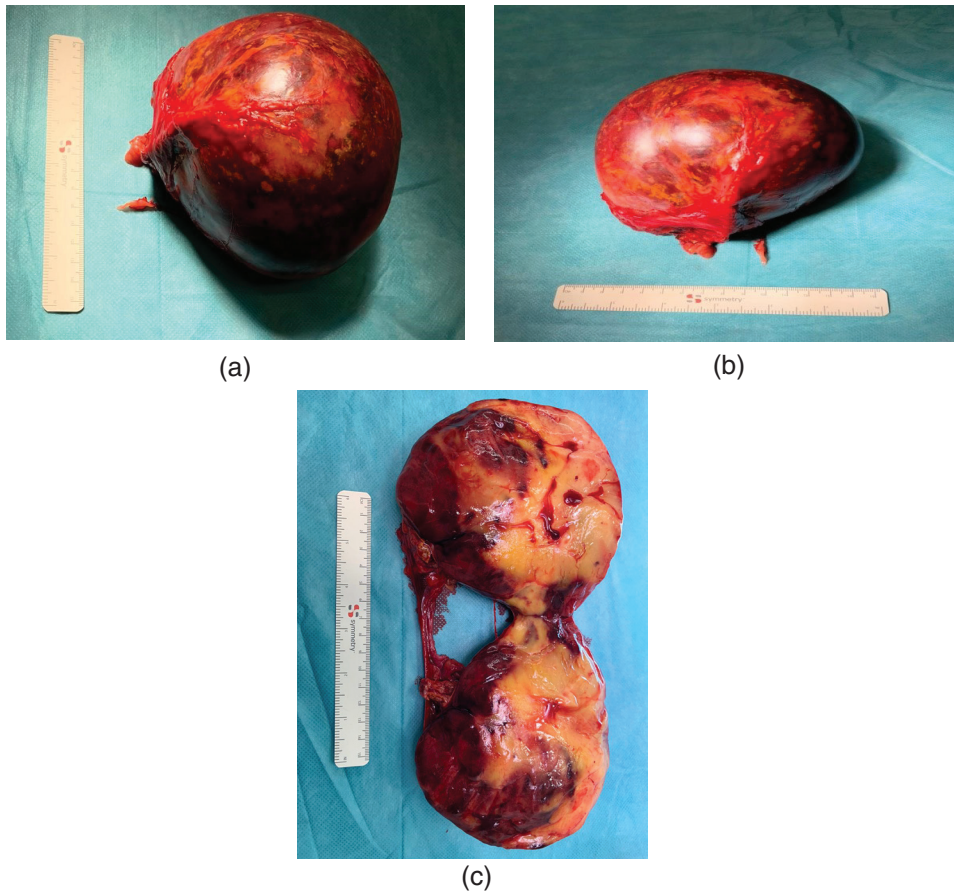


Figure 3. (A) Gross appearance of an adrenal myelolipomas. (B) Gross appearance of an adrenal myelolipomas. (C) Gross appearance of an adrenal myelolipomas.

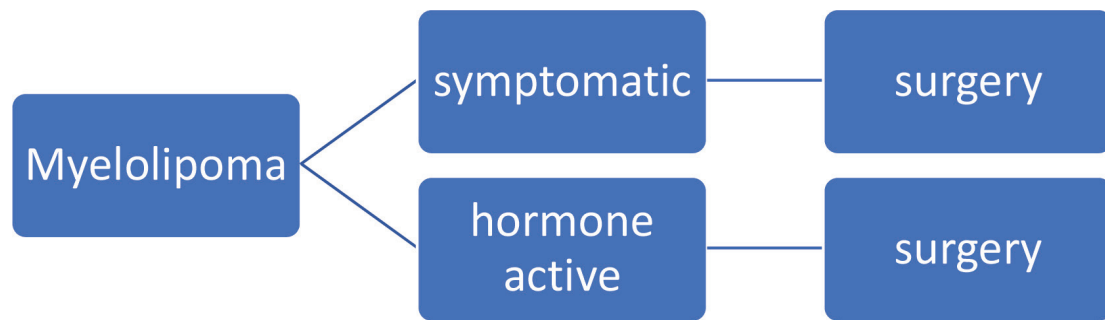


Figure 4. Indication of surgery for myelolipoma.

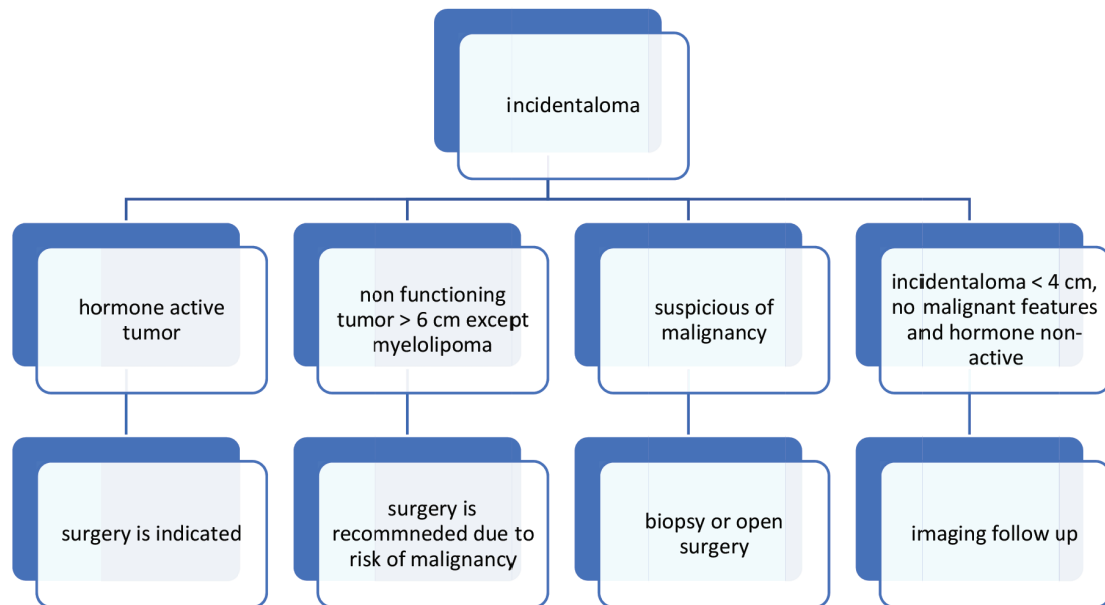


Figure 5. Review of management approach of adrenal incidentalomas.

muscle cells. These are large, heterogeneous appearing tumors that could invade through the renal capsule. Image-guided biopsy for diagnostic confirmation was useful and safe. However, care must be taken to avoid the risk of malignant, seeding, rupture, and bleeding. Twenty two cases had been reported in the literature [13] with bleeding complication, especially intratumoral hemorrhage. Characteristics included sudden onset of pain, male dominance, right-sided predilection, and mean tumor size of 11.7 cm (range 4–20.5).

Therefore, it could be said that the management approach should be individualized based on the presence of symptoms and the size of the lesion. Asymptomatic tumors could be usually followed. The surgery is indicated by symptomatic tumors, the presence of signs of a hormone-secreting tumor, or giant myelolipomas due to the risk of intra-tumoral bleeding and rupture. Thus, it was concluded that Adrenal myelolipomas consist of mature fatty tissue combined with hematopoietic tissue, such as myeloid and erythroid cells. Referring to incidentalomas, they are often serendipitously discovered by radiological examination. The presence of macroscopic fat on imaging is characteristic of an adrenal myelolipoma. Surgery is

indicated for symptomatic myelolipomas. Asymptomatic tumors could be usually followed, the presence of signs of a hormone-secreting tumor or giant myelolipomas due to risk of intra-tumoral bleeding and rupture. Resection could be performed minimal-invasive up to 10 cm in specialized centers and via open surgery in every other case.

What is new?

Adrenal myelolipomas are a type of benign tumor that is often serendipitously discovered by radiological examination. 2. Asymptomatic tumors could be usually followed, the presence of signs of a hormone-secreting tumor or giant myelolipomas due to risk of intra-tumoral bleeding and rupture 3. Surgery was indicated for symptomatic myelolipomas. Resection could be performed minimal-invasive up to 10 cm in specialized centers and via open surgery in every other case.

List of Abbreviations

CT Computed tomography
MRI Magnetic resonance imaging

Consent of publication

Informed consent was obtained from all participants.

Ethical approval

Ethical approval was obtained from Institutional research and ethics board.

Author details

Mohsen Ali Ezzy¹, Stefan Schopf², Thomas Kraus³, Peter Heinz³

1. Krankenhaus Nordwest, Frankfurt, Germany
2. Krankenhaus Agatharied/Bad Aibling Krankenhaus, Frankfurt Germany
3. Krankenhaus Nordwest, Frankfurt, Germany

References

1. Anis-Ul-Islam M, Qureshi AH, Zaidi SZ. Adrenal myelolipoma in a young male - a rare case scenerio. *J Pak Med Assoc.* 2016;66:342–4.
2. Ersoy E, Ozdoğan M, Demirağ A, Aktimur R, Kulaçoğlu H, Kulaçoğlu S, et al. Giant adrenal myelolipoma associated with small bowel leiomyosarcoma: a case report. *Turk J Gastroenterol.* 2006;17:126–9.
3. Brogna A, Scalisi G, Ferrara R, Bucceri AM. Giant secreting adrenal myelolipoma in a man: a case report. *J Med Case Rep.* 2011;5:e298. <https://doi.org/10.1186/1752-1947-5-298>
4. Meyer A, Behrend M. Presentation and therapy of myelolipoma. *Int J Urol.* 2005;12:239–43.
5. Gershuni VM, Bittner JG, Moley JF, Brunt LM. Adrenal myelolipoma: operative indications and outcomes. *J Laparoendosc Adv Surg Techniq.* 2014;24:8–12. <https://doi.org/10.1089/lap.2013.0411>
6. Hakim A, Rozeik C. Adrenal and extra-adrenal myelolipomas—a comparative case report. *J Radiol Case Rep.* 2014;8:1–12. <https://doi.org/10.3941/jrcr.v8i1.1551>
7. Jung SI, Kim SO, Kang TW, Kwon DD, Park K, Ryu SB. Bilateral adrenal myelolipoma associated with hyperaldosteronism: report of a case and review of the literature. *Urology.* 2007;70:1223.e11–3. <https://doi.org/10.1016/j.urology.2007.09.046>
8. Porcaro AB, Novella G, Ficarra V, Cavalleri S, Antonioli SZ, Curti P. Incidentally discovered adrenal myelolipoma. Report on 3 operated patients and update of the literature. *Arch Italian Urol Androl.* 2002;74:146–51.
9. Vierna J, Laforga JB. Giant adrenal myelolipoma. Report of a case and review of the literature. *Scand J Urol Nephrol.* 1994;28:301–4. <https://doi.org/10.3109/00365599409181284>
10. Tyritzis SI, Adamakis I, Migdalis V, Vlachodimitropoulos D, Constantinides CA. Giant adrenal myelolipoma, a rare urological issue with increasing incidence: a case report. *Cases J.* 2009;2:e8863. <https://doi.org/10.4076/1757-1626-2-8863>
11. Haro A, Fujishita T, Nishikawa H, Taguchi Y, Kouda T, Kajiwara K, et al. A rare case of gradual enlargement of a multifocal myelolipoma of the posterior mediastinum for 12 years after surgical resection of an adrenal myelolipoma. *Int J Surg Case Rep.* 2018;51:400–3. <https://doi.org/10.1016/j.ijscr.2018.09.027>
12. Liu W, Chen W, He X. An unusual cause of Cushing's Syndrome and virilization. *Gastroenterology.* 2015;149:e5–6. <https://doi.org/10.1053/j.gastro.2015.02.020>
13. Littrell LA, Carter JM, Broski SM, Wenger DE. Extra-adrenal myelolipoma and extramedullary hematopoiesis: imaging features of two similar benign fat-containing presacral masses that may mimic liposarcoma. *Eur J Radiol.* 2017;93:185–94.

Summary of the case

1	Patient	58-year-old male, 43-years-old female
2	Final Diagnosis	adrenal myelolipoma
3	Symptoms	pain in the right upper abdomen
4	Medications	None
5	Clinical Procedure	Abdominal ultrasound, Contrast-enhanced computed tomography (CT) scan of the abdomen and Magnetic Resonance Imaging
6	Specialty	Oncology