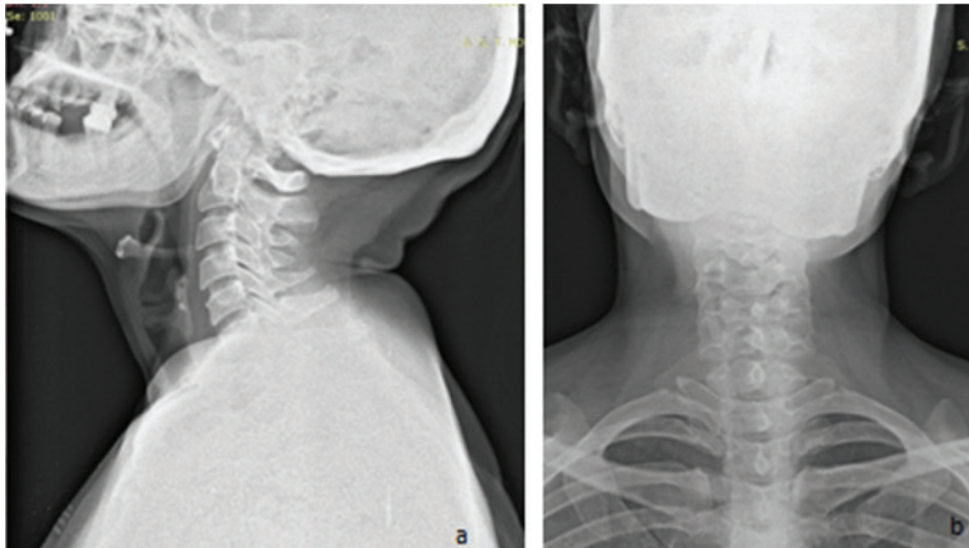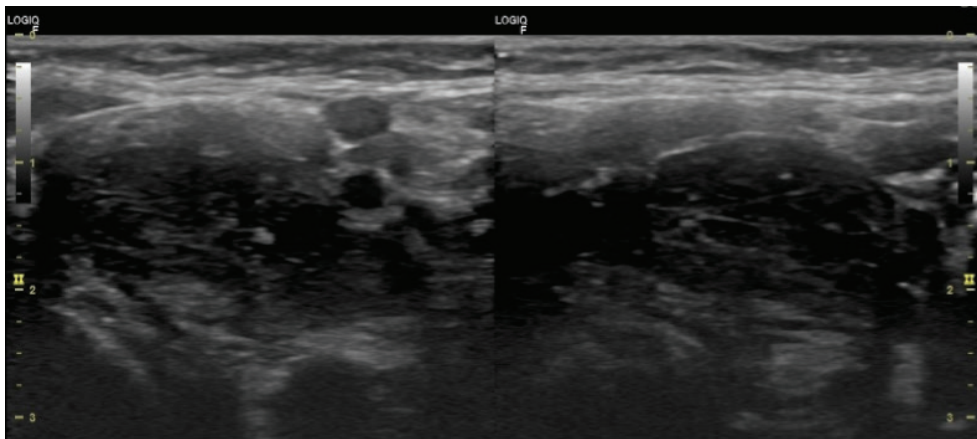


**Figure 2.** Plain radiograph of the neck region (a) lateral projection and (b) anteroposterior view. No abnormality was detected.



**Figure 3.** USG evaluation of carotid body tumor seen in gray scale in the long axis and short axis. The mass is more elongated rather than short axis. Tumor is well defined and slightly hypoechoic. No calcification or necrotic areas were seen.

mass was splaying the external carotid artery (ECA) and internal carotid artery (ICA). The mass had internal vascularity. No calcification was seen (Figure 4).

Contrast-enhanced computerized tomography (CECT) evaluation revealed a well-defined avid by enhancing mass at the bifurcation. This mass was lying on the medial side of the bifurcation. Some branches of the ECA were seen feeding this mass. The mass was covering around 250° of the circumference of ICA. This was categorized as type II as per Shamblin classification (Figures 5a and b and 6a and b).

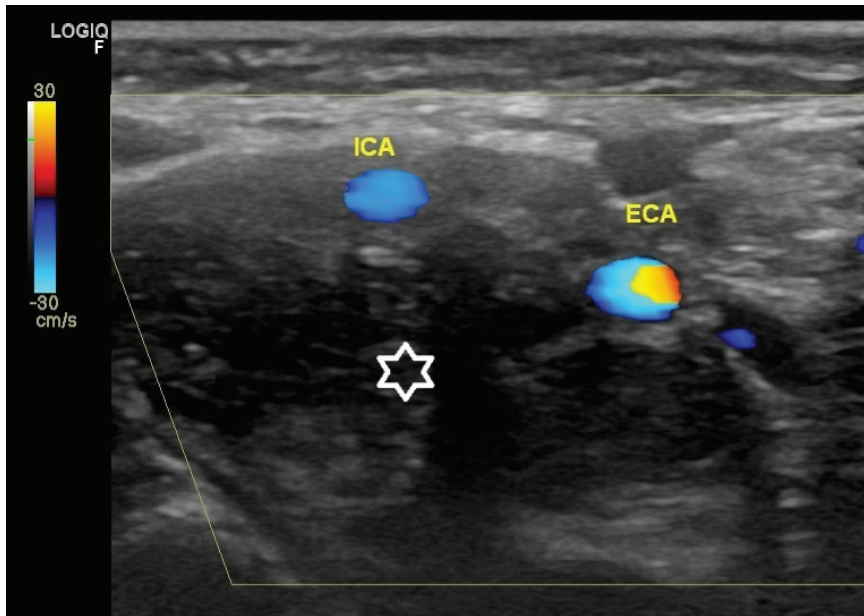
Magnetic Resonance Imaging evaluation was done subsequently using the standard protocol along with magnetic resonance angiography (MRA). This revealed a classical “salt pepper” appearance of the mass in T1W. This is because of slow flow punctate foci (salt) and flow void dots (pepper). The mass was slightly hyperintense on T2W as compared to muscles, and there was no restriction in Diffusion Weighted Imaging. MRA shows “lyre sign” as splaying of the ICA and

ECA. This can also be seen in source axial images (Figure 7a and b).

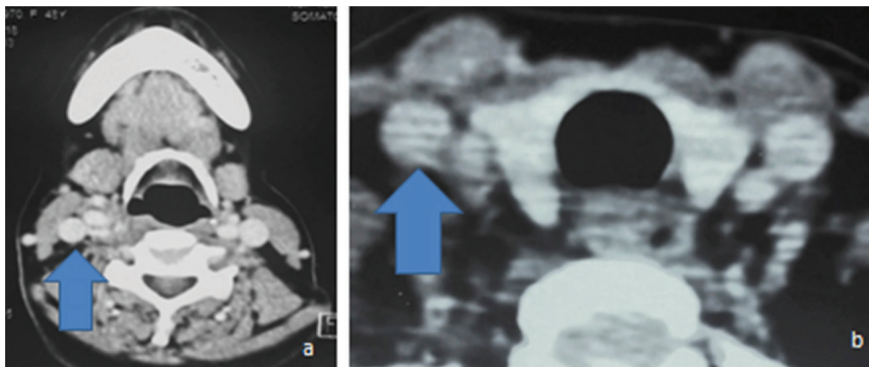
After ruling out other differentials such as schwannoma, neurofibroma, lymph node mass, or glomus vagale tumor pathologies, the working diagnosis was made as carotid body tumor of Shamblin type II. The diagnosis was straightforward on the basis of clinical and radiological evaluation. Now, the patient was advised a planned surgical management and kept under 6-month follow-up.

### Discussion

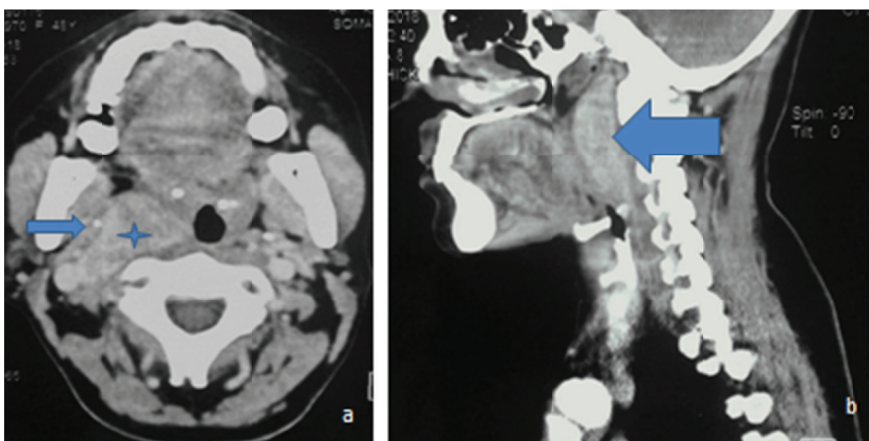
CBTs are paragangliomas of the carotid bodies occurring at the bifurcation of common carotid into ECA and ICA. These are also called as chemodectomas [2–4]. These cervical paragangliomas arise in close relation to the extracranial arterial system and cranial nerves. These tumors arise in adventitia which lies in the carotid sheath. The origin is from neural crest, so these are responsible for the adaptation of carbon dioxide, pH, and oxygen in the body [5,6].



**Figure 4.** CFI of CBT. The hypoechoic mass (white star) is splaying the ICA and ECA. The velocity of ECA can be recognized by the color spectrum.



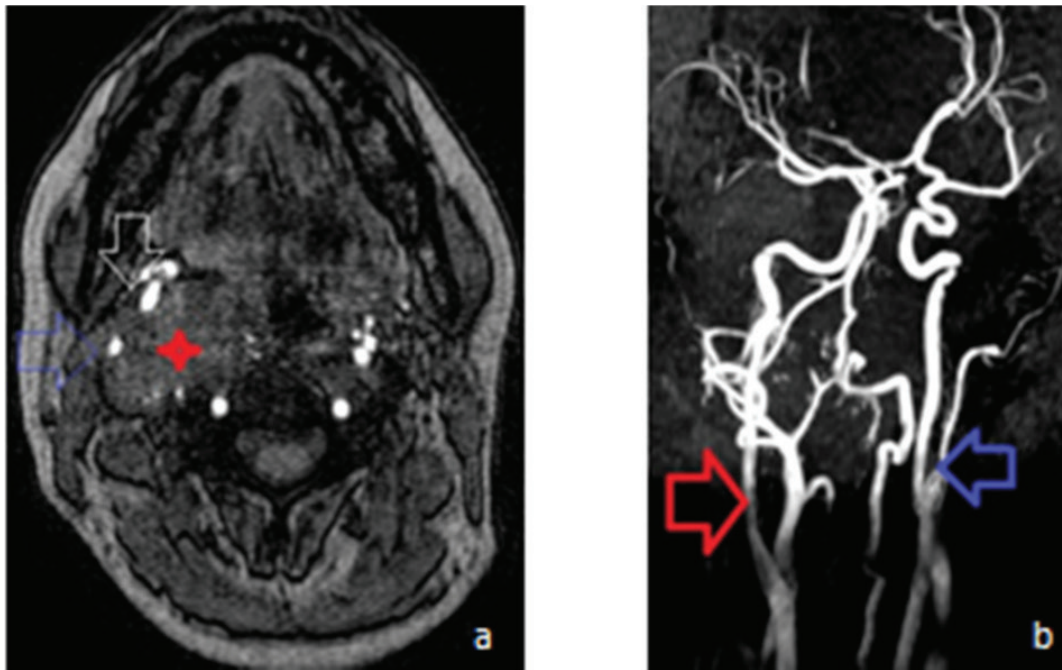
**Figure 5.** CECT axial section at various levels. (a) Right common carotid artery is seen normal at hyoid bone level (upward arrow). (b) Right CCA is normal at thyroid level (upward arrow).



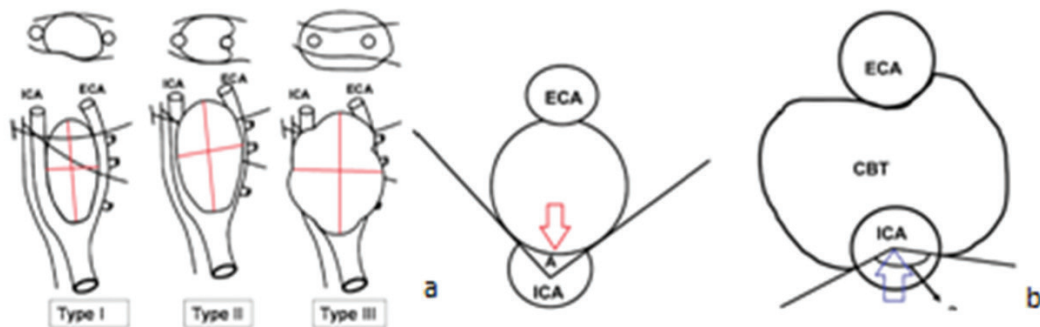
**Figure 6.** CECT neck region. (a) Axial section shows the avid-enhancing CBT (blue star) displacing the right ICA (blue horizontal arrow). (b) Reconstructed sagittal format showing the enhancing mass growing in superoinferior direction (blue horizontal arrow).

These tumors are bilateral in about 5% of the cases. The mechanism is by releasing neurotransmitters which increase the ventilation after their stimulation. These tumors splay

both the ECA and ICA. They are benign and asymptomatic in nature. They represent 65% of the cervical region paragangliomas. They can be either familial, sporadic, or



**Figure 7.** Magnetic resonance imaging evaluation. (a) Source axial section shows the CBT mass on the right side (red arrow) displacing ICA (blue hollow faint arrow) and ECA (inverted white hollow arrow). (b) MRA shows the splaying of ICA and ECA at the bifurcation of right CCA as “lyre sign” (red arrow) and the normal CCA bifurcation on the left side (blue arrow).



**Figure 8.** Diagrammatic representation of CBT as per Shamblin classification. (a) Mass splaying of ICA and ECA (red cross lines) as seen in angiography as per various types. (b) As seen in cross-sectional CECT images as per circumference. Type I is up to  $180^\circ$  (inverted red arrow) and Types II and III are between  $180^\circ$  onward (upward blue arrow).

hyperplastic as per their subsets in origin. The sporadic variety constitutes the majority of tumors to the tune of 85% and is found in the age group of 40–70 years. The malignant variety in these subsets occurs in 20–40 years age group [7,8]. The hyperplastic variety is found among those where hypoxia is the underlying factor such as high altitude, chronic obstructive pulmonary disease, or congenital heart disease. The surgical management of these types of tumor involves a lot of complications. The main complication is intraoperative bleeding. USG in combination with CFI depicts the reason well about the status of the vascularity and the origin of CBTs. CECT shows the evidence of vascularity in the form of avid enhancement and displacement of the main vessels [8]. The surgical Shamblin classification of CBTs (Figure 8a and b) is good predictor for

the preoperative bleeding and morbidity. This is as per the size and extent of tumor. A preoperative MRA Shamblin classification [9] is as follows:

Type I: circumferential contact  $180^\circ$  or less.

Type II: circumferential contact between  $180^\circ$  and  $270^\circ$ .

Type III: circumferential contact  $> 270^\circ$ .

An imaging evaluation shows a classical hypervascular, hypoechoic tumor mass with splaying of carotid bifurcation. The management warrants the multidisciplinary approach involving interventional radiologist and the surgeon [10]. Shamblin III group definitely requires preoperative embolization [11,12]. This leads to the safe and effective management of these notorious tumors. Conventional digital subtraction angiography shows a typical blush and early

filling of vein because of arteriovenous shunting. The main nerves involved during the surgical intervention are vagus, hypoglossal, sympathetic chain, or marginal mandibular branch of the facial nerve. The literature accounts for 11%–50% of such injuries [13–15]. Preoperative embolization can prevent 75% of the blood loss, and this is usually done in ascending pharyngeal branch of the ECA [16]. Radiological evaluation always leads to the maximum safety of such surgical interventions and can be the best predictor for the complications [17].

## Conclusion

The management of CBTs is a very controversial issue as the procedure is not free of complications. Intraoperative bleeding during the surgery is the most challenging issue. As these are benign tumors, the decision of surgical management should be as per the weight age of the advantages. Preoperative embolization is the most effective step to avoid blood loss during the surgery.

### What is new?

CBTs are uncommon tumors but every case has got some criteria for the management. Surgical management requires complete imaging evaluation and this is very important for the operating surgeon.

## Acknowledgment

The authors are extremely thankful to Mr. Arshad lecturer, Miss. Komal tutor, and Prashant tutor from the Faculty of Allied Health Sciences for helping us in diagnostic support. The authors are also thankful to Mr. Prahlad Singh, Mr. Kasif, and Mr. Anil Kumar radiographers of SGT Hospital for carrying out general radiography and CT.

## Consent for Publication

A written consent of the patient was taken.

## Ethical Approval

Ethical approval is not required at our institution to publish an anonymous case report.

## Author details

Shweta Sharma<sup>1</sup>, Bharat Bhushan Sharma<sup>2</sup>, Neeru Kapur<sup>3</sup>, Pawan Joon<sup>3</sup>, Mir Rizwan Aziz<sup>4</sup>, Dileep Kumar Jha<sup>4</sup>, Nitish Virmani<sup>5</sup>, Sadaf Zaffar<sup>6</sup>

1. ENT Specialist Registrar, Warwick Hospital, Warwick, UK
2. Professor & HOD, Department of Radio-Diagnosis, SGT Medical College, Gurugram, India
3. Assistant Professor, Department of Radio-Diagnosis, SGT Medical College, Gurugram, India
4. Senior Resident, Department of Radio-Diagnosis, SGT Medical College, Gurugram, India
5. Assistant Professor, Faculty of Allied Health Sciences, SGT University, Gurugram, India
6. BRIT (Student), Faculty of Allied Health Sciences, SGT University, Gurugram, India

6. BRIT (Student), Faculty of Allied Health Sciences, SGT University, Gurugram, India

## References

1. Shamblin WR, ReMine WH, Sheps SG, Harrison EG Jr. Carotid body tumor (chemodectoma). Clinicopathologic analysis of ninety case. *Am J Surg.* 1971;122(6):732–9. [https://doi.org/10.1016/0002-9610\(71\)90436-3](https://doi.org/10.1016/0002-9610(71)90436-3)
2. Day TA, Joe JK. Primary neoplasms of the neck. Cummings: otolaryngology: head & neck surgery. 4th edition, Elsevier-Mosby, St Louis, MI, p 113, 2005.
3. Isik AC, Imamoglu M, Erem C, Sari A. Paragangliomas of the head and neck. *Med Princ Pract.* 2007;16(3):209–14. <https://doi.org/10.1159/000100392>
4. Georgiadis GS, Lazarides MK, Tsalkidis A, Argyropoulou P, Giatromanolaki A. Carotid body tumor in a 13-year-old child: case report and review of the literature. *J Vasc Surg.* 2008;47(4):874–80. <https://doi.org/10.1016/j.jvs.2007.10.040>
5. Ghoreishi M, Akbar-Beigi A, Tahery D, Sehhat S. Fever as the main presenting symptom of a carotid body tumor. *Arch Iran Med.* 2008;11(2):214–7.
6. Baysal BE, Myers EN. Etiopathogenesis and clinical presentation of carotid body tumors. *Microsc Res Tech.* 2002;59(3):256–61. <https://doi.org/10.1002/jemt.10200>
7. Naughton J, Morley E, Chan D, Fong Y, Bosanquet D, Lewis M. Carotid body tumours. *Br J Hosp Med (Lond).* 2011;72(10):559–64. <https://doi.org/10.12968/hmed.2011.72.10.559>
8. Straughan DM, Neychev VK, Sadowski SM, Ellis RJ, Thomas F, Patronas NJ, et al. Preoperative imaging features are associated with surgical complications following carotid body tumor resection. *World J Surg.* 2015;39(8):2084–9. <https://doi.org/10.1007/s00268-015-3058-9>
9. Arya S, Rao V, Juvekar S, Dcruz AK. Carotid body tumors: objective criteria to predict the Shamblin group on MR imaging. *AJNR Am J Neuroradiol.* 2008;29(7):1349–54. <https://doi.org/10.3174/ajnr.A1092>
10. Lim JY, Kim J, Kim SH, Lee S, Lim YC, Kim JW, et al. Surgical treatment of carotid body paragangliomas: outcomes and complications according to the shamblin classification. *Clin Exp Otorhinolaryngol.* 2010;3(2):91–5. <https://doi.org/10.3342/ceo.2010.3.2.91>
11. Sajid MS, Harmilton G, Baker DM. A multicenter review of carotid body tumor management. *Eur J Vasc Endovasc Surg.* 2007;34:127–30. <https://doi.org/10.1016/j.ejvs.2007.01.015>
12. Sahin MA, Jahollari A, Guler A, Doganci S, Bingoi H, Karaman B, et al. Results of combined preoperative direct percutaneous embolization and surgical excision in treatment of carotid body tumors. *Vas.* 2011;40(6):461–6. <https://doi.org/10.1024/0301-1526/a000149>
13. Li-Shan L, Chang-Wei L, Heng G, Yue-Hong Z, Xing-Ming C, Yong-Jun L. Efficacy of surgical therapy for carotid body tumors. *Clin Med Sci J.* 2011;26(4):241–5. [https://doi.org/10.1016/S1001-9294\(12\)60008-X](https://doi.org/10.1016/S1001-9294(12)60008-X)
14. Davila VJ, Chang JM, Stone WM, Fowl RJ, Bower TC, Hinni ML, et al. Current surgical management of carotid body tumors. *J Vasc Surg.* 2016;64(6):1703–10. <https://doi.org/10.1016/j.jvs.2016.05.076>

15. Makeieff M, Raingeard I, Alric P, Bonafe A, Guerrier B, Marty-Ane CH. Surgical management of carotid body tumors. *Ann Surg Oncol*. 2008;15(8):2180–6. <https://doi.org/10.1245/s10434-008-9977-z>
16. Zhang TH, Jiang WL, Li YL, Li B, Yamakawa T. Perioperative approach in the surgical management of carotid body tumors. *Ann Vasc Surg*. 2012;26(6):775–82. <https://doi.org/10.1016/j.avsg.2012.01.020>
17. Kim GY, Lawrence PF, Moridzadeh RS, Zimmerman K, Munoz A, Luna-Ortiz K, et al. New predictors of complications in carotid body tumor resection. *J Vasc Surg*. 2017;65(6):1673–9.

### Summary of the case

1	<b>Patient (gender, age)</b>	Female, 48-year-old
2	<b>Final Diagnosis</b>	Carotid Body Tumor
3	<b>Symptoms</b>	Swelling in the right side of the neck with mild pain
4	<b>Medications</b>	Only symptomatic medication when required
5	<b>Clinical Procedure</b>	Diagnosis made on the clinical and radiological background. Now surgical resection is to be undertaken. The patient had been told regarding the benefit of preoperative embolization as these are very vascular tumors.
6	<b>Specialty</b>	Radiology