

Table 1. Lab results.

TESTS	PATIENTS VALUES	NORMAL VALUES
Hb	7.6 g/dl	9 g/dl
WBC	27,600 × 10 ⁹ /l	3.5–10.0 × 10 ⁹ /l
Neutrophils	74%	52%
Lymphocytes	23%	42%
Monocytes	02%	04%
Eosinophils	01%	02%
Prothrombin time	12 seconds	13 seconds
Activated partial thromboplastin time	30 seconds	33 seconds
Alanine aminotransferase	46 IU/l	7–56 IU/l
Aspartate aminotransferase	48 IU/l	10–40 IU/l
Serum albumin	3 g/dl	3.5–4.5 g/dl
Urea	25	10–25 mg/dl
Creatinine	0.4	0.7–1–4 mg/dl
Serum IgA	0.58 g/l	0.08–0.91 g/l
Serum IgG	8.8 g/l	2.05–9.48 g/l
Serum IgM	0.91 g/l	0.17–1.43 g/l
ELISA for amoebiasis		positive
Echinococcus antibodies		negative
Blood culture		negative

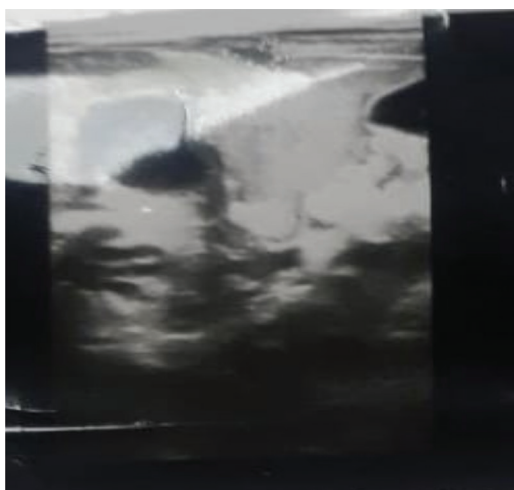


Figure 1. Ultrasound of the abdomen showing heterogeneous ill-defined areas in the right lobe of the liver, suggesting multiple liver abscesses, with the largest one measuring 33.6 × 13.2 × 26 mm, with a volume of 6.1 ml, and the other one measuring 20.9 × 14.7 × 17.5 mm, with a volume of 2.8 ml. The smallest one measured 15.2 × 9.4 × 11.2 mm, with a volume of 0.8 ml.

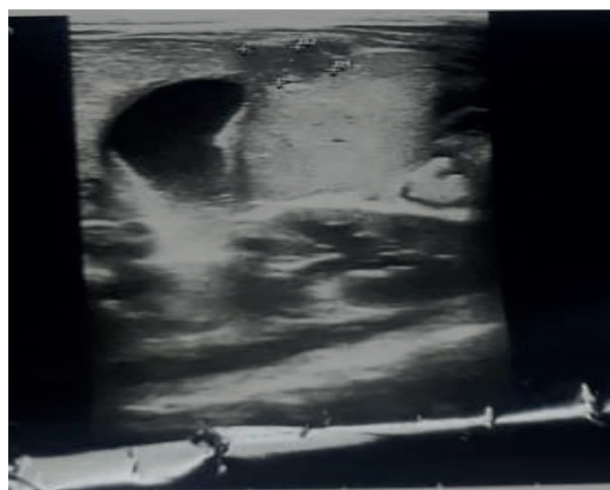


Figure 2. Ultrasound of the abdomen showing heterogeneous ill-defined areas in the right lobe of the liver, suggesting multiple liver abscesses, with the largest one measuring 33.6 × 13.2 × 26 mm, with a volume of 6.1 ml, and the other one measuring 20.9 × 14.7 × 17.5 mm, with a volume of 2.8 ml. The smallest one measured 15.2 × 9.4 × 11.2 mm, with a volume of 0.8 ml.

improvement in the WBC count to normal on the seventh day. The C reactive protein became normal on the tenth day. Follow-up ultrasound was carried out with marked improvement showing the largest lesion of about 2.7 × 4 mm only, while the smallest one was about 2.1 × 1.2 mm. The child was discharged with an oral metronidazole course for 4 weeks and follow-up was given in the clinic. On follow-up, the child was symptom-free, playful, and healthy, having a normal ultrasound.

Discussion

Amoebiasis is caused by *Entamoeba histolytica*, which is endemic in developing countries [1]. The most common intestinal manifestation is colitis, whereas the most common extraintestinal illness is amoebic liver abscess. Liver abscess is prevalent in areas with overcrowding, poor hygiene, and low standards of sanitation. The spread is through the orofecal route. It is further influenced by the nutritional status of the population, making

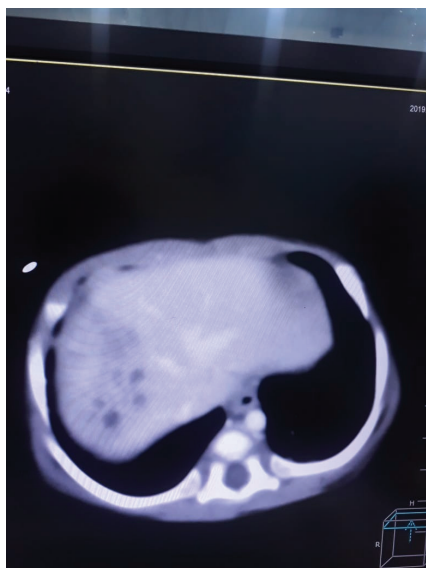


Figure 3. CT of the abdomen showing multiple heterogeneous density areas with internal cystic spaces in the right lobe of the liver.

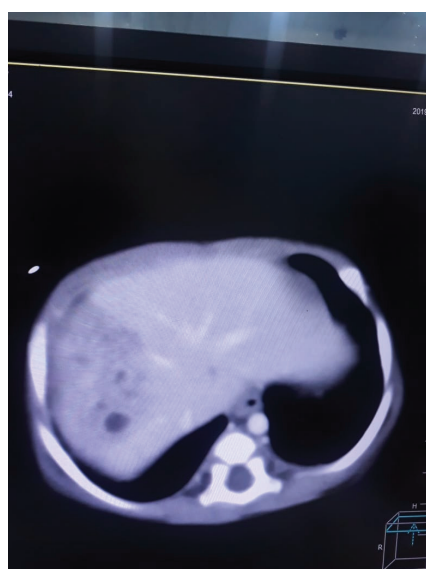


Figure 4. CT of the abdomen showing multiple heterogeneous density areas with internal cystic spaces in the right lobe of the liver.

undernourished people more vulnerable to the disease [7]. In developed countries, it is more common among travelers and immigrants from endemic areas [8].

Amoebic liver abscess presents with fever, abdominal pain, and occasional gastrointestinal symptoms, like diarrhea. There is hepatic tenderness and its presentation is mostly acute [9]. It is diagnosed by identification of cystic lesions in the liver and positive serological tests for amoebiasis [10]. The most common differential is echinococcus cysts and malignant disease of the liver. The standard treatment in uncomplicated amoebic liver abscess is metronidazole along with intraluminal amoebicide, like paromomycin. Drainage is usually not required in the right

lobe abscess, unless it is bigger than 6 cm or in the left lobe of the liver [11].

Amoebic liver abscess is a rare condition and very few cases have been reported in neonates and infants. One case study reported on a 19-day-old baby who was orally given sugar solution and was treated successfully with metronidazole [12]. Another case report showed that a 20-day-old newborn was diagnosed with amoebic liver abscess who presented with a cystic lesion in the right lobe of the liver. The liver abscess was drained, which confirmed the amoebic pathology; however, the baby died due to necrotizing enterocolitis [13]. Another case study showed three neonates with amoebic liver abscess, whose presentation was similar to our case and were diagnosed on serology and microscopic examination of the abscess content. These cases had a history of umbilical catheter infection, prematurity, and necrotizing enterocolitis [14].

In our case, the baby had no history of umbilical catheterization or any other predisposing factors leading to the hematogenous spread of infection. The mother had no antenatal history of any illnesses and there was no maternal and baby contact with a tuberculosis patient. The stool test was negative. There was no evidence of immune deficiency and the child recovered fully after the treatment. The cause of liver abscess seemed to be the contaminated water source. The baby was taking formula feed and normal tap water was being used for preparing the milk without boiling it. The family was living in an overcrowded locality with low standards of personal hygiene and sanitation. At the time of discharge, she was referred to the health educator for proper counseling and advice on hygiene and feeding practices.

Conclusion

Amoebic liver abscess is rare and can have serious consequences in infants. This highlights the fact that we need a high degree of suspicion to diagnose such an illness in infants. It is important to create awareness among people about hygiene and sanitation. Water should be used after boiling or disinfecting.

What is new?

Liver abscess has been reported in children, but amoebic liver abscess is very rare in infants. This is a rare case of amoebic liver abscess in an otherwise healthy baby with no immune deficiency and no history of umbilical catheterization or sepsis after birth.

List of Abbreviations

CT scan Computed tomography
Hb Hemoglobin

Consent for publication

Written informed consent was obtained from the family of the patient's family.

Ethical approval

Ethical approval is not required at our institution for publishing an anonymous case report.

Author details

Nagina Shahzadi¹, Uzma Rubab², Nadeem Hashmat³, Naureen Kanwal Satti⁴

1. Paediatric Gastroenterology Children Hospital Faisalabad, Faisalabad, Pakistan
2. Woman Medical Officer, Department of Peds Gastroenterology Children Hospital, Faisalabad, Pakistan
3. Department of Emergency Medicine, King Saud University, Riyadh, Saudi Arabia
4. Department of Paediatrics, King Saud University, Riyadh, Saudi Arabia

References

1. Ali WM, Ali I, Rizvi SA, Rib AZ, Ahmed M. Recent trends in the epidemiology of liver abscess in western region of Uttar Pradesh: a retrospective study. *J Surf Anesth.* 2018;2(117):2.
2. Broz P, Jacob AL, Fehr J, Kissel CK. An unusual presentation of amoebic liver abscesses. *CMAJ.* 2010;182(16):1755–7. <https://doi.org/10.1503/cmaj.091210>
3. Choudhury SR. Splenic and Liver abscess. In *Pediatric Surgery*. Springer, Singapore, pp 151–6, 2018. https://doi.org/10.1007/978-981-10-6304-6_24
4. Kushwaha Y, Kapil R, Khurana S. A prospective study of one hundred cases of Amoebic liver abscess in a secondary care hospital of Delhi. *Int J Med Public Health.* 2016;6(2):84–7. <https://doi.org/10.5530/ijmedph.2016.2.6>
5. Petridou C, Al-Badri A, Dua A, Dryden M, Saeed K. Learning points from a case of severe amoebic colitis. *Le infezioni in Medicina*, 3, pp 281–4, 2017.

6. Houpt E, Hung CC, Petri W. *Entamoeba histolytica* (amebiasis). *Infectious Disease and Antimicrobial Agents*, Rochester, MN, 2016.
7. Arias F, Bhide AG, Arulkumaran S, Damania K, Daftary SN, editors. *Arias’ practical guide to high-risk pregnancy and delivery: a South Asian perspective*. Chennai, India: Elsevier India; 2019.
8. Gaut D, Shull H, Bejjani A, Kahn D. Hepatic abscess in a returning traveler with crohn's disease: differentiating amoebic from pyogenic liver abscess. *Case Rep Med.* 2018;2018:9593865. <https://doi.org/10.1155/2018/9593865>. PMID: 30002680; PMCID: PMC5996425
9. Prakash V, Oliver TI. Amoebic liver abscess. In *StatPearls [Internet]*. StatPearls Publishing, Treasure Island, FL, 2019.
10. Rubinson HA, Isikoff MB, Hill MC. Diagnostic imaging of hepatic abscesses: a retrospective analysis. *Am J Roentgenol.* 1980;135(4):735–45. <https://doi.org/10.2214/ajr.135.4.735>
11. Saleem A, Qazi SH, Akhtar W, Jilani SM. Amoebic liver abscess: outcomes of percutaneous needle aspiration vs drain placement in paediatric population. *J Pak Med Assoc.* 2019;69(Suppl. 1): S29.
12. Güven A. Amebiasis in the newborn. *Indian J Pediatr.* 2003;70(5):437–8. <https://doi.org/10.1007/BF02723620>
13. Gomez NA, Cozzarelli R, Alvarez LR, Fabre E, Roldos FE. Amoebic liver abscess in newborn. Report of a case. *Acta Gastroenterol Latinoam.* 1999;29(3):115–8.
14. Nazir Z, Qazi SH. Amoebic liver abscesses among neonates can mimic bacterial sepsis. *Pediatr Infect Dis J.* 2005;24(5):464–6. <https://doi.org/10.1097/01.inf.0000160956.12570.3a>

Summary of the case

1	Patient (gender, age)	Male, 45 days
2	Final diagnosis	Amoebic liver abscess in a 45-days-old baby
3	Symptoms	Fever and vomiting
4	Medications	IV fluids, antipyretics, antibiotics
5	Clinical procedure	None
6	Specialty	Pediatrics gastroenterology