


Using point of care ultrasound in diagnosing pneumoperitoneum: a case report in a pediatric patient

Maram Althagafi¹, Najeeb Alqarni¹, Bsaim Altirkistani^{2*} 

European Journal of Medical Case Reports

Volume 8(9):209–212

DOI: 10.24911/ejmcr.173-1724966675



This is an open access article distributed in accordance with the Creative Commons Attribution (CC BY 4.0) license: <https://creativecommons.org/licenses/by/4.0/> which permits any use, Share — copy and redistribute the material in any medium or format, Adapt — remix, transform, and build upon the material for any purpose, as long as the authors and the original source are properly cited. © The Author(s) 2024

ABSTRACT

Background: Gastrointestinal perforation with subsequent pneumoperitoneum is a life-threatening surgical emergency, has a high risk of morbidity and mortality, and requires prompt diagnosis and treatment.

Case Presentation: A 4-year-old boy known case of lymphocele, tethered spinal cord syndrome, neurogenic bladder, and vesicoureteral reflux grade 3 was brought to the emergency department with a history of on and off periumbilical abdominal pain for 15 days, centralized in position, without radiation to other sites of the abdomen, the pain became progressively severe in nature and intensity in the last 3 days. Point of care ultrasound was performed while waiting for the abdomen X-ray. The right upper quadrant of the abdomen was assessed using the curvilinear probe in the longitudinal view, which showed sonographic evidence of pneumoperitoneum, and enhanced peritoneal stripe signs associated with posterior reverberation artifacts.

Conclusion: Understanding the fundamentals of abdominal ultrasound examination will give emergency physicians another diagnostic tool to identify life-threatening cases of acute pneumoperitoneum promptly.

Keywords: Point of care, ultrasound, diagnosis, pneumoperitoneum, and pediatrics.

Received: 29 August 2024

Accepted: 12 September 2024

Type of Article: CASE REPORT

Specialty: Radiology

Correspondence to: Bsaim Altirkistani

*College of Medicine, King Saud Bin Abdulaziz University for Health Sciences, Jeddah, Saudi Arabia.

Email: bsaim.altirkistani064@gmail.com

Full list of author information is available at the end of the article.

Background

Gastrointestinal perforation with resultant pneumoperitoneum is a life-threatening surgical emergency associated with a high morbidity and mortality rate that necessitates immediate diagnosis and intervention [1,2]. Rapid identification of pneumoperitoneum is critically important and can be lifesaving. Upright chest radiographs or abdominal computed tomography are common methods to detect intraperitoneal free air. However, obtaining these examinations at an appropriate time in the emergency room can occasionally be challenging. Ultrasound is an imaging tool that can be performed at the bedside to diagnose acute abdomen issues quickly. It is more widely available in the emergency department (ED) and can rapidly recognize intraperitoneal free air [3,4]. There is limited data to support the use of point-of-care ultrasound (POCUS) in diagnosing pneumoperitoneum in the ED [3-5]. In this case report, we emphasize the role of POCUS for early identification of gastrointestinal perforation.

Case Presentation

A 4-year-old boy, with a known case of lymphocele and tethered spinal cord syndrome that was diagnosed at birth;

and neurogenic bladder and grade 3 vesicoureteral reflux, diagnosed at the age of 3 years. Now the patient was brought to the ED with a history of on-and-off periumbilical abdominal pain, for 15 days, centralized in position, without radiation to other sites of the abdomen, the pain became progressively severe in nature and intensity in the last 3 days; however, the patient could not determine its character. The pain was aggravated by food intake and not relieved by any other factors. It was associated with decreased oral intake, one episode of non-projectile, non-bilious vomiting 2 days back, and one documented fever reaching 39°C the day of presentation to the ED. The parents denied a history of diarrhea, urinary complaints, trauma, or foreign body ingestion. Upon arrival at the ED, he was febrile (39°C), heart rate of 124 beats/minute, respiration rate of 42 breath/minute, SPO₂ of 96% with a blood pressure of 104/64 mmHg. His blood glucose was 2.8 mg/dl at presentation. On physical examination, he was irritable and crying from pain. The abdomen was distended and diffusely tender with positive rebound tenderness. A peripheral intravenous line was inserted. Laboratory investigations, IV dextrose bolus, intravenous maintenance fluid, and acetaminophen were ordered.

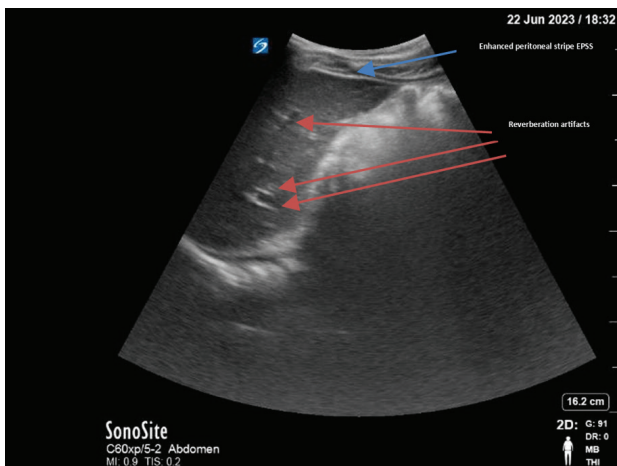


Figure 1. POCUS reveals the presence of free intraperitoneal air, evidenced by the EPSS (blue arrow) and reverberation artifact (red arrow).

POCUS was performed while waiting for the abdomen X-ray. The right upper quadrant of the abdomen was assessed using the curvilinear probe in the longitudinal view, which showed sonographic evidence of pneumoperitoneum, and enhanced peritoneal stripe signs (EPSSs) associated with posterior reverberation artifacts (Figure 1).

Abdomen supine and upright X-rays were then performed and showed dilated bowel loops with multiple metallic foreign bodies projecting over the right lower quadrant (most likely magnet) with free air under the diaphragm (Figure 2). Laboratory investigations were remarkable for leukocytosis: White blood cell count of neutrophils count of 11.60, C-reactive protein of 234, and procalcitonin of 2.02.

The patient was started on broad-spectrum antibiotics, and the pediatric surgery team was consulted urgently. He was immediately taken to the operating room for emergent exploratory laparotomy. The post-operative report showed the presence of thirteen magnets (Figure 3) in the ascending colon and two perforations, one at the cecum and one at the terminal ileum, for which magnets removal with primary closure of ileal and cecal perforation was performed.

Discussion

Ultrasound technique

A focused abdominal ultrasound is performed utilizing a curvilinear abdominal transducer. The patient was positioned supine on the examination table with adequate exposure of the abdomen. This position allows for an initial assessment of the abdominal cavity for signs of free intraperitoneal air. A liberal amount of ultrasound gel was applied, and the examination began with the placement of the transducer in the midline and the right upper quadrant of the abdomen. Following this, the scan is repeated in the left lateral decubitus position. This

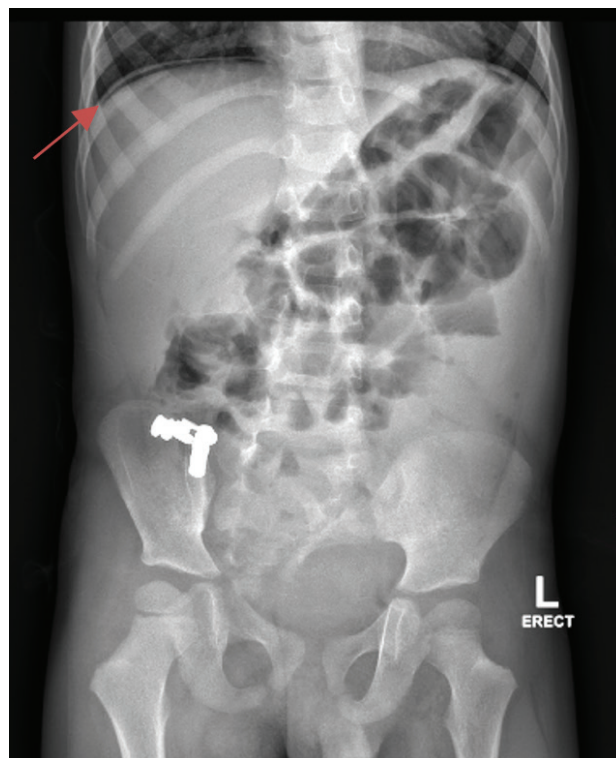


Figure 2. X-ray displaying the presence of free air under the diaphragm, as indicated by the arrow.

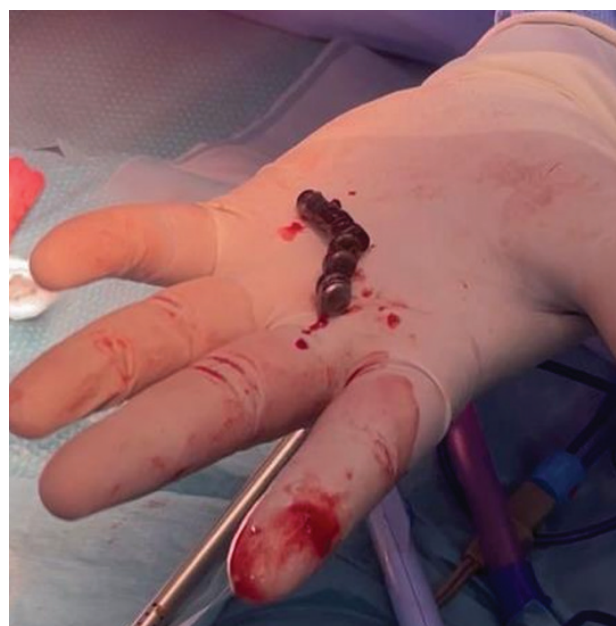

Figure 3. Illustrates the presence of 13 magnets located in the ascending colon.

change in position aids in the detection of subtle signs of pneumoperitoneum by allowing intraperitoneal air to accumulate along dependent areas, enhancing visualization. Dynamic maneuvers, such as altering the patient’s position and instructing deep breathing, were employed to optimize visualization [6-8].

Systematic scanning for the abdomen was conducted, encompassing all four quadrants of the abdomen. Both

longitudinal and transverse views were obtained to evaluate intra-abdominal structures comprehensively.

The pneumoperitoneum presents sonographically with characteristic signs such as the EPSS. Intraperitoneal air thickens the peritoneum, leading to increased echogenicity of the peritoneal stripe. EPSS can be visualized alone or in conjunction with posterior reverberation artifacts, further aiding in the identification of pneumoperitoneum [8].

Gastrointestinal perforation is a surgical emergency that requires prompt diagnosis and surgical intervention. Many factors can cause perforation, including blunt or penetrating abdominal trauma, peptic ulcer disease, foreign body ingestion, and inflammatory conditions such as appendicitis, inflammatory bowel disease, and necrotizing enterocolitis [1,2]. Gastrointestinal perforation can result in pneumoperitoneum, which is defined as a collection of air under the diaphragm that can be detected by plain radiography when the patient is either upright or in a lateral decubitus position. However, the traditional use of plain radiography and computed tomography to detect pneumoperitoneum is occasionally challenging in the setting of an ED for many reasons, including overcrowded ED, patient's ability to stand for erect chest X-rays, and lack of an adequate number of ED staff needed for transporting the patient to the imaging department. Therefore, POCUS would be a more easily accessible and excellent alternative bedside diagnostic tool [6]. There is one study aimed to compare the diagnostic accuracy between POCUS and plain radiography in 132 patients with suspected perforated viscus demonstrated a sensitivity of 93% vs. 79%, specificity of 64% vs. 64%, accuracy of 90% vs. 77%, positive predictive value of 97% vs. 96%, and negative predictive value of 44% vs. 21% [7].

The diagnosis of pneumoperitoneum using ultrasound is made by placing the curvilinear probe over the midline and right upper quadrant of the abdomen. At the same time, a patient is in the supine position. Subsequently, the scan should be repeated in the left lateral decubitus position, looking for signs of pneumoperitoneum. Intraperitoneal air thickens the peritoneum, resulting in EPSS, which can be identified alone or with posterior reverberation artifacts [8].

With this case report, we emphasize the importance of POCUS as an excellent and rapid diagnostic method to evaluate patients with acute abdomen. Therefore, we recommend using it in the ED to differentiate the life-threatening pneumoperitoneum while preventing unnecessary radiation exposure.

Conclusion

Acute abdominal pain is a common diagnostic dilemma that may not always present with clear signs, especially in the pediatric age group. Knowing the basics of utilizing the abdominal ultrasound examination will offer emergency physicians an additional diagnostic modality to

recognize life-threatening cases of acute pneumoperitoneum promptly.

What is new?

Gastrointestinal perforation with subsequent pneumoperitoneum is a life-threatening surgical emergency, has a high risk of morbidity and mortality, and requires prompt diagnosis and treatment. The authors present a case of abdominal pain with pneumoperitoneum to emphasize the role of POCUS for early identification of gastrointestinal perforation. The authors believe that their study makes a significant contribution to the literature because understanding the fundamentals of abdominal ultrasound examination will give emergency physicians another diagnostic tool to identify life-threatening cases of acute pneumoperitoneum quickly.

List of Abbreviations

ED	Emergency department
EPSSs	Enhanced peritoneal stripe signs
IV	Intravenous
POCUS	Point-of-care ultrasound

Conflicts of interest

The authors declare that they have no conflict of interest regarding the publication of this case report.

Funding

None.

Consent for publication

Written informed consent was obtained from the patient's legal guardian for publication of this case report and any accompanying images.

Ethical approval

Ethical approval is not required at our institution to publish an anonymous case report.

Author details

Maram Althagafi¹, Najeeb Alqarni¹, Bsaim Altirkistani²

1. Pediatric Emergency Department, King Abdulaziz Medical City, Jeddah, Saudi Arabia
2. College of Medicine, King Saud Bin Abdulaziz University for Health Sciences, Jeddah, Saudi Arabia

References

1. Emanuel B, Zlotnik P, Raffensperger JG. Perforation of the gastrointestinal tract in infancy and childhood. *Surg Gynecol Obstet*. 1978 Jun;146(6):926–8.
2. Grosfeld JL, Molinari F, Chaet M, Engum SA, West KW, Rescorla FJ, et al. Gastrointestinal perforation and peritonitis in infants and children: experience with 179 cases over ten years. *Surgery*. 1996 Oct;120(4):650–5. [https://doi.org/10.1016/S0039-6060\(96\)80012-2](https://doi.org/10.1016/S0039-6060(96)80012-2)
3. Hoffmann B, Nürnberg D, Westergaard MC. Focus on abnormal air: diagnostic ultrasonography for the acute abdomen. *Eur J Emerg Med*. 2012 Oct;19(5):284–91. <https://doi.org/10.1097/MEJ.0b013e3283543cd3>
4. Coppolino F, Gatta G, Di Grezia G, Reginelli A, Iacobellis F, Vallone G, et al. Gastrointestinal perforation: ultrasonographic diagnosis. *Crit Ultrasound J*. 2013 Jul;5(Suppl 1):S4. <https://doi.org/10.1186/2036-7902-5-S1-S4>

5. Bacci M, Kushwaha R, Cabrera G, Kalivoda EJ. Point-of-care ultrasound diagnosis of pneumoperitoneum in the Emergency Department. *Cureus*. 2020 Jun;12(6):e8503. <https://doi.org/10.7759/cureus.8503>

6. Yum J, Hoffman T, Naraghi L. Timely diagnosis of pneumoperitoneum by point-of-care ultrasound in the Emergency Department: a case series. *Clin Pract Cases Emerg Med*. 2021 Nov;5(4):377–80. <https://doi.org/10.5811/cpcem.2021.4.52139>

7. Chen SC, Wang HP, Chen WJ, Lin FY, Hsu CY, Chang KJ, et al. Selective use of ultrasonography for the detection of pneumoperitoneum. *Acad Emerg Med*. 2002 Jun;9(6):643–5. <https://doi.org/10.1111/j.1553-2712.2002.tb02307.x>

8. Hefny AF, Abu-Zidan FM. Sonographic diagnosis of intraperitoneal free air. *J Emerg Trauma Shock*. 2011 Oct;4(4):511–3. <https://doi.org/10.4103/0974-2700.86649>

Summary of the case

1	Patient (gender, age)	4 years old boy
2	Final diagnosis	Pneumoperitoneum
3	Symptoms	Periumbilical abdominal pain
4	Medications	Antibiotics
5	Clinical procedure	Emergency exploratory laparotomy
6	Specialty	Radiology