

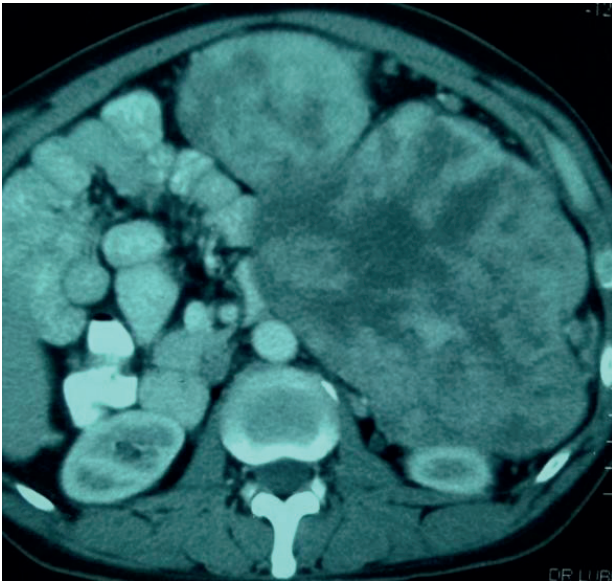Figure 1. Axial section of CT scan showing large tumor.

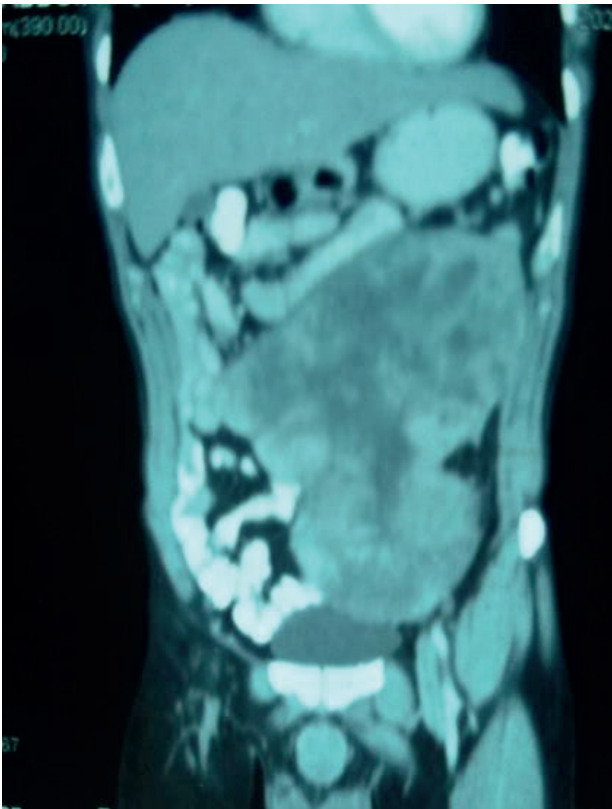


Figure 2. Coronal View of the tumor.

effacing left kidney causing mild hydronephrosis and inferiolaterally abutting adjacent descending colon. Multiple subcentimetric and mildly enlarged mesenteric lymph nodes noted. Liver parenchyma is unremarkable. Rest of the scan is unremarkable.

Ultrasound guided biopsy (Trucut needle) was done and the findings were atypical smooth muscle neoplasm. Mild to moderate atypia and mitoses, low grade LMS suspected. Exploratory laparotomy was then performed on 10th April 2020. Huge lobulated mass was found arising from

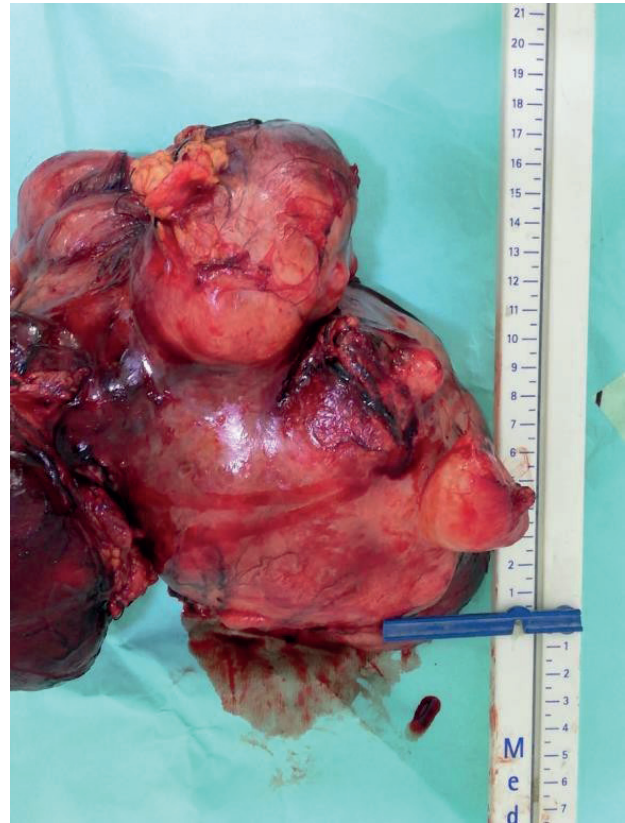


Figure 3. Gross view of the specimen.

the large bowel, near the splenic flexure involving the transverse mesocolon, splenic flexure and descending colon. Posteriorly, the mass was firmly adherent to the Gerota's Fascia of left kidney. The tumor was separated from the surrounding structures by ligasure, cavity washed and abdomen closed in layers. One pint of packed red blood cells was transfused intra-operatively. The excised mass was sent for biopsy and the result retrieved in 10 days. Patient spent first 24 hours post-operatively in intensive care unit for observation and one packed red blood cell volume was transfused there. The recovery was swift and on post-operative day 4, patient was discharged home.

On gross examination of the specimen (Figures 3 and 4), a brown multi nodular mass measuring $24 \times 21 \times 12.5$ cm with nodular outer surface, thin capsule, firm and gelatinous areas and hemorrhages in certain regions. This might be the largest size of the tumor ever reported as according to a literature review done by Affas et al. [10], they have analyzed 19 case and the largest size reported was 23 cm.

Microscopic examination reveals spindle cell lesion composed of cells having elongated cigar shaped nuclei and abundant eosinophilic cytoplasm with indistinct cell borders. At places, scattered focal moderate atypia is also seen in cells. Mitoses 2/10 high power field noted. Tumor was found to be 0.2 mm at the closest margin.

IHC stains were performed and the tumor was found to be α -smooth muscle actin positive, epithelial membrane

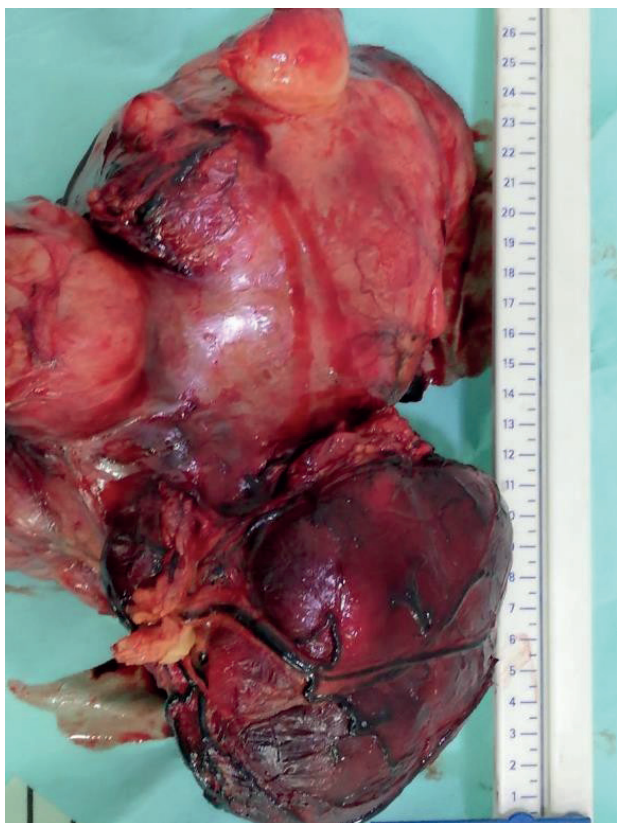


Figure 4. Gross view of the specimen.

antigen positive, H-Caldesmon positive, and Desmin positive. The tumor stained negative for CD117, CD34, Discovered on gastrointestinal stromal tumors protein 1, S100, and Cytokeraitv CAM 5.2.

The diagnosis of Low Grade LMS was made on the basis of histopathology. Patient is in follow up. No recurrence of symptoms has occurred till this day. Follow up CT scan is scheduled.

Discussion

Mesenteric LMS is a rare entity and it was first recorded by Yannopoulos and Stout [7]. The tumor takes its origin from the smooth muscle of mesenteric blood vessels [5]. The clinical presentation may vary from non-specific abdominal pain, abdominal distension, nausea, vomiting and diarrhea, most of the symptoms attributing to the compression of surrounding structures by the tumor [8]. Late cases may present with a palpable abdominal mass and significant weight loss. Distant metastasis to lungs and liver is common (50%) in contrast to lymph nodes [9]. On the CT imaging, LMSs are reported as tumors showing heterogenous attenuation due to the enhancement of solid portions of the tumor along with non-enhancing areas of hemorrhage, degeneration and necrosis [10].

In a literature review done by Affas et al. [11] reports the median age at presentation is 55 years with a female predominance (68%). The tumor has a poor prognosis with 5 years survival rate of 20%-30% [10]. The 5 years survival of retroperitoneal liposarcoma is reported as 61%

[12]. Surgical excision with wide tissue margin is the most effective mode of treatment since adjuvant chemo or radiotherapy has limited role [2]. Cytotoxic drugs such as Doxorubicin and Ifosamide has shown some role in advanced cases [10]. The recurrence of the tumor is the main cause of mortality among these patients and hence negative resection margins improve survival rates. Patients undergoing surgical resection need surveillance follow ups every 3-6 months for 2-3 years and then annually [13].

The role of core needle biopsy in the management of soft tissue tumors is noteworthy. As their usual presentation is of large abdominal masses, after the radiological workup is done, core needle biopsy shall be the next step. This does not only reveal the tumor pattern and histology, it is rather a fundamental step in tumor diagnosis. The diagnostic accuracy of core needle biopsy is reported to be as high as 99% [14]. Similarly in our case, it directed us towards the diagnosis with IHC staining adding up to their diagnostic yield.

Conclusion

Mesenteric LMS is an aggressive tumor, with poor prognosis. The most important prognostic indicators are the tumor size and location, as both of these factors can affect curative resection. Surgery is the mainstay of treatment. Radiotherapy can offer a better local control but does not improve 5-year survival and recurrence. For advanced stage, cytotoxic chemotherapy has shown a limited role. However, further trials need to be done on that.

We recommend that for an early diagnosis of LMS, MR, and CT imaging supplemented with core-needle biopsy shall be done. We also underline the need of Multidisciplinary Team coordination for the management of such tumors.

List of Abbreviations

IHC	Immunohistochemical
LMS	Leiomyosarcoma

Conflict of interest

The authors declare that there is no conflict of interest regarding the publication of this article.

Funding

None.

Consent for publication

Written consent was obtained from the patient.

Ethical approval

Ethical approval is not required at our institution to publish an anonymous case report.

Author details

- Muhammad Areeb Ashfaq¹, Summaya Saeed², Ammara Salam³, Pirhay Fatma⁴, Danish Faheem⁵, Aun Ali Khawaja³
1. Aga Khan University Hospital, Karachi, Pakistan
2. Dow University of Health Sciences, Karachi, Pakistan
3. Fazaia Ruth Pfau Medical College, Karachi, Pakistan

4. Liaquat University of Medical & Health Sciences, Karachi, Pakistan
 5. Ziauddin Medical University, Karachi, Pakistan

References

1. Dalal V, Kaur M, Menia R, Siraj F, Bhatnagar A, Agrawal U. Primary leiomyosarcoma of the mesentery: a case report. *Iran J Med Sci.* 2017;42:505–8.
2. Simonovich CJ, Hardman JM, Navin JJ, Jacobs J, Fergusson N. An unusual abdominal tumor -leiomyosarcoma of the mesentery: a case report. *Hawaii Med J.* 2006;65:18–20.
3. Schoucair R, Nicolas G, Ahdab R, Bejjani N, Abdalla EK. Posterior reversible encephalopathy syndrome (PRES) in mesenteric leiomyosarcoma: a case report. *Int J Surg Case Rep.* 2018;49:96–101. <https://doi.org/10.1016/j.ijscr.2018.04.043>
4. Weiss SW, Goldblum JR. Leiomyosarcoma. In: Weiss SW, Goldblum JR, editors. *Enzinger and Weiss’ s soft tissue tumors.* 5th ed. Philadelphia, PA: Mosby; 2008. Pp 769–88.
5. Kato T, Noda H, Abe I, Alonso S, Yokoyama N, Rikiyama T. Curative resection for leiomyosarcoma of the descending mesocolon with metachronous liver metastasis: a case report and literature review. *Mol Clin Oncol.* 2016;5:53–6. <https://doi.org/10.3892/mco.2016.874>
6. Ilias AS, Yaacob H, Wan Zain WZ, Zakaria AD. Rare case of primary leiomyosarcoma of sigmoid mesocolon. *BMJ Case Rep.* 2017;2017:bcr2017219826. <https://doi.org/10.1136/bcr-2017-219826>
7. Yannopoulos K, Stout AP. Primary solid tumors of the mesentery. *Cancer.* 1963;16:914–27. [https://doi.org/10.1002/1097-0142\(196307\)16:7<914::AID-CN-CR2820160708>3.0.CO;2-X](https://doi.org/10.1002/1097-0142(196307)16:7<914::AID-CN-CR2820160708>3.0.CO;2-X)
8. Varghese M, Bruland O, Wiedswang AM, Lobmaier I, Røsok B, Benjamin RS, et al. Metastatic mesenteric dedifferentiated leiomyosarcoma: a case report and a review of literature. *Clin Sarcoma Res.* 2016;6:2. <https://doi.org/10.1186/s13569-016-0042-6>
9. Hamed MO, Roberts KJ, Merchant W, Lodge JP. Contemporary management and classification of hepatic leiomyosarcoma. *HPB (Oxford).* 2015;17:362–67. <https://doi.org/10.1111/hpb.12366>
10. Levy AD, Manning MA, Al-Refaie WB, Miettinen MM. Soft-tissue sarcomas of the abdomen and pelvis: radiologic-pathologic features, part 1-common sarcomas: from the radiologic pathology archives. *Radiographics.* 2017;37(2):462–83. <https://doi.org/10.1148/rg.2017160157>
11. Affas S, Ayas MF, Mendes JM, Hadid T. Primary leiomyosarcoma of the mesentery: a case report with review of literature. *Cureus.* 2020;12(10):e10777. <https://doi.org/10.7759/cureus.10777>
12. Zhao X, Li P, Huang X, Chen L, Liu N, She Y. Prognostic factors predicting the postoperative survival period following treatment for primary retroperitoneal liposarcoma. *Chin Med J.* 2015;128(1):85–90. <https://doi.org/10.4103/0366-6999.147822>
13. Fong Y, Coit DG, Woodruff JM, Brennan MF. Lymph node metastasis from soft tissue sarcoma in adults: analysis of data from a prospective database of 1772 sarcoma patients. *Ann Surg.* 1993;217:72–77. <https://doi.org/10.1097/0000658-199301000-00012>
14. Hoerber I, Spillane AJ, Fisher C, Thomas JM. Accuracy of biopsy techniques for limb and limb girdle soft tissue tumors. *Ann Surg Oncol.* 2001;8:80–7. <https://doi.org/10.1007/s10434-001-0080-y>

Summary of the case

1	Patient (gender, age)	Male, 46 years old
2	Final diagnosis	Mesenteric LMS
3	Symptoms	Intermittent non-projectile vomiting and constipation
4	Medications	None
5	Clinical procedure	Exploratory laparotomy
6	Specialty	General surgery