

Bardet-Biedl syndrome with chronic kidney disease-CKD G5: a rare case report from India

Ravi Raju Tatapudi^{1,2*}, Satyanarayana Rentala², Ramya Varada³, Aruna Lakshmi Komarraju⁴, Anusha Pusapati⁴



OPEN ACCESS: This is an open access article distributed in accordance with the Creative Commons Attribution (CC BY 4.0) license: <https://creativecommons.org/licenses/by/4.0/> which permits any use, Share — copy and redistribute the material in any medium or format, Adapt — remix, transform, and build upon the material for any purpose, as long as the authors and the original source are properly cited.

ABSTRACT

Background: Bardet-Biedl Syndrome (BBS) is a rare autosomal ciliopathy disorder caused by mutations in genes encoding the proteins localized in primary cilia or basal body complex resulting in derangement of functions of various systemic organs containing cilia. The syndrome is characterized by classic phenotype features. Renal failure is a major cause of morbidity and mortality in these patients and early detection offers disease management benefit.

Case Presentation: We report for the first time in India, a case of BBS in advanced renal failure chronic kidney disease due to mutation in BBS12 gene, confirmed by next-generation sequencing. We also present clinical data, molecular genetics, and treatment of BBS.

Conclusion: Early diagnosis will help in the management of renal failure, thereby progression of the disease may be retarded. Further genetic mutations in all BBS genes can be studied by routine genotyping of all patients and followed up clinically.

Keywords: Bardet-Biedl syndrome, BBS gene, chronic kidney disease.

Received: 10 August 2020

Accepted: 06 April 2021

Type of Article: CASE REPORT

Specialty: Nephrology

Correspondence to: Ravi Raju Tatapudi

*Department of Nephrology, Apollo Hospitals, Visakhapatnam, India.

Email: ravitatapudi@gmail.com

Full list of author information is available at the end of the article.

Background

Bardet-Biedl Syndrome (BBS) is a genetically heterogeneous disease characterized by rod cone (retinal) dystrophy, central obesity, post-axial polydactyly, learning difficulties, hypogonadism, and renal disease with several minor features including developmental delay, speech abnormalities, brachydactyly, and dental anomalies [1-6]. BBS is a rare disease with a reported prevalence of 1:100,000 in North America and 1:160,000 in Europe [7]. The prevalence in consanguineous Arab populations is 1:65,000 and that in isolated inbred population of Newfoundland is 1:18,000 [5,8,9], whereas the prevalence in Indian population is unknown. Rod cone dystrophy and blindness are universal features of this disease. Renal disease is seen in 53%-82% of the patients whereas around 8% develop chronic kidney disease stage 5 (CKD G5). Though some patients develop CKD G5 in early childhood, several of them develop at a later stage in life [8]. Very few cases of patients with BBS in advanced kidney failure are reported from India [10,11]. In none of these patients, genomic sequencing was done to identify the abnormal gene. In the only cohort study from India where 30 families of BBS with genomic sequencing were reported, none of the patients had any renal involvement [2]. Molecular confirmation of BBS has evolved over the last decade from

targeted sequencing to next-generation sequencing (NGS) gene panels containing known BBS genes. The frequency at which molecular confirmation is achieved has increased to 40%-80% [8]. We report for the first time in India, a case of BBS in end stage renal failure where next generation sequencing revealed mutation in the BBS 12 gene.

Case Presentation

A 20-year-old male was brought to us by his parents for the treatment of chronic kidney disease. He was the product of consanguineous marriage and has a healthy female sibling. Milestones of development were delayed, and he was a school drop out after 1st grade. He was noticed to have nocturia and polyuria since childhood and he developed night blindness when he was around 4 years old. He had severe bilateral visual loss by age 10, and he was diagnosed to have retinitis pigmentosa (Figure 1). However, no further evaluation was done at this stage. He developed azotemic symptoms and edema of the legs 1 year ago when he was seen by two nephrologists. His serum creatinine was 353.6 $\mu\text{mol/l}$ and was diagnosed to have hypertension and CKD. Neither the ophthalmologist nor the nephrologists identified the syndrome. He was on conservative therapy since then. He came to us as

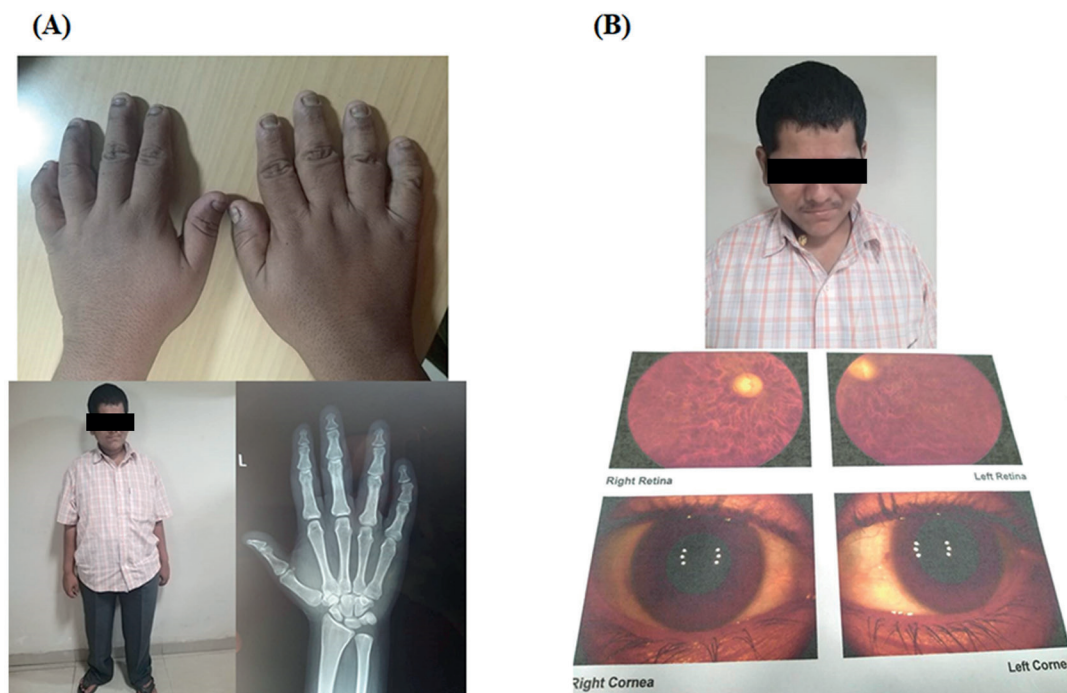


Figure 1. Clinical features of Bardet-Biedl syndrome patient. (A) Bilateral visual loss. (B) Retinitis pigmentosa. (C) Brachydactyly. (D) Edema of the limbs.

his renal functions deteriorated. On examination, he was obese with a body mass index of 34 kg/m^2 and a waist-hip ratio of 1:1.02. He had bilateral pitting edema and pallor. There was bilateral gynecomastia. He had brachydactyly of all fingers and toes and clinodactyly of both 5th fingers. Blood pressure was 150/100. Cardiovascular, respiratory and abdominal examination was unremarkable. Examination of genitalia revealed well-formed scrotum, buried penis, and bilateral testicular volume of 10-12 ml. Vision was restricted to perception of light in both the eyes. Laboratory investigations revealed hemoglobin of 5.83 mmol/l, normal CBC (Complete Blood Counts), serum creatinine was 618.8 $\mu\text{mol/l}$, urea 49.91 mmol/l, albumin 38 g/l, sodium 140 mmol/l, potassium 4.4 mmol/l, calcium 2.45 mmol/l, phosphate 2.2 mmol/l, and alkaline phosphatase 220 U/l. Blood glucose, lipid profile, and liver function tests were normal. His TSH (Thyroid Stimulating Hormone) was 4.0 $\mu\text{IU/ml}$, FSH (Follicular Stimulating Hormone) 4.3 minutes/ml, LH (Luteinizing Hormone) 3 minutes/ml, and Testosterone 6.969 mmol/l. Chest X-ray, EKG (Electrocardiogram), and cardiac echo were normal. Audiometry was normal. USG (Ultrasound Sonogram) and plain CT (Computerized Tomography) abdomen revealed bilateral small grade 3 echogenic kidneys and other organs were normal. Micturating cystourethrogram was normal. Fundoscopy revealed retinitis pigmentosa in both eyes. Basing on clinical criteria and investigations, a diagnosis of BBS with CKD G5 and hypogonadism was made. Informed consent was obtained from the patient. The case was evaluated for pathogenic gene variations by NGS at Medgenome, India.

A homozygous nonsense variation in exon 3 of BBS12 gene was detected, thereby confirming the genotype (Figure 2). Genetic test results are reported based on the recommendations of American College of Medical Genetics [12]. A homozygous nonsense variation in exon 3 of the BBS12 gene (chr4:g.123663276C>T; Depth: 134 \times) that results in a stop codon and premature truncation of the protein at codon 77 (p.Gln77Ter; ENST00000542236.1) was detected (Figure 2). The p.Gln77Ter variant has not been reported in the 1,000 genomes database and has a minor allele frequency of 0.001% and 0.003% in the ExAC and our internal databases, respectively. The reference codon is conserved across species. Coverage of BBS panel genes was given in Figure 2B. Diagnostic features were given in Figure 2C. The patient was started on antihypertensives, iron, calcium, and vitamin D supplementation and was explained about the need for renal replacement therapy. He will be started on maintenance Hemodialysis now.

Discussion

Bardet [13] and Biedl [14] independently described patients with retinitis pigmentosa, central obesity, renal disease, polydactyly, learning difficulties, and hypogonadism, and the syndrome is known after them as BBS. It is an autosomal recessive disease with wide spectrum of clinical features. Though several cohorts of patients were reviewed earlier, most comprehensive survey of a large population of 109 patients with BBS was done by Beales et al. [1]. Based on this study, diagnostic criteria were proposed to facilitate early diagnosis. Four primary or three primary and two secondary features are required

(A).

Gene (Transcript) #	Location	Variant	Zygoty	Disease (OMIM)	Inheritance	Classification
BBS12 (+) (ENST00000542236.1)	Exon 3	c.229C>T (p.Gln77Ter)	Homozygous	Bardet-Biedl syndrome-12	Autosomal recessive	Pathogenic

(B).

Gene	Percentage of coding	Gene	Percentage of coding	Gene	Percentage of Coding
ARL6	100	BBIP1	100	BBS1	100
BBS10	100	BBS12	100	BBS2	100
BBS4	100	BBS5	100	BBS7	100
BBS9	100	CCDC28B	100	CEP164	100
CEP19	100	CEP290	100	FBN3	100
IFT27	100	IFT74	100	LZTFL1	100
MKKS	100	MKS1	100	SDCCAG8	100
TMEM67	100	TRIM32	100	TTC8	100
WDPCP	98.21				

(C). Diagnostic Features

Primary Features	Frequency
Rod-Cone Dystrophy	93%
Polydactyly	63-81%
All Four Limbs	21%
Upper Limbs Only	9%
Lower Limbs Only	21%
Obesity	72-91%
Genital Anomalies	59-98%
Renal Anomalies	53%
Learning Difficulties	61%
Secondary Features	
Speech Delay	54-81%
Developmental Delay	50-91%
Diabetes mellitus	6-48%
Dental Anomalies	51%
Congenital Heart Disease	7%
Brachydactyl / syndactyl	46-100% / 8-95%
Ataxia / poor coordination	40-86%
Anosmia /Hyposmia	60%

Figure 2. Genomic and diagnostic features of Bardet–Biedl syndrome patient. (A) Mutation in exon 3 of BBS12 gene of the patient confirmed by next-generation sequencing. (B) Coverage of BBS panel genes during next-generation sequencing. (C) Diagnostic features of Bardet–Biedl syndrome. At least three major and two minor features are required to make a clinical diagnosis [7].

for diagnosis of BBS. Clinical evaluation in infancy is difficult as not all manifestations are congenital, and many appear later in childhood.

Very few cases of BBS in end stage renal disease have been reported from India [10,11]. In all these reports, the diagnosis was based on clinical criteria and in none of the patients, genetic studies were done to establish the BBS gene or the mutations.

Diagnosis of the disease was delayed in our patient because of lack of awareness and rarity of the syndrome. The

presence of rod cone dystrophy leading to night blindness from early childhood and total blindness by second decade is an important diagnostic feature and has a prevalence of 90%-100% [4,8]. When compared with hereditary retinitis pigmentosa visual impairment in BBS is consistently early in onset. Our patient had retinal dystrophy early in childhood and this should have prompted the ophthalmologist to suspect BBS (Figure 1). Other ocular features include myopia, strabismus and cataracts. Central obesity is seen in 70%-95% of patients [1]. Defects in hypothalamic

leptin-melanocortin axis cause leptin resistance culminating in obesity [8]. Post axial polydactyly was seen in 69% and limb defects like brachydactyly and sandal gap in 46%. Absence of polydactyly doesn't rule out the possibility of the disease and interestingly our patient had no polydactyly, but he had other limb abnormalities (Figure 1). Renal failure is a major cause of morbidity and mortality in BBS patients [15]. Various structural abnormalities like parenchymal cysts, vesico-ureteric reflux, ectopic kidneys, and hypoplastic kidneys have been described in up to 46% of patients [1]. Either structural or functional abnormalities of kidney were described in all patients in some case series [15], whereas in other series, only 82% had some form of renal involvement [16] But these abnormalities may not always lead to renal insufficiency. Renal insufficiency is noted in 5%-25% and CKD G5 in 4%-8% patients. Molecular mechanistic pathways leading to renal disease are not clear. Aberrant mTOR (mammalian target of rapamycin) signaling may contribute to cystic kidneys and renal failure later. Polyuria and nocturia in childhood and bilateral minute renal calculi, minimal proteinuria, and small kidneys in our patient are suggestive of chronic interstitial nephritis as a cause of renal failure. Diabetes, hypertension, and metabolic syndrome, the common secondary features of the syndrome, will lead to rapid deterioration of renal function.

BBS occurs as result of defect in BBS genes that code for ciliary proteins. The BBS proteins form a complex called BBS complex leading to ciliary dysgenesis and dysfunction.

In the last two decades, 21 BBS genes (BBS1 to BBS21) have been identified [8]. Mutations in genes BBS 1-18 account for about 70%-80% cases [10]. Frequent mutations in BBS1 and BBS 10 genes were reported in European descents contributing to 40%-50% cases [17]. In contrast, in Asian population, a novel, different spectrum of mutation in BBS 3 and 9 genes was observed [17]. Unlike in Europeans, BBS1 and BBS10 mutations account for only 7% and 10% cases, respectively, in Indian population [2]. BBS10 gene mutations clustered in exon 2 of the gene suggesting the exon as a probable hotspot for mutations in Indian population [18]. BBS-12 (OMIM#615989) is caused by homozygous or compound heterozygous mutations in the BBS12 gene (OMIM*610683). This disorder is primarily characterized by rod-cone dystrophy, polydactyly, obesity, learning disabilities and renal anomalies. Our BBS patient is unique as he presented with CKD G5 and has mutation in BBS 12, such case is hitherto unknown from India. Robust genomic analysis techniques available now, will provide prenatal and early diagnosis of BBS, so that major delay in diagnosis, as happened in our patient, can be avoided.

Management

Management of the disease is mostly by supportive therapy. Early detection is the key for correcting several

problems. Speech therapy and training in special schools for blind will help in the rehabilitation of these children. Diet, exercise, and bariatric surgery may prevent problems like diabetes, hypertension, and metabolic syndrome. Progression of renal disease can also be retarded by prevention of these secondary features. When patients progress to CKD G5, renal replacement therapy is the option. Hemodialysis, CAPD (Continuous Ambulatory Peritoneal Dialysis), and kidney transplantation have been tried successfully in BBS syndrome. Appropriate genetic counselling of families and regular medical follow up of the affected children by a group of specialists will help in effective management of the disease.

Conclusion

We have presented a patient with classic phenotype of BBS in end stage kidney failure. Determination of gene BBS12 led us to confirm the syndrome in spite of some atypical features; our patient had brachydactyly but primary feature of BBS, postaxial polydactyly was absent. Genetic studies early in life help us diagnose the condition even in those with one or two major features. Early diagnosis will help in the management of serious complications like renal failure, thereby progression of the disease can be retarded. Lack of awareness and rarity of the disease clearly delay the diagnosis of the syndrome. More genotype-phenotype associations can be made out by routine genotyping of all patients suspected to have BBS by standard criteria. We propose that all patients of BBS be genotyped early and stratified according to genotype and followed up clinically. Genetic analysis will be useful in pre-marital counseling in close family members and consanguineous marriages.

List of Abbreviations

BBS	Bardet-Biedl Syndrome
CKD	Chronic Kidney Disease

Conflict of interest

The authors declare that there is no conflict of interest regarding the publication of this article.

Funding

None.

Consent to participate

Written consent was obtained from the patient.

Ethical approval

Ethical approval is not required at our institution to publish an anonymous case report.

Author details

Ravi Raju Tatapudi^{1,2}, Satyanarayana Rentala², Ramya Varada³, Aruna Lakshmi Komarraju⁴, Anusha Pusapati⁴

1. Distinguished Professor, GITAM Institute of Medical Sciences and Research, GITAM (Deemed to be University), Visakhapatnam, India

2. Department of Health Informatics and Analytics, Apollo Hospitals Educational and Research Foundation, Chittoor, India
3. Department of Endocrinology, Apollo Hospitals, Visakhapatnam, India
4. Department of Biotechnology, GITAM (Deemed to be University), Visakhapatnam, India

References

1. Beales PL, Elcioglu N, Woolf AS, Parker D, Flinter FA. New criteria for improved diagnosis of Bardet-Biedl syndrome: results of a population survey. *J Med Genet.* 1999;36(6):437–46.
2. Sathya Priya C, Sen P, Umashankar V, Gupta N, Kabra M, Kumaramanickavel G, et al. Mutation spectrum in BBS genes guided by homozygosity mapping in an Indian cohort. *Clin Genet.* 2015;87(2):161–6. <https://doi.org/10.1111/cge.12342>
3. Klein D, Ammann F. The syndrome of Laurence-Moon-Bardet-Biedl and allied diseases in Switzerland. Clinical, genetic and epidemiological studies. *J Neurol Sci.* 1969;9(3):479–513. [https://doi.org/10.1016/0022-510X\(69\)90091-4](https://doi.org/10.1016/0022-510X(69)90091-4)
4. Green JS, Parfrey PS, Harnett JD, Farid NR, Cramer BC, Johnson G, et al. The cardinal manifestations of Bardet-Biedl syndrome, a form of Laurence-Moon-Biedl syndrome. *N Engl J Med.* 1989;321(15):1002–9. <https://doi.org/10.1056/NEJM198910123211503>
5. Farag TI, Teebi AS. High incidence of Bardet Biedl syndrome among the Bedouin. *Clin Genet.* 1989;36(6):463–4. <https://doi.org/10.1111/j.1399-0004.1989.tb03378.x>
6. Cherian MP, Al-Sanna'a NA. Clinical spectrum of Bardet-Biedl syndrome among four Saudi Arabian families. *Clin Dysmorphol.* 2009;18(4):188–94. <https://doi.org/10.1097/MCD.0b013e32832e4657>
7. Suspitsin EN, Imyanitov EN. Bardet-Biedl syndrome. *Mol Syndromol.* 2016;7(2):62–71. <https://doi.org/10.1159/000445491>
8. Forsythe E, Kenny J, Bacchelli C, Beales PL. Managing Bardet-Biedl syndrome-now and in the future. *Front Pediatr.* 2018;6:23. <https://doi.org/10.3389/fped.2018.00023>
9. Seo S, Guo DF, Bugge K, Morgan DA, Rahmouni K, Sheffield VC. Requirement of Bardet-Biedl syndrome proteins for leptin receptor signaling. *Hum Mol Genet.* 2009;18(7):1323–31. <https://doi.org/10.1093/hmg/ddp031>
10. Rathi M, Ganguli A, Singh SK, Kohli HS, Gupta KL, Sakhuja V, et al. Bardet-Biedl syndrome with end stage kidney disease. *Indian J Nephrol.* 2007;17(1):10–3. <https://doi.org/10.4103/0971-4065.35014>
11. Priya S, Nampoothiri S, Sen P, Sripriya S. Bardet-Biedl syndrome: genetics, molecular pathophysiology, and disease management. *Indian J Ophthalmol.* 2016;64(9):620–7. <https://doi.org/10.4103/0301-4738.194328>
12. Richards S, Aziz N, Bale S, Bick D, Das S, Gastier-Foster J, et al. Standards and guidelines for the interpretation of sequence variants: a joint consensus recommendation of the American College of Medical Genetics and Genomics and the Association for Molecular Pathology. *Genet Med.* 2015;17(5):405–24. <https://doi.org/10.1038/gim.2015.30>
13. Bardet G. Sur un syndrome d'obesite infantile avec polydactylie et retinite pigmentaire (contribution a l'etude des formes cliniques de l'obesite hypophysaire). 1920.
14. Biedl A. Ein Geschwisterpaar mit adiposo-genitaler Dystrophie. *Dtsch Med Wochenschr.* 1922;48:1630.
15. O'Dea D, Parfrey PS, Harnett JD, Hefferton D, Cramer BC, Green J. The importance of renal impairment in the natural history of Bardet-Biedl syndrome. *Am J Kidney Dis.* 1996;1;27(6):776–83. [https://doi.org/10.1016/S072-6386\(96\)90513-2](https://doi.org/10.1016/S072-6386(96)90513-2)
16. Forsythe E, Sparks K, Best S, Borrowes S, Hoskins B, Sabir A, et al. Risk factors for severe renal disease in Bardet-Biedl syndrome. *J Am Soc Nephrol.* 2017;28(3):963–70. <https://doi.org/10.1681/ASN.2015091029>
17. Harville HM, Held S, Diaz-Font A, Davis EE, Diplas BH, Lewis RA, et al. Identification of 11 novel mutations in eight BBS genes by high-resolution homozygosity mapping. *J Med Genet.* 2010;47(4):262–7. <https://doi.org/10.1136/jmg.2009.071365>
18. Chandrasekar SP, Namboothiri S, Sen P, Sarangapani S. Screening for mutation hotspots in Bardet-Biedl syndrome patients from India. *Indian J Med Res.* 2018;147(2):177–82. https://doi.org/10.4103/ijmr.IJMR_1822_15

Summary of the case

1	Patient (gender, age)	Male, 20 years old
2	Final diagnosis	Bardet Biedl Syndrome with Chronic Kidney Disease G5
3	Symptoms	Nocturia, polyuria, night blindness, severe bilateral visual loss, retinitis pigmentosa, azotemia, edema of legs, hypertension, obesity, bilateral pitting edema, bilateral gynaecomastia, brachydactyly, hypogonadism, CKD
4	Medications	Nifedipine retard, clonidine, iron, calcium, and vitamin D
5	Clinical procedure	None
6	Specialty	Nephrology