



an ex-smoker but did not drink or use recreational drugs. Family history was negative for thyroid cancer. Clinical examination showed a nodular goiter of the right thyroid and at least 3 enlarged lymph nodes of about 1.5 to 2 cm located in the right lateral neck (area IIB-III). She was in good general condition. Her laboratory findings including thyroid function tests were all within normal range.

Neck ultrasound confirmed the clinical observations. In the upper lobe of the right thyroid, two well-defined hypoechogenic nodules (of 7 and 10 mm, respectively) were observed, resembling benign thyroid adenomas. The left thyroid and isthmus were unremarkable. Additionally, in region IIIB of the right neck, three heterogeneous nodules (of 9, 18, and 20 mm, respectively) were observed, resembling ectopic thyroid tissue.

Cytology after fine-needle aspiration of the thyroid was normal (Bethesda 2). No malignant cells were retained in either of the two samples. No thyroid tissue was found in the lateral neck sample. Additional thyroglobulin immunohistochemistry was negative.

A <sup>99m</sup>Tc technetium-Single Photon Emission Computed Tomography (MIBI SPECT/CT) showed a moderate uptake of some structures located superior and lateral of the right thyroid proving the presence of thyroid tissue (Figure 1).

**Treatment**

After a multidisciplinary discussion, a diagnostic right hemithyroidectomy was proposed because of the thyroid nodularity. A total, right lateral neck dissection was proposed and discussed with the patient to reduce the risk of

future lateral recurrence of ectopic thyroid tissue growth. In the unlikely case of a micropapillary thyroid carcinoma with skip metastases, a completion left hemithyroidectomy could have been performed in a second time. A right hemithyroidectomy with total lateral neck dissection with lymphadenectomy was performed, removing all lymph nodes of neck areas IIA, IIB, III, and IV. During surgery, one elongated adenopathy and two cystic lesions with thyroid parenchyma were found. Additionally, a nodular cystic lesion was found in the upper part of the right thyroid lobe. The surgery was uneventful.

**Histopathology**

Postoperative histopathology reported the presence of ectopic thyroid tissue in 2 out of 14 lymph nodes. The lesion of the right thyroid was reported as nodular hyperplasia. No signs of a thyroid malignancy were found in the thyroid lobe or the lymph nodes (Figure 2).

**Follow up**

The patient was seen at the outpatient clinic 6 weeks after surgery. A routine blood test showed thyroid function tests within the normal range. No wound morbidity or voice changes were present. Laryngoscopy confirmed normal functioning vocal cords. Follow-up neck ultrasound performed 7 months after surgery depicted a single remaining lymph node close to the carotid neurovascular bundle. Due to its small diameter (6 mm), the previous benign pathology, and the proximity of the carotid artery, no further action was undertaken. After 2 years of clinical

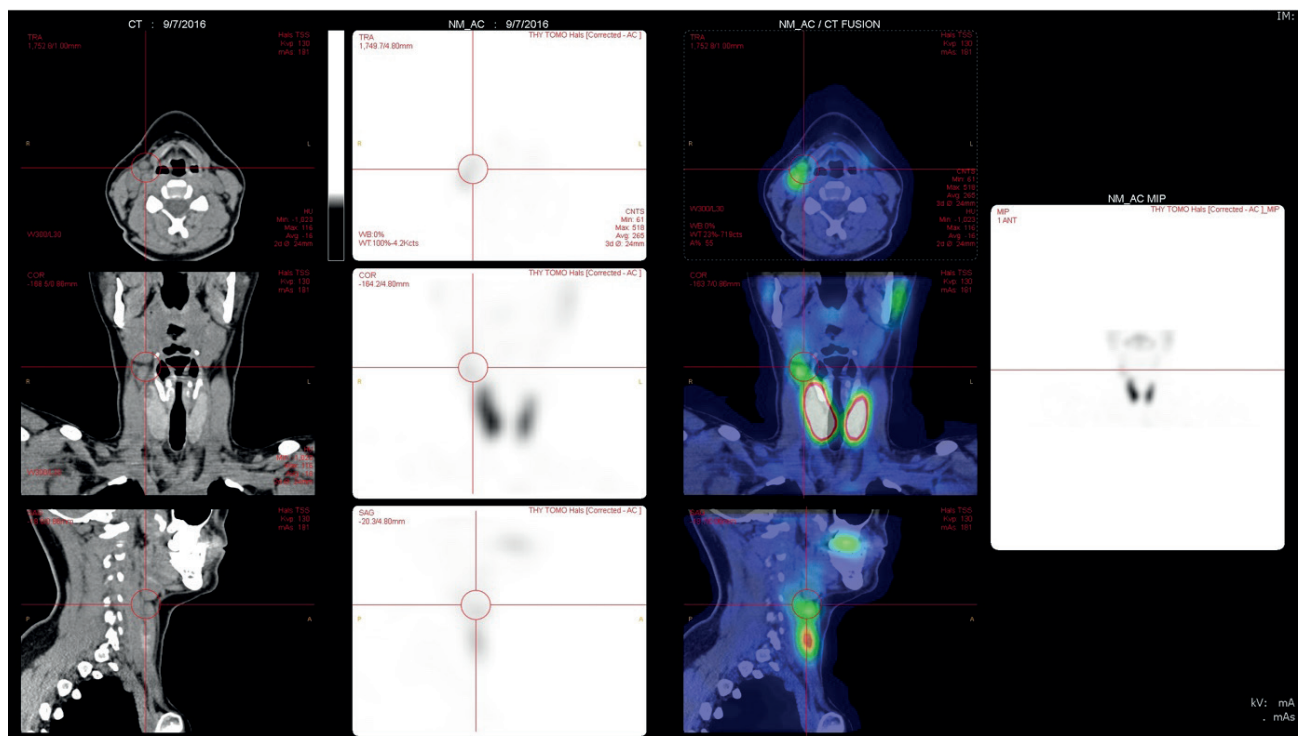
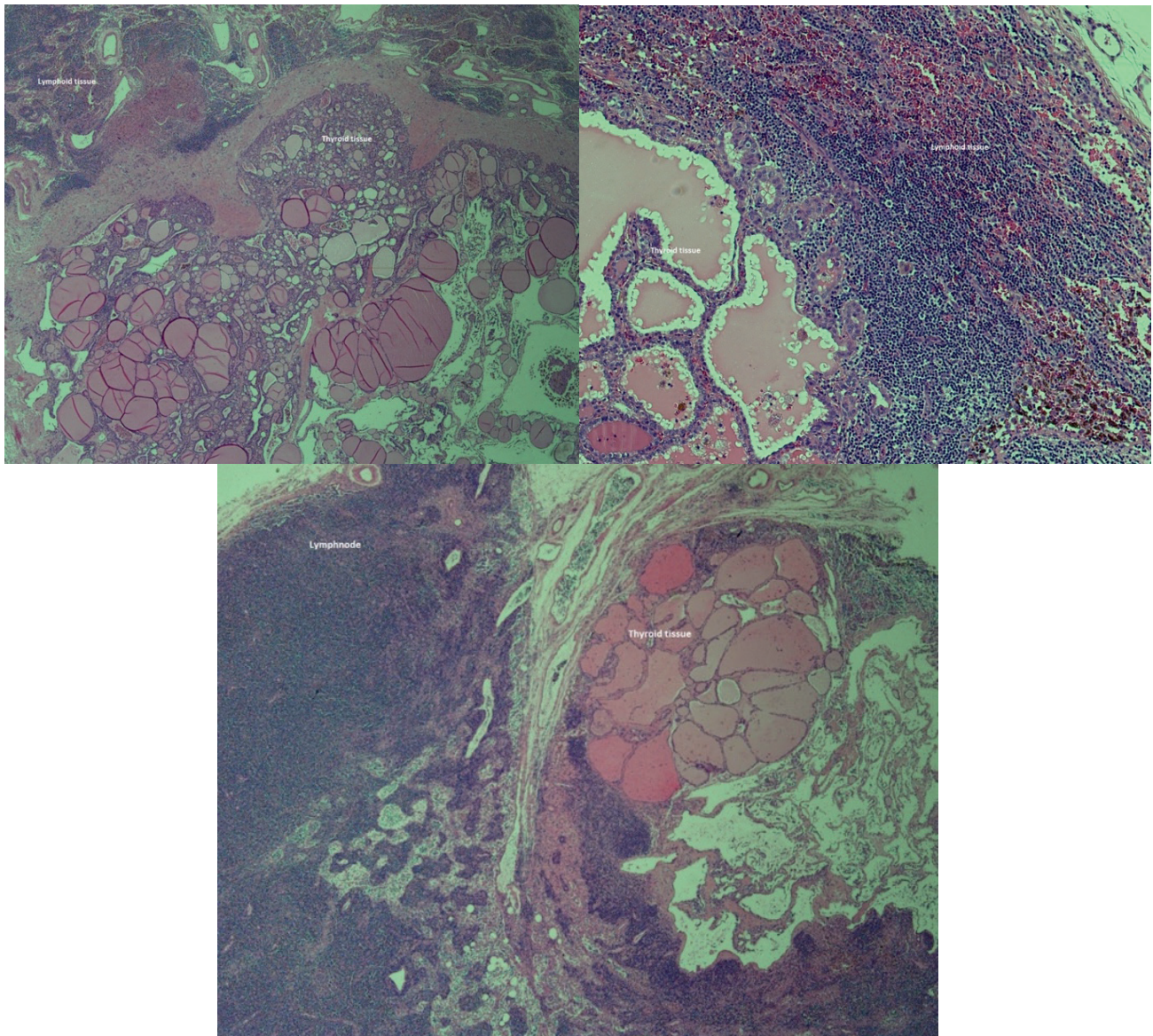


Figure 1. A <sup>99m</sup>Tc technetium-MIBI SPECT/CT fusion image. Slight zone of capitation located superior and lateral of the right thyroid lobe.



**Figure 2.** Postoperative histopathologic specimen. A/ Benign thyroid tissue within lymphoid tissue. B/ Benign thyroid tissue within a lymph node.

and ultrasound follow-up with identical appearance, the patient was discharged from follow-up.

## Discussion

The presence of thyroid tissue outside of the thyroid gland may occur in various clinical settings and anatomic locations. Differential diagnoses include both benign and malignant lesions [12].

Our patient's ectopic thyroid tissue was found in an uncommon location, as only 1% to 3% of all ectopic thyroid tissue is found in the lateral neck [6]. The location inside the lymph nodes themselves is even rarer. Only two similar cases have been reported [6,10]. This is a unique case of recurrent ectopic thyroid tissue, probably after spilling, present inside the capsule of the lymph nodes combined with a nodular thyroid lobe. The necessity of a hemithyroidectomy with a lateral neck

dissection to prevent recurrent (benign) enlarged lymph nodes in a young woman has not yet been published.

In our patient, the possibility of a micropapillary carcinoma with skip metastases was unlikely, as the presenting symptoms, clinical examination, and laboratory findings are rather uncommon in the case of thyroid cancer [13]. A  $^{99m}$ technetium-MIBI SPECT/CT to evaluate the cervical mass was done because it provides good anatomical detail, unlike a Positron Emission Tomography (PET) scan [14]. It proved the presence of thyroid tissue in the lymph nodes excluding some common causes of neck masses such as a branchial cleft cyst. The remaining differential diagnosis consisted of two conditions: micropapillary thyroid cancer with skip metastases and recurrent benign ectopic thyroid tissue [15].

Fine-needle aspiration was also performed. Compared to fine-needle aspiration for thyroid nodules, a higher rate

of false-negative results is seen when carried out in the context of a cystic neck mass [14].

The patient's medical history, clinical examination, thyroid function tests, and additional imaging might make a strong case for the presence of benign ectopic thyroid tissue. However, a definitive answer excluding thyroid cancer can only be provided by cytology or histopathology and given the high false-negative fine-needle aspiration results for cystic neck masses, a confident diagnosis remains difficult to make preoperatively. Therefore, the negative result of this patient was deemed not decisive enough to rule out malignancy.

It is still not clear whether ectopic thyroid tissue in the lymph nodes of the lateral neck is associated with thyroid cancer. This case supports the benign lymphatic transport theory of lateral ectopic thyroid. We opted to perform a total lateral neck dissection to avoid future ectopic thyroid growth. We share the opinion that it should be treated as metastases of thyroid cancer until proven otherwise [16].

## Conclusion

The presence of ectopic thyroid tissue in the lateral neck is rare, especially when present within the lymph nodes themselves. An important differential diagnosis with a thyroid malignancy must be made. Benign causes, such as ectopic thyroid tissue, are diagnoses by exclusion.

### What is new?

Only two cases of ectopic thyroid tissue in lateral cervical lymph nodes have been reported. The main and most important differential diagnosis in these cases is metastatic thyroid cancer. This case proves that a definitive answer to excluding thyroid cancer can only be provided by cytology or histopathology.

## List of Abbreviations

IIA, IIB, III, IV	Level IIA, IIB, III, IV topographic anatomy neck region
MeSH	Medical Subject Headings
MIBI SPECT/CT	Single Photon Emission Computed Tomography
PET	Positron Emission Tomography
TSH	Thyroid-Stimulating Hormone

## Conflict of interest

The authors declare that there is no conflict of interest regarding the publication of this article.

## Funding

None.

## Consent for publication

Written and informed consent was taken from patient to publish this case report.

## Ethical approval

Ethical approval is not required at our institution to publish an anonymous case report.

## Author details

Laurens Hutsebaut<sup>1</sup>, Klaas Van Den Heede<sup>2,3</sup>, Vanessa Meert<sup>4</sup>, Nele Brusselaers<sup>5,6</sup>, Sam Van Slycke<sup>2,7,8</sup>

1. Department of Clinical and Experimental Medicine, University Hospital Leuven, Herestraat, Leuven, Belgium.

2. Department of General and Endocrine Surgery, Onze-Lieve-Vrouw (OLV) Hospital Aalst, Moorselbaan, Aalst, Belgium.

3. Department of Endocrine and Digestive Surgery, Hôpital Pitié-Salpêtrière, AP-HP, Sorbonne University, 47-83 Boulevard de l'Hôpital, Paris, France.

4. Department of Pathology, Onze-Lieve-Vrouw (OLV) Hospital Aalst, Moorselbaan, Aalst, Belgium.

5. Center for Translational Microbiome Research Department of Microbiology, Tumor, and Cell Biology, Karolinska Institute, Karolinska Hospital, Tomtebodavagen, Stockholm, Sweden.

6. Global Health Institute, University of Antwerp, Doornstraat, Wilrijk, Belgium.

7. Department of Head and Skin, University of Ghent, Corneel Heymanslaan, Ghent, Belgium.

8. Department of General Surgery, AZDambiaan, Gouwelozestraat, Ostend, Belgium.

## References

- Ibrahim NA, Fadeyibi IO. Ectopic thyroid: etiology, pathology and management. *Hormones (Athens)*. 2011;10(4):261–9. <https://doi.org/10.14310/horm.2002.1317>
- Babazade F, Mortazavi H, Jalalian H, Shahvali E. Thyroid tissue as a submandibular mass: a case report. *J Oral Sci*. 2009;51(4):655–7. <https://doi.org/10.2334/josnusd.51.655>
- Guerra G, Cinelli M, Mesolella M, Tafuri D, Rocca A, Amato B, et al. Morphological, diagnostic and surgical features of ectopic thyroid gland: a review of literature. *Int J Surg*. 2014;12(Suppl 1):S3–11. <https://doi.org/10.1016/j.ijso.2014.05.076>
- Noussios G, Anagnostis P, Goulis DG, Lappas D, Natsis K. Ectopic thyroid tissue: anatomical, clinical, and surgical implications of a rare entity. *Eur J Endocrinol*. 2011;165(3):375–82. <https://doi.org/10.1530/EJE-11-0461>
- Yoon JS, Won KC, Cho IH, Lee JT, Lee HW. Clinical characteristics of ectopic thyroid in Korea. *Thyroid*. 2007;17(11):1117–21. <https://doi.org/10.1089/thy.2007.0004>
- Baek MK, Kim DY, Woo JH. A case of pediatric ectopic thyroid in lateral lymph nodes. *J Pediatr Endocrinol Metab*. 2015;28(1-2):227–30. <https://doi.org/10.1515/jpem-2014-0149>
- Bersaneti JA, Silva RD, Ramos RR, Matsushita Mde M, Souto LR. Ectopic thyroid presenting as a submandibular mass. *Head Neck Pathol*. 2011;5(1):63–6. <https://doi.org/10.1007/s12105-010-0209-z>
- Rabinov CR, Ward PH, Puscheck T. Evolution and evaluation of lateral cystic neck masses containing thyroid tissue: "lateral aberrant thyroid" revisited. *Am J Otolaryngol*. 1996;17(1):12–5. [https://doi.org/10.1016/s0196-0709\(96\)90036-8](https://doi.org/10.1016/s0196-0709(96)90036-8)
- Feller KU, Mavros A, Gaertner HJ. Ectopic submandibular thyroid tissue with a coexisting active and normally located thyroid gland: case report and review of literature. *Oral Surg Oral Med Oral Pathol Oral Radiol Endod*. 2000;90(5):618–23. <https://doi.org/10.1067/moe.2000.108804>
- Nicastri AD, Foote FW, Jr., Frazell EL. Benign thyroid inclusions in cervical lymph nodes. *JAMA*. 1965;194(1):1–4.
- Triggiani V, Giagulli VA, Licchelli B, Resta F, Fiore G, De Pergola G, et al. Ectopic thyroid gland: description of a case and review of the literature. *Endocr Metab Immune*

- Disord Drug Targets. 2013;13(3):275–81. <https://doi.org/10.2174/18715303113136660044>
12. Barbieri A, Prasad ML, Gilani SM. Thyroid tissue outside the thyroid gland: differential diagnosis and associated diagnostic challenges. *Ann Diagn Pathol*. 2020;48:151584. <https://doi.org/10.1016/j.anndiagpath.2020.151584>
  13. Soh SB, Aw TC. Laboratory testing in thyroid conditions - pitfalls and clinical utility. *Ann Lab Med*. 2019;39(1):3–14. <https://doi.org/10.3343/alm.2019.39.1.3>
  14. Goffart Y, Hamoir M, Deron P, Claes J, Remacle M. Management of neck masses in adults. *B-ENT*. 2005;Suppl 1:133–40.
  15. Gronlund S, Mey K, Andersen E, Rasmussen ER. The true malignancy rate in 135 patients with preoperative diagnosis of a lateral neck cyst. *Laryngoscope Investig Otolaryngol*. 2016;1(4):78–82. <https://doi.org/10.1002/lio2.23>
  16. Riva G, Villanova M, Francia G, Valotto G, Mezzetto L, Toiari M, et al. Lymphnode metastasis of thyroid cancer misinterpreted as lateral aberrant thyroid 40 years before identification of primary tumor. Case report and review of the literature. *Pathologica*. 2018;110(4):313–5.

### Summary of the case

1	<b>Patient (gender, age)</b>	Female, 34 years old, previous history of submandibular ectopic thyroid tissue removal
2	<b>Final diagnosis</b>	Recurrent ectopic thyroid tissue inside lateral cervical lymph nodes mimicking enlarged, suspicious lymph nodes
3	<b>Symptoms</b>	Painless right-sided adenopathy in the right lateral neck without clinical signs of hypo- or hyperthyroidism, compression, or voice changes
4	<b>Medications (generic)</b>	None
5	<b>Clinical procedure</b>	Hemithyroidectomy with ipsilateral neck dissection with total lymphadenectomy
6	<b>Speciality</b>	Endocrine surgery
7	<b>Objective</b>	Determine the risk of malignancy and the best treatment option for recurrent ectopic thyroid tissue versus a small risk of thyroid cancer with skip metastases.
8	<b>Background</b>	The presence of ectopic thyroid tissue in the lateral neck is rare, especially when present within the lymph nodes themselves. Important differential diagnosis with a thyroid malignancy must be made.
9	<b>Case report</b>	A case of recurrent ectopic thyroid tissue within lateral neck lymph nodes with three thyroid nodules was treated with a hemithyroidectomy and a total lateral neck dissection to exclude thyroid cancer and reduce the risk of ectopic thyroid tissue recurrence.
10	<b>Conclusions</b>	Recurrent ectopic thyroid tissue inside lateral cervical lymph nodes is extremely rare but can mimic thyroid cancer.
11	<b>Medical Subject Headings (MeSH) keywords</b>	Lymph nodes; thyroid dysgenesis; thyroid neoplasms; diagnosis, differential; thyroidectomy; neck dissection; case report