


Late metastasis of a clear-cell renal cell carcinoma in the gallbladder as a possible cause of acute cholecystitis: a case report

Julie Tuypens¹, Jaro Van Zande¹, Klaas Van Den Heede^{1*}, Sam Van Slycke^{1,2,3} 

European Journal of Medical Case Reports

Volume 8(2):37–40

DOI: 10.24911/ejmcr.173-1706128578



This is an open access article distributed in accordance with the Creative Commons Attribution (CC BY 4.0) license: <https://creativecommons.org/licenses/by/4.0/> which permits any use, Share — copy and redistribute the material in any medium or format, Adapt — remix, transform, and build upon the material for any purpose, as long as the authors and the original source are properly cited. © The Author(s) 2024

ABSTRACT

Background: Gallbladder metastasis from renal cell carcinoma (RCC) is extremely rare.

Case Presentation: We present a case of metastasis of clear cell carcinoma to the gallbladder, mimicking acute cholecystitis on clinical examination, in an 80-year-old man 24 years after radical nephrectomy. Ultrasound showed an image compatible with acute cholecystitis with sludge in the gallbladder. An elective cholecystectomy was performed with an uneventful postoperative course.

Histopathologic examination revealed a metastasis of clear-cell RCC.

The clinical presentation of acute cholecystitis can mask an RCC metastasis to the gallbladder, even several years after initial nephrectomy. This makes qualitative anatomopathological examination essential, especially with a neoplasia in the medical history. Gallbladder metastasis from RCC is not necessarily linked to a poor outcome. A cholecystectomy is recommended whenever possible.

Conclusion: This case highlights the importance of considering metastatic disease in the differential diagnosis of gallbladder masses and acute cholecystitis, even in patients with a history of treated primary tumors.

Keywords: Case report, gallbladder, metastasis, renal cell carcinoma.

Received: 24 January 2024

Accepted: 29 March 2024

Type of Article: CASE REPORT

Specialty: General Surgery

Correspondence to: Klaas Van Den Heede

*Consultant General Surgeon, Onze-Lieve-Vrouw (OLV) Hospital Aalst-Asse-Ninove, Aalst, Belgium.

Email: klaasvandenheede@hotmail.com

Full list of author information is available at the end of the article.

Background

Renal cell carcinoma (RCC) originates from the renal epithelium and accounts for >90% of cancers in the kidney [1]. RCC metastasizes in most cases to the lungs (75%), bone (20%), liver (18%), lymph nodes (11%), and brain (8%) [2]. Gallbladder metastasis from RCC is extremely rare and was found in less than 0.6% of cases at autopsy. Clinical diagnosis of gallbladder metastasis is even rarer [2].

Patients with metastasis from RCC usually have a poor prognosis, with a 5-year survival of <10% [3]. However, it is known that complete resection of the metastasis in patients with pancreatic metastasis of RCC improves survival [3]. This favorable prognosis probably also applies to patients with gallbladder metastasis [3].

We present a case of metastasis of clear cell RCC to the gallbladder, mimicking acute cholecystitis on clinical examination, in an 80-year-old man 24 years after radical nephrectomy.

The work has been reported in line with the SCARE criteria and cited in the following paper [4].

Case Presentation

An 80-year-old man presented in November 2022 to the emergency department because of vague abdominal pain for 4 days at the right hypochondrium. He did not experience nausea, vomiting, or fever. Besides an antibiotic treatment because of a urinary tract infection, no medication was taken. He underwent a left nephrectomy in 1998 in the context of a Grawitz tumor, an invasive clear-cell adenocarcinoma (hypernephroma). The primary tumor was discovered following a renal colic with hematuria, because of small pre-vesical lithiasis. Preoperatively, there were no indications of distant metastases, and retrograde pyelography showed no remaining lithiasis. The postoperative T-stage was T1 with a complete resection (R0). The multidisciplinary decision was made to refrain from adjuvant therapy. The patient was followed up every 4 months during the first year, every 6 months during the second year, and annually thereafter with blood tests, chest X-rays, and ultrasound of liver and kidney. Follow-up ended in 2015.

On clinical examination, a smooth, impressionable, and painless abdomen was found. No masses were felt, and the sign of Murphy was negative. Serum blood tests showed an elevated CRP level (59 mg/dl, Ref. 5 mg/l) without leukocytosis. There were no elevated cholestatic parameters. Ultrasound showed signs of cholecystitis (Hydrops of the gallbladder with wall thickening (up to 6 mm) and edema). with sludge or solid content in the gallbladder. No clear distinction could be made by the radiologist. No other pathological findings were reported.

Due to the prolonged duration of the symptoms, the decision was made to treat the cholecystitis initially with antibiotics (Amoxiclav 3 × 875 mg/day for 7 days). After 4 weeks, a laparoscopic cholecystectomy was performed. Macroscopically the gallbladder contained sludge and an inch-tall polyp. The patient was uneventfully discharged on the first postoperative day.

Histopathologic examination showed a metastasis of clear-cell RCC measuring 2.5 × 2.7 × 3.0 cm (Figures 1 and 2) Additional examination using contrast-enhanced computed tomography (CT) thorax and abdominal scan revealed no suspicious lymphadenopathies or lesions suspected of distant metastasis.

After a multidisciplinary discussion, no adjuvant therapy was given because the tumor was completely removed, the margins were negative, and no other distant metastases were found on additional staging examinations (CT scan of the thorax and abdomen). Further follow-up was performed annually with blood tests and ultrasound, and to date, the patient is doing well without any gastrointestinal or urinary complaints.

Discussion and literature review

Kidney cancers account for 4% of all newly diagnosed malignancies in men, with the majority being RCCs. Approximately 30% of all RCC cases have metastasis at the time of diagnosis.

The most common primary tumors associated with gallbladder metastasis include melanoma, breast, and lung cancer [5]. RCC metastasis to the gallbladder is an exceedingly rare occurrence, with only a handful of cases reported in the literature [6]. These metastases are often metachronous, with a median interval of 4 years after nephrectomy [6]. The clear cell type is present in almost all cases of RCC metastasis to the gallbladder. It is still unclear whether this is due to clear cell RCC being the most common type of RCC or whether this type of metastasis occurs only in the clear cell type [7].

Gallbladder metastasis from RCC is mostly asymptomatic and discovered incidentally through imaging, but some patients may present with biliary colic or acute cholecystitis. When a patient presents with acute cholecystitis, it is believed to be associated with a poorer prognosis [8]. In our case, the patient had acute cholecystitis and pre-operative imaging showed sludge. Previous studies have

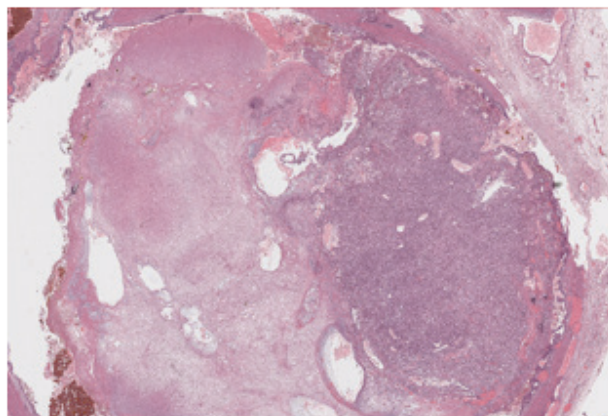


Figure 1. Low power view (40x magnification) of metastasis of clear-cell RCC.

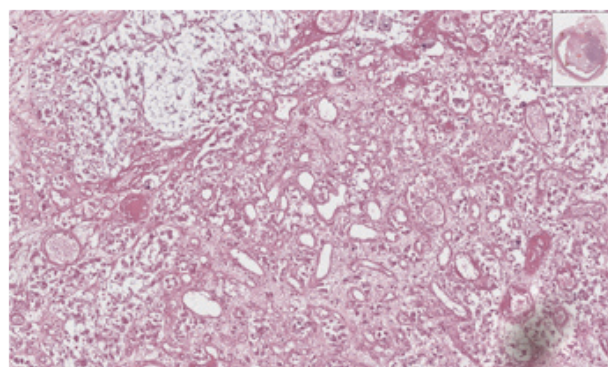


Figure 2. At a magnification 200x, the image reveals ample clear cytoplasm, round nuclei, and prominent nucleoli arranged within a capillary network.

shown that gallbladder metastasis is usually not associated with gallstones, while primary cholangiocarcinoma is often associated with lithiasis [9].

Diagnosis of gallbladder metastasis from RCC can be challenging, as it often mimics primary gallbladder malignancies. Transabdominal ultrasound is a good examination for visualizing gallbladder polyps, but it can be difficult to distinguish real and pseudo polyps [10].

On a CT scan, gallbladder metastasis is almost indistinguishable from a primary cholangiocarcinoma. All gallbladder metastases will present with infiltrative wall thickening or as a polypoid mass. These are also two of the three morphologic features of primary cholangiocarcinoma, i.e., infiltrative, polypoid, and mass forming [11].

Immunohistochemical analysis can be used to differentiate primary gallbladder cancer from RCC metastasis. Typically, primary gallbladder carcinoma shows positive staining for CK7, EMA, and CEA consistently, but is negative for CA9 and vimentin. On the other hand, metastatic clear cell RCC shows the contrary staining pattern. [12].

Gallbladder metastasis of RCC does not have a definitive treatment strategy. Typically, patients are diagnosed with widespread disease and multiple metastases in various organs, resulting in a poor prognosis [8]. However, in some rare cases, the gallbladder is the only site of

metastasis. According to the Japanese clinical practice guidelines for RCC in Japan, metastasectomy can improve disease-free period and survival if the patient is in good clinical condition and when complete resection is feasible [12]. In this context, a straightforward cholecystectomy may be adequate in fully eliminating the gallbladder metastasis, resulting in enhanced outcomes and survival.

A recent literature review reports a recurrence rate of around 48%, while a study by Chung et al. [13] followed 33 patients and found a five-year survival rate of 35%–50% after cholecystectomy. Adjuvant therapies such as chemotherapy, radiotherapy, and immunotherapy have been suggested after cholecystectomy, but there is no consensus on their effectiveness [13].

Conclusion

This case illustrates a rare presentation of acute cholecystitis caused by delayed metastasis of clear cell RCC to the gallbladder. It emphasizes the importance of a thorough evaluation (CT thorax and abdomen) of underlying causes in unexpected presentations of acute cholecystitis, particularly in patients with a history of treated primary tumors. Early detection and accurate diagnosis of gallbladder metastasis can significantly impact treatment decisions and patient outcomes. Further research is needed to better understand the pathogenesis and optimal management strategies for this rare clinical entity.

What is new?

This paper is significant because late gallbladder metastases from renal cell carcinoma are extremely rare. In this paper, the authors present a case of metastasis of clear cell RCC to the gallbladder, mimicking acute cholecystitis on clinical examination, 4 years after radical nephrectomy.

List of Abbreviations

CT	Contrast-enhanced computed tomography
RCC	Renal cell carcinoma

Conflict of interest

The authors declare that there is no conflict of interest regarding the publication of this article.

Funding

None.

Consent for publication:

Written informed consent was obtained from the patient.

Ethical approval

Ethical approval is not required at our institution to publish an anonymous case report.

Author details

Julie Tuypens¹, Jaro Van Zande¹, Klaas Van Den Heede¹, Sam Van Slycke^{1,2,3}

1. Department of General and Endocrine Surgery, Onze-Lieve-Vrouw (OLV) Hospital Aalst-Asse-Ninove, Aalst, Belgium

2. Department of Head and Skin, University Hospital Ghent, Ghent, Belgium

3. Department of General Surgery, AZ Damiaan, Ostend, Belgium

References

- Hsieh JJ, Purdue MP, Signoretti S, Swanton C, Albiges L, Schmidinger M, et al. Renal cell carcinoma. *Nat Rev Dis Primers*. 2017 Mar;3(1):17009. <https://doi.org/10.1038/nrdp.2017.9>
- White I, Smith S, Rizkalla K, Davies E. Unexpected gallbladder metastasis of clear cell renal carcinoma. *Clin Pathol*. 2019 Jul;12:X19861112. <https://doi.org/10.1177/2632010X19861112>
- Patterson GT, Ullah A, Elhelf I, Madi R, Kavuri SK, Karim NA. The unusual presentation of a single case of synchronous metastatic clear cell renal cell carcinoma to the gallbladder: a case report and literature review. *Curr Health Sci J*. 2021;47(3):457–61.
- Agha RA, Borrelli MR, Farwana R, Koshy K, Fowler AJ, Orgill DP, et al. The SCARE 2018 statement: Updating consensus Surgical Case report (SCARE) guidelines. *Int J Surg*. 2018 Dec;60:132–6. <https://doi.org/10.1016/j.ijssu.2018.10.028>
- Shyr BU, Chen SC, Shyr YM, Lee RC, Wang SE. Metastatic polyp of the gallbladder from renal cell carcinoma. *BMC Cancer*. 2017 Apr;17(1):244. <https://doi.org/10.1186/s12885-017-3243-3>
- Papalampros A, Davakis S, Syllaios A, Vagios I, Diamantopoulou P, Kyros E, et al. Late onset metastasis from renal cell carcinoma masquerading as a gallbladder polyp. *Ann R Coll Surg Engl*. 2021 Jan;103(1):e13–6.
- Dergamoun H, Gdaoui AE, Ziouziou I. Renal cell carcinoma with gallbladder metastasis: a case report. *Pan Afr Med J*. 2022 Oct;43:106. <https://doi.org/10.11604/pamj.2022.43.106.36588>
- Takagi K, Kawase K, Minoshima K, Yamaha M, Maekawa Y, Yokoi S, et al. Gallbladder metastasis from renal cell carcinoma: a case report and literature review. *Urol Case Rep*. 2019 Jan;23:69–71. <https://doi.org/10.1016/j.eucr.2019.01.006>
- Nojima H, Cho A, Yamamoto H, Nagata M, Takiguchi N, Kainuma O, et al. Renal cell carcinoma with unusual metastasis to the gallbladder. *J Hepatobiliary Pancreat Surg*. 2008;15(2):209–12. <https://doi.org/10.1007/s00534-007-1226-5>
- Cho SH, Han YS, Han JR, Kwon HJ, Choi SH, Kim HT, et al. Synchronous gallbladder metastasis of renal cell carcinoma presenting as a gallbladder polyp: a case report. *Medicine (Baltimore)*. 2021 Jan;100(3):e24037. <https://doi.org/10.1097/MD.00000000000024037>
- Kim CG, Kim SH, Cho SH, Ryeom HK. Gallbladder metastasis of renal cell carcinoma: a case report. *Taehan Yongsang Uihakhoe Chi*. 2021 Jul;82(4):959–63. <https://doi.org/10.3348/jksr.2020.0053>
- Oba T, Sato N, Tamura T, Fujimoto K, Matsuyama A, Hirata K. Gallbladder metastasis of renal cell carcinoma presenting as a hypervascular polypoid lesion: case report of two cases with immunohistochemical analysis. *surg case rep*. 2020 Apr 28. <https://doi.org/10.1186/s40792-020-00814-z>
- Chung PH, Srinivasan R, Linehan WM, Pinto PA, Bratslavsky G. Renal cell carcinoma with metastases to the gallbladder: four cases from the National Cancer Institute (NCI) and review of the literature. *Urol Oncol*. 2012;30(4):476–81. <https://doi.org/10.1016/j.urolonc.2010.04.010>

Summary of the case

1	Patient (sex, age)	80 years, male
2	Final diagnosis	Late gallbladder clear-cell RCC metastasis
3	Symptoms	Acute cholecystitis
4	Medications	Laparoscopic cholecystectomy
5	Clinical procedure	Surgery
6	Specialty	Oncology