

highlight areas of concern within the tomosynthesis stack. Hologic’s Genius AI Detection solution represents a significant step forward in this realm, offering decision support tools powered by advanced AI technology that are intended to aid radiologists in identifying and interpreting breast abnormalities with greater accuracy and efficiency compared to radiologists not using AI. Specifically tailored for use with digital breast tomosynthesis (DBT) systems, it aids in identifying soft tissue densities and calcifications in breast images. The software provides lesion scores for findings and an overall case score, facilitating the interpretation of DBT examinations. It is meant to be used concurrently with the radiologist’s assessment, enhancing efficiency and accuracy without replacing clinical judgment.

Genius AI Detection solution stands as an innovative DL algorithm designed to detect breast cancer from tomosynthesis images. The software aids in identifying suspicious breast lesions, including soft-tissue densities, spiculations, and calcification clusters, by analyzing each slice of Hologic 3D™ Mammography examinations using DL neural networks. It generates essential computer-aided detection (CAD) findings, including lesion location, outline, and lesion scores, along with an overall case score indicative of potential malignant lesion presence. Notably, the Genius AI Detection solution exhibits superior performance in true positive marking and reduces false positives, particularly in soft tissue lesions, compared to conventional 2D CAD systems [11]. Additionally, the algorithm provides insights into case complexity and reading priority on the acquisition workstation in the examination room, facilitating workflow adjustments tailored to site-specific needs and protocols. By focusing on areas of concern such as calcification clusters, soft tissue lesions, and their associations, Genius AI Detection solution impacts breast cancer detection by potentially enhancing radiologists’ diagnostic performance and reading efficiency. Genius AI Detection solution marks serve as indicators of potential areas of concern, identifying three primary characteristics commonly associated with cancer: (a) Calcification mark, denoting calcification clusters; (b) Mass mark, indicating soft tissue lesions encompassing masses, densities, and architectural distortions; and (c) Calc mark, signifying a soft tissue lesion associated with a calcification cluster.

The DL networks within Genius AI Detection solution employ two key metrics to aid in lesion identification and case assessment: Lesion Score and Case Score. The Lesion Score, assigned to each detected lesion, indicates the level of suspicion relative to other lesions and their respective lesion scores. It is normalized using a dataset of biopsy-proven malignant lesions, with a higher score indicating increased suspicion of malignancy. Conversely, the Case Score is derived from information

Table 1. Genius AI Detection 2.0 Solution: case scores and corresponding likelihood of cancer.

CASE SCORE ¹ (LIKELIHOOD OF SUSPICIOUS LESION)	LIKELIHOOD OF CANCER
0%	1 / 2862
1%-25%	1 / 1059
26%-50%	1 / 137
51%-75%	1 / 61
76%-100%	1 / 27

¹Note: Case score represents the likelihood of the presence of a suspicious lesion in a case. This score is expressed as a percentage and communicates how suspicious the case appears, but it is not a probability of cancer. The “1 in” cancer rate indicates the estimated frequency of cancer occurrence based on the case score.

gathered across all lesions detected in standard screening views and reflects the confidence that the entire case harbors a cancerous lesion (Table 1). Each Lesion Score ranges from 1 to 100 and reflects the level of suspicion associated with a lesion, suggesting whether further review may be warranted. However, it is important to note that a Lesion Score alone does not definitively determine if a lesion is cancerous. Diagnosis typically requires a biopsy, following standard care protocols. A lower Lesion Score indicates that the lesion appears less suspicious compared to known cancerous lesions in the database. Nonetheless, it does not guarantee that the lesion is benign. The Case Score is calculated based on the highest Lesion Score among the views processed for a case. Both scores are displayed as overlays during image review, facilitating radiologists’ interpretation. Additionally, the Genius AI Detection solution features a Reading Priority Indicator and Case Complexity Index to further assist radiologists in prioritizing and managing cases effectively. The Reading Priority Indicator, based on the Case Score, flags cases with heightened concern, and enables immediate review by radiologists. Meanwhile, the Case Complexity Index categorizes cases based on the number of identified findings, aiding in the customization of worklists and distribution of workload among radiologists. Genius AI Detection solution, a DL-based software developed and trained on Hologic tomosynthesis images, was evaluated in a multi-reader, multi-case study. Results showed radiologists’ clinical superiority, with a significant increase in the area under the ROC curve when Genius AI Detection solution was employed during reading compared to reading without aid from this software. Sensitivity in detecting cancer cases improved without compromising recall rates for non-cancer cases. The software’s outputs, including the Reading Priority Indicator and Case Complexity Index, enhance workflow efficiency in mammography centers. Genius AI Detection 2.0 Solution, the latest version, offers improved specificity and reduces false positives compared to the initial release.

The objective of this case series report is to assess the clinical effectiveness and utility of Hologic Genius AI Detection solution in identifying breast cancers, emphasizing its capacity to transform diagnostic precision and patient management in breast imaging. Through a comprehensive analysis of real-world cases, this report seeks to elucidate the impact of AI-driven technologies on improving breast cancer detection rates.

Case Presentation

Case CR-1

A 41-year-old female with a family history of breast cancer presented for a baseline mammogram. Notably, her maternal grandmother had been diagnosed with breast cancer at the age of 72. The patient's breast tissue was characterized as heterogeneously dense. Suspicious microcalcifications were identified in the left breast on both the medio-lateral oblique (MLO) and craniocaudal (CC) views, prompting further evaluation with magnification views. Genius AI Detection solution accurately detected the calcifications on both MLO and CC views, assigning lesion a score of 85% for each and an overall case score of 85%. (Figure 1) Given the high score, the

case was flagged as a high priority. Subsequent stereotactic biopsy confirmed the presence of ductal carcinoma *in situ* (DCIS). The pathology report revealed two distinct foci of invasive ductal carcinoma (IDC) in the breast tissue, both Nottingham grade 2, display varied histological features - one with mucinous, tubular, and lobular characteristics, the other with apocrine features - while both are positive for estrogen (ER) and progesterone receptors (PRs) and negative for HER-2/NEU. This case underscores the utility of Genius AI Detection solution in identifying abnormalities in patients with dense breast tissue, thereby facilitating early detection and intervention.

The early detection of DCIS is crucial for optimal patient outcomes. We report a case demonstrating the clinical utility of Hologic's Genius AI Detection solution in DCIS in a young patient with heterogeneously dense breast tissue and a family history of breast cancer. Hologic's Genius AI Detection solution played a pivotal role in identifying and prioritizing suspicious microcalcifications in this case, leading to the timely diagnosis of DCIS. This case highlights the effectiveness of AI-driven technologies in improving the accuracy and efficiency of

Table 2. Investigating the potential of Hologic Genius AI Detection solution in breast cancer screening: observations from 3 case reports.

CASE	PATIENT CHARACTERISTICS	CAD GENIUS AI DETECTION FINDINGS	PATHOLOGY REPORT
Case CR-1	A 41-year-old female with a family history of breast cancer, notably her maternal grandmother diagnosed at 72, underwent baseline mammogram, revealing heterogeneously dense breast tissue.	Suspicious microcalcifications in the left breast on MLO and CC views led to further evaluation with magnification views. Genius AI Detection solution accurately detected calcifications, assigning a lesion score of 85% for each view and an overall case score of 85%.	Two distinct foci of invasive ductal carcinoma in breast tissue, both Nottingham grade 2, exhibit varied histological features - one with mucinous, tubular, and lobular characteristics; the other with apocrine features - both positive for estrogen and progesterone receptors, negative for HER-2/NEU.
Case CR-2	A 58-year-old woman, with no family history of breast cancer, underwent regular screening mammogram.	The CAD findings indicate scattered breast density, with asymmetry noted in the right breast at the 12 'O clock. The lesion was accurately marked on both craniocaudal (CC) and medio-lateral oblique (MLO) views, with lesion scores of 54% and 84%, respectively. Spot compression views confirmed the persistence of the abnormality. Tomosynthesis highlighted spiculations of the lesion, demonstrating the specificity of Genius AI Detection solution in detecting high-priority lesions.	The pathology report revealed the presence of invasive ductal carcinoma with well-differentiated tubular features, testing negative for HER-2/NEU and positive for estrogen and progesterone receptors.
Case CR-3	A 42-year-old woman, underwent a routine screening mammogram, and there is no history of breast cancer in her family.	The examination showed scattered fibroglandular densities, with asymmetry noted on the right MLO view and marked by the Genius AI Detection solution with a high-priority case score of 87%. Further evaluation confirmed the presence of an invasive lobular carcinoma, underscoring the importance of the Genius AI Detection's accurate marking in facilitating prompt diagnosis.	The pathology report revealed invasive lobular carcinoma, with positive estrogen receptor (ER) and progesterone receptor (PR) status, while the status of HER-2/NEU was equivocal.

breast cancer detection, particularly in patients with dense breast tissue and a family history of breast cancer.

Case CR-2

We report a case demonstrating the clinical utility of Hologic's Genius AI Detection solution in identifying and localizing a high-priority lesion subsequently confirmed to be IDC.

A 58-year-old female with no family history of breast cancer presented for routine screening mammography. Scattered breast density was noted, with asymmetry observed in the right breast at the 12 o'clock position. The lesion was accurately marked on both cranio-caudal (CC) and MLO views, with lesion scores of 54% and 84%, respectively. Spot compression views confirmed the persistence of the abnormality (Figure 2). Tomosynthesis highlighted spiculations of the lesion. Subsequent ultrasound revealed an irregular spiculated nodule diagnosed as IDC. Invasive well-differentiated ductal carcinoma with tubular features, HER-2/NEU negative, and positive for ER and PRs were identified in the pathology report.

The case demonstrates the specificity of the Genius AI Detection solution in detecting high-priority lesions, as evidenced by the accurate localization and high case score (case score 84%) assigned to the identified abnormality.

Screening mammography is essential for early detection of breast cancer, particularly in asymptomatic individuals. Genius AI Detection solution played a vital role in the early detection of IDC in a patient undergoing screening mammography. This case highlights the ability of Hologic Genius AI Detection solution to identify small spiculated areas and facilitate the focused evaluation of abnormalities, ultimately leading to the timely diagnosis of breast cancer. Early detection of IDC is crucial for optimal patient outcomes. Hologic Genius AI Detection solution demonstrated its effectiveness in identifying and prioritizing the suspicious nodule, facilitating prompt diagnostic evaluation and intervention.

Case CR-3

A 42-year-old female underwent a screening mammogram with no family history of breast cancer. The examination revealed scattered fibroglandular densities, with no abnormalities detected on the CC views bilaterally (Figure 3A). However, an area of asymmetry was identified on the right MLO view (Figure 3B) and flagged by the Genius AI Detection solution with a high-priority case score of 87%.

Further evaluation of the asymmetrical area confirmed the presence of an invasive lobular carcinoma. Invasive lobular carcinoma, ER and PR positive, with HER-2/NEU status equivocal, as indicated in the pathology report. Genius AI Detection's marked lesion without additional distracting

markings proved instrumental in drawing attention to this high-priority case and facilitating prompt diagnosis.

Hologic Genius AI Detection solution facilitated the early detection of invasive lobular carcinoma in a 42-year-old female undergoing screening mammography. This case underscores the importance of utilizing AI-driven technologies in enhancing early cancer detection, particularly in patients with no family history of breast cancer. Invasive lobular carcinoma can be challenging to detect

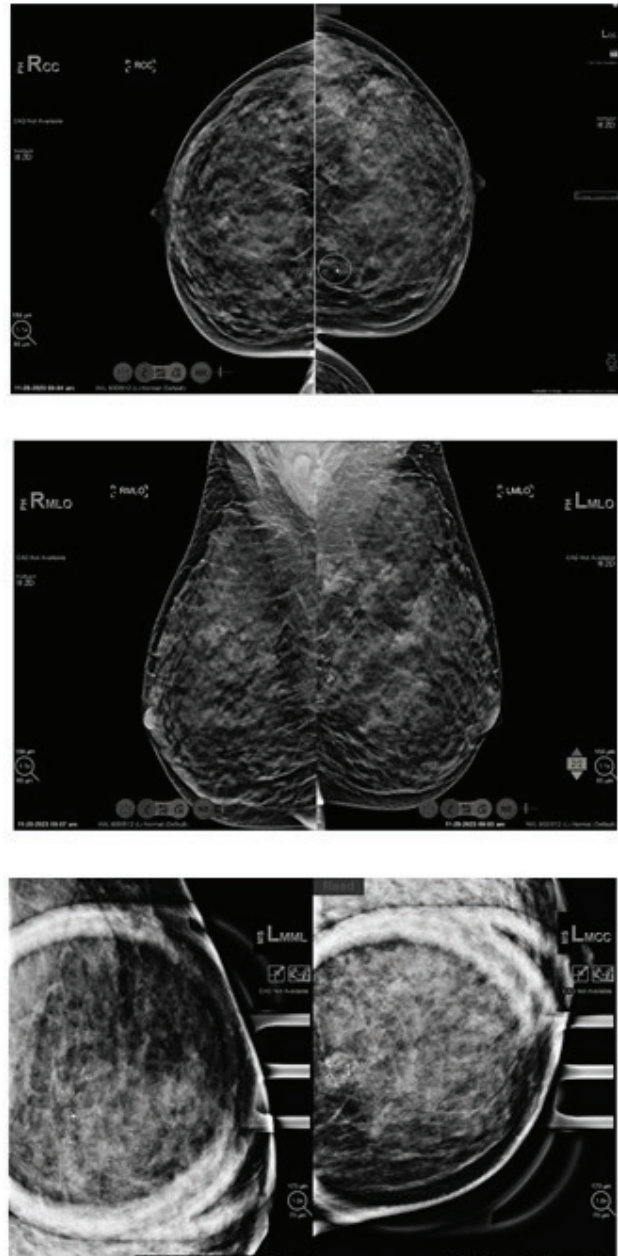


Figure 1. (A) (CC view) and (B) (MLO view) demonstrate suspicious microcalcifications in the left breast of a 41-year-old female with heterogeneously dense breast tissue. The Genius AI correctly identified the calcifications with a lesion score of 85 on both views, contributing to an overall case score of 85%. The case was flagged as high priority, leading to a stereotactic biopsy and subsequent diagnosis of DCIS. (C) depicts magnification views obtained during the biopsy procedure.

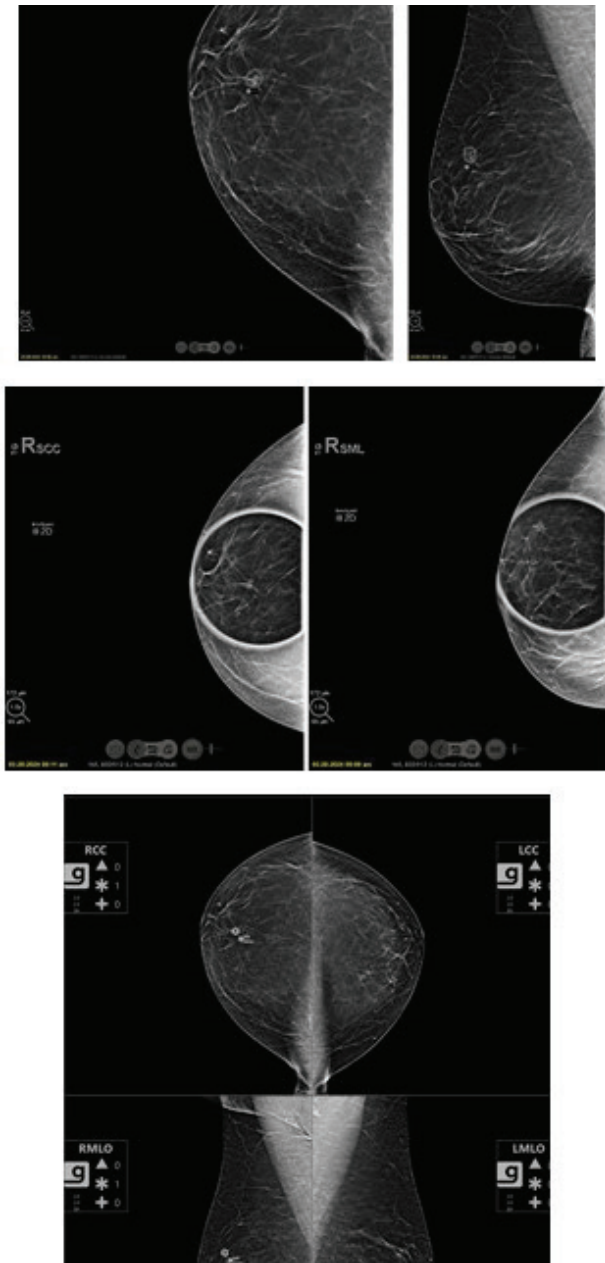


Figure 2. Screening mammogram images of a 58-year-old female with no family history of breast cancer. Scattered breast density is observed. Asymmetry noted in the right breast 12 o’ clock position, accurately marked in the CC view with a lesion score of 54% and marked on the MLO view with a lesion score of 84% (A). Spot compression views confirm the persistence of the identified area (B). Tomosynthesis image highlighting the spiculations of the lesion. Illustration of the Genius technology’s specificity, with only one area marked, resulting in the case being flagged as high priority. The case score was 84%. The lesion was marked in both views, enabling quick localization of the abnormality (C).

on mammography, particularly in its early stages. Hologic Genius AI Detection solution played a crucial role in identifying and prioritizing the suspicious area, leading to the timely diagnosis of breast cancer.

Discussion

The cases (Table 2) presented demonstrate the clinical utility of the Hologic Genius AI Detection solution in

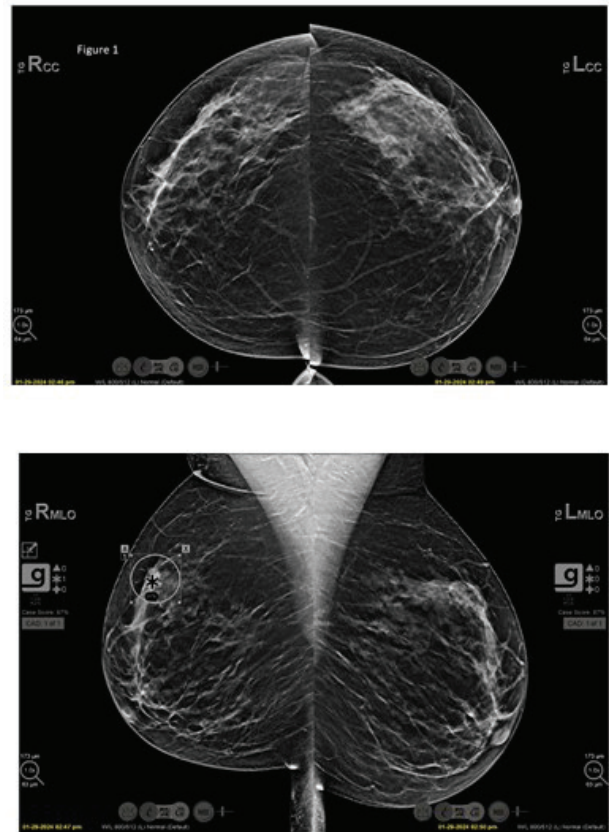


Figure 3. (A) Displays the CC views of a 42-year-old female with scattered fibroglandular densities and no family history of breast cancer, showing no abnormalities bilaterally. (B) Presents the right MLO view revealing an area of asymmetry marked by the Genius AI Detection with a case score of 87% and flagged as high priority.

enhancing breast cancer detection. Across diverse patient demographics and breast tissue compositions, the integration of AI-driven technology has shown significant promise in improving the accuracy and efficiency of identifying suspicious lesions, ultimately leading to early diagnosis and intervention.

In Case CR-1, the detection of DCIS highlights the ability of Genius AI Detection solution to identify subtle abnormalities, particularly in patients with dense breast tissue and a family history of breast cancer. By accurately detecting suspicious microcalcifications, Genius AI Detection solution facilitated the timely diagnosis of DCIS, emphasizing its role in enhancing early cancer detection in high-risk individuals.

Case CR-2 underscores the effectiveness of the Hologic Genius AI Detection solution in detecting small spiculated areas, leading to the early diagnosis of IDC. Despite the absence of a family history of breast cancer, the integration of the Genius AI Detection solution enabled the prioritization and focused evaluation of suspicious findings, ultimately facilitating prompt diagnostic intervention.

In Case CR-3, the early detection of invasive lobular carcinoma emphasizes the importance of utilizing

AI-driven technologies, particularly in patients with no family history of breast cancer. By flagging asymmetrical areas with a high priority case score, Genius AI Detection solution drew attention to suspicious findings, enabling timely diagnosis and intervention in a challenging-to-detect cancer subtype.

Overall, the cases demonstrate the impact of Hologic Genius AI Detection solution in breast cancer by enabling diagnostic precision and enhancing patient management. By leveraging DL algorithms to prioritize cases and provide essential CAD findings, Genius AI Detection solution potentially enhances radiologist efficiency and accuracy, ultimately improving patient outcomes in breast cancer detection and treatment. In addition, outcomes from GAID can lead to a workflow solution for radiologists by prioritizing reading order in a busy clinic. This solution is trained on image data from diverse demographics and has been proven to enhance radiologists' sensitivity of cancer detection. GAID also offers immediate access to results right on the acquisition workstation and allows for point-of-care triaging and faster response to patients. The three presented cases demonstrate clinical utility of GAID solution in identifying, localizing, and prioritizing cancerous lesions in a screening mammography practice. Further research and widespread adoption of AI-driven technologies like Genius AI Detection solutions are essential to continue advancing breast imaging and optimizing patient care.

Conclusion

The cases exemplify how Hologic Genius AI Detection solution can potentially improve breast cancer detection in clinical practice.

What is new?

Known in the literature: challenges in breast cancer detection: the manuscript outlines the limitations of traditional mammography, particularly in detecting cancer in dense breast tissues, and the variability in radiologists' interpretations. These challenges have been well-documented, with prior research highlighting the need for improved diagnostic tools. Use of AI in medical imaging: the integration of AI in medical imaging, particularly in enhancing the accuracy and efficiency of breast cancer detection, is a growing field. AI's ability to analyze vast amounts of imaging data and identify subtle abnormalities is recognized as a significant advancement. Novel: Genius AI Detection Solution: the manuscript presents the Genius AI Detection solution, a deep learning algorithm designed specifically for use with DBT systems. It provides detailed CAD findings, including lesion scores and case scores, to assist radiologists in identifying suspicious areas. This tool not only marks potential lesions but also categorizes them based on suspicion levels, which is a novel approach in the field.

Acknowledgment

We would like to express our sincere gratitude to all those who have contributed to this manuscript. Special thanks to Hologic team members Scott Pohlman, Elektra Alivisatos, Martin Wan, Muhammad Waqas, Julia Mathis, Joyce Bourgeois and Jheelam Banerjee for their review of manuscript and invaluable support and assistance throughout the study.

Conflicts of interest

Dr. Gizienski is a consultant for Hologic, Inc. Drs. Singh and Kshirsagar are employees of Hologic, Inc. Dr. Kandhi is contractor employee of Hologic, Inc.

Funding

Funding was provided by Hologic, Inc. to Dr. Gizienski for image reading, analysis, and histo-path reports.

Consent for publication

Not necessary for this manuscript.

Ethical approval

Not necessary for this manuscript.

Author details

Rani Singh¹, Sharath Kandhi¹, Ashwini Kshirsagar², Terri-Ann Gizienski³

1. Clinical Affairs, Breast and Skeletal Health, Hologic Inc, Marlborough, MA, USA
2. Research and Development, Breast and Skeletal Health, Hologic Inc, Marlborough, MA, USA
3. Clinical Breast Imaging Division, Department of Radiology, University of Pittsburgh, Pittsburgh, PA, USA

References

1. Berry DA, Cronin KA, Plevritis SK, Fryback DG, Clarke L, Zelen M, et al.; Cancer Intervention and Surveillance Modeling Network (CISNET) Collaborators. Effect of screening and adjuvant therapy on mortality from breast cancer. *N Engl J Med*. 2005 Oct;353(17):1784–92. <https://doi.org/10.1056/NEJMoa050518>
2. Nelson HD, Fu R, Cantor A, Pappas M, Daeges M, Humphrey L. Effectiveness of breast cancer screening: systematic review and meta-analysis to update the 2009 U.S. Preventive services task force recommendation. *Ann Intern Med*. 2016;164(4):244–55. <https://doi.org/10.7326/M15-0969>
3. Boyd NF, Guo H, Martin LJ, Sun L, Stone J, Fishell E, et al. Mammographic density and the risk and detection of breast cancer. *N Engl J Med*. 2007 Jan;356(3):227–36. <https://doi.org/10.1056/NEJMoa062790>
4. Houssami N, Lee CI, Buist DSM, Tao D. Artificial intelligence for breast cancer screening: Opportunity or hype? *Breast*. 2017;36:31–3. <https://doi.org/10.1016/j.breast.2017.09.003>
5. Elmore JG, Barton MB, Moceri VM, Polk S, Arena PJ, Fletcher SW. Ten-year risk of false positive screening mammograms and clinical breast examinations. *N Engl J Med*. 1998 Apr;338(16):1089–96. <https://doi.org/10.1056/NEJM199804163381601>
6. McKinney SM, Sieniek M, Godbole V, Godwin J, Antropova N, Ashrafian H, et al. International evaluation of an AI system for breast cancer screening. *Nature*. 2020;577(7788):89–94. <https://doi.org/10.1038/s41586-019-1799-6>

7. Ribli D, Horvath A, Unger Z, Pollner P, Csabai I. Detecting and classifying lesions in mammograms with deep learning. *Sci Rep*. 2018;8(1):4165. <https://doi.org/10.1038/s41598-018-22437-z>
8. Friedewald SM, Rafferty EA, Rose SL, Durand MA, Plecha DM, Greenberg JS, et al. Breast cancer screening using tomosynthesis in combination with digital mammography. *JAMA*. 2014 Jun;311(24):2499–507. <https://doi.org/10.1001/jama.2014.6095>
9. McDonald ES, Oustimov A, Weinstein SP, Synnestvedt MB, Schnall M, Conant EF. Effectiveness of digital breast tomosynthesis compared with digital mammography: outcomes analysis from 3 years of breast cancer screening. *JAMA Oncol*. 2016 Jun;2(6):737–43. <https://doi.org/10.1001/jamaoncol.2015.5536>
10. Conant EF, Zuckerman SP, McDonald ES, Weinstein SP, Korhonen KE, Birnbaum JA, et al. Five consecutive years of screening with digital breast tomosynthesis: outcomes by screening year and round. *Radiology*. 2020 May;295(2):285–93. <https://doi.org/10.1148/radiol.2020191751>
11. Bahl M, Kshirsagar A, Pohlman S, Lehman C. Performance of a traditional machine learning computer-aided detection (CADe) algorithm versus a deep learning artificial intelligence (AI) algorithm on digital breast tomosynthesis (DBT) studies. *European Congress of Radiology 2024*.

Summary of the Case

Case	Patient characteristics	CAD Genius AI Detection findings	Pathology report
CR-1	41-year-old female, family history of breast cancer.	Detected suspicious microcalcifications in the left breast with an overall case score of 85%.	Two foci of invasive ductal carcinoma, Nottingham grade 2, ER/PR positive, HER-2/NEU negative.
CR-2	58-year-old woman, no family history of breast cancer.	Detected asymmetry in the right breast with lesion scores of 54% (CC) and 84% (MLO).	Invasive ductal carcinoma with tubular features, ER/PR positive, HER-2/NEU negative.
CR-3	42-year-old woman, no family history of breast cancer.	Detected asymmetry on the right MLO view with a case score of 87%.	Invasive lobular carcinoma, ER/PR positive, HER-2/NEU equivocal.