


# Shingles infection resulting from BCG treatment for bladder cancer: a case report

Vivian Wong<sup>1\*</sup> , Diana M. Lopategui<sup>2</sup>, Elias Atri<sup>1</sup>, Akshay Bhandari<sup>2</sup>

European Journal of Medical Case Reports

Volume 5(1):18–21

<https://doi.org/10.24911/ejmcr/173-1592252959>



OPEN ACCESS: This is an open access article distributed in accordance with the Creative Commons Attribution (CC BY 4.0) license: <https://creativecommons.org/licenses/by/4.0/> which permits any use, Share — copy and redistribute the material in any medium or format, Adapt — remix, transform, and build upon the material for any purpose, as long as the authors and the original source are properly cited.

## ABSTRACT

**Background:** Bacillus Calmette-Guerin (BCG) bladder instillations have been long known to successfully treat non-muscle invasive bladder cancer. The objective of this report is to highlight the first case to our knowledge of Varicella Zoster virus (VZV) shingles reactivation to BCG.

**Case presentation:** An 80-year-old male with history of Parkinson's disease and recurring high-grade T1 bladder cancer. Five days after first repeat BCG instillation, patient presented to the emergency room with a progressively worsening rash that started 1 day after treatment, characterized as VZV shingles reactivation. Intravenous acyclovir treatment produced rapid clinical improvement.

**Conclusion:** Reactivation of dormant VZV infection may be a reaction to BCG intravesical instillation. This is, to the authors' knowledge, the first documented case of this complication. Although coincidence cannot be completely ruled out, the timing of this case and the context of immunosuppression-immunomodulation inherent to BCG therapy make causality plausible.

**Keywords:** BCG, shingles, bladder cancer, adverse reaction, varicella zoster, case report.

Received: 15 June 2020

Accepted: 21 October 2020

Type of Article: CASE REPORT

Specialty: Urology

Correspondence to: Vivian Wong

\*Herbert Wertheim College of Medicine, Florida International University, Miami, FL.

Email: [vwong010@fiue.edu](mailto:vwong010@fiue.edu)

Full list of author information is available at the end of the article.

## Background

Bladder cancer is the fourth most common cancer in males, with non-muscle invasive bladder cancer (NMIBC) accounting for 80% of all bladder cancers [1,2]. Bacillus Calmette-Guerin (BCG) bladder instillations have been long known to successfully treat NMIBC cancer [2]. Used for over 40 years, it is the most effective intravesical immunotherapy agent known to decrease invasion risk of NMIBC [3]. The mechanism is largely unknown, and the failure rates reach 40% of patients [2]. Some adverse effects have been well described as a result of BCG instillations, mainly BCG cystitis, systemic disease, or pneumonitis [4].

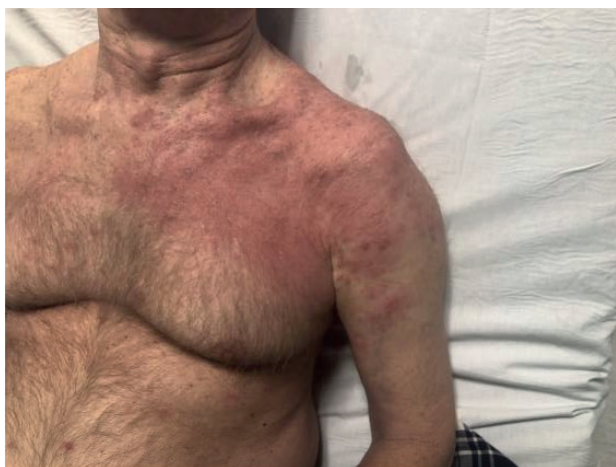We hereby present a case report describing a patient with bladder cancer who presented with an extensive vesicular rash starting 1 day after instillation of intravesical BCG. Rash was identified as a reactivation of a Varicella Zoster virus (VZV) shingles infection. This is, to the authors' knowledge, the first reported case of this adverse reaction to BCG.

## Case Presentation

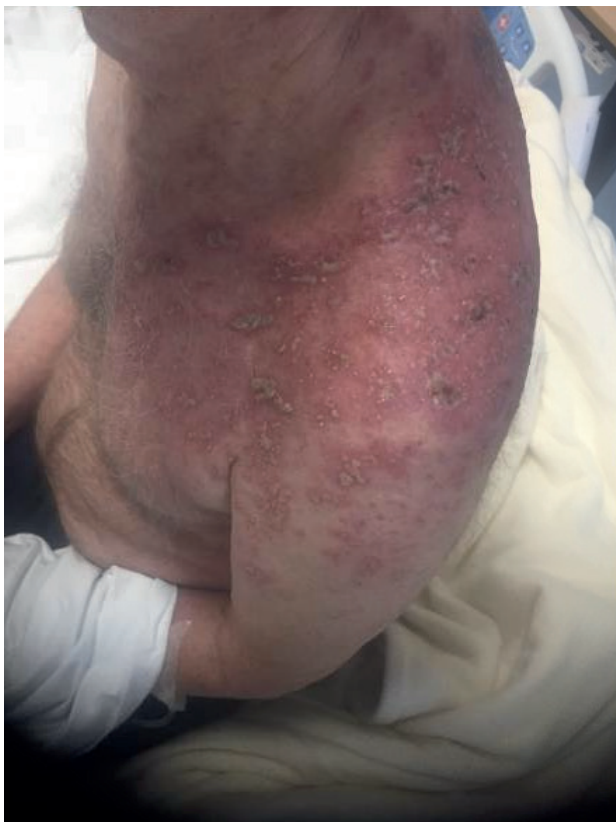The patient is an 80-year-old male with history of Parkinson's disease and high-grade T1 bladder cancer, first diagnosed 2 months prior to initial presentation to our institution, after a cystoscopy was performed at an

outside hospital due to 3 weeks of on and off hematuria. He underwent transurethral resection of bladder tumor (TURBT) in two occasions 1 year and 1 month apart, showing high-grade transitional cell carcinoma with no muscle invasion. As is indicated in high grade NMIBC [5], he underwent a complete course of immunotherapy induction and maintenance with six cycles of BCG. He had an acceptable tolerance of the induction cycles but was unable to complete the maintenance treatment, due to experiencing significant dysuria and flu-like symptoms after each course. The last dose of the treatment was administered at a 1/3 dilution in an attempt to limit these adverse effects, with limited improvement. One year and 8 months after completion of maintenance treatment, follow-up cystoscopy showed a small area of recurrence. Patient underwent a repeat TURBT, and recurrence pathology reported high grade, non musculo-invasive transitional cell carcinoma. The decision was made to repeat BCG treatment. He had no significant immediate reaction to the administration of the first treatment and tolerated it well. He reported voiding comfortably with some mild dysuria, which he experiences at baseline. Five days after the first instillation, the patient presented to the emergency room with a progressively worsening rash that started one day after the treatment. The rash

consisted of fluid-filled <5 mm vesicles over the patient's left shoulder and upper lateral chest quadrant, in a C4 dermatome distribution (Figure 1). A consult was placed from the emergency room to the infectious diseases specialty service, which characterized the rash as VZV shingles reactivation. Patient was admitted for intravenous Acyclovir treatment, with rapid clinical improvement. He completed 3 days of intravenous treatment and was discharged in stable condition on clinical day 3 after marked clinical improvement (Figure 2), to complete the 10 days of oral therapy. Following doses of BCG were held, no evidence of recurrence was found on follow up cystoscopies after 4 weeks, 3 months, and 1 year. At 1 year follow



**Figure 1.** Day 1 of admission, day 5 after BCG.



**Figure 2.** Day 3 of admission, day 8 after BCG.

up, patient reports scars and occasional pain and itching at the initial site of the rash which is further indicative of VZV shingles reactivation.

## Discussion

We present the first case to the authors' knowledge of VZV shingles reactivation after intravesical BCG immunotherapy. The patient had a history of recurrent NMIBC presenting with fluid-filled vesicles in a dermatomal distribution 1 day following the BCG treatment.

BCG has been used as a treatment for bladder cancer for over 40 years. The typical schedule of BCG treatment includes induction therapy with weekly instillations for 6 weeks, and maintenance therapy for 3 weeks at 3 and 6 months after, and then every 6 months for 3 years. The number of BCG doses to complete treatment total 27. In one study, the over-all complete response rate, which included a negative cytology and biopsy result, was 66% [6]. However, in the Southwest Oncology Group Trial, only 16% completed the full trial of all 27 instillations, implying broadly that many patients are not completing the treatment course [7]. Therefore, adequate BCG therapy has been defined as at least 5 out of 6 instillations of induction therapy and at least 2 out of 3 maintenance treatments for at least 6 months [8].

The treatment with BCG is generally well tolerated, but certain effects can be common, such as the ones experienced in our patient during the first treatment. Infectious complications are an uncommon but well documented adverse effect of BCG instillation: Cystitis, sepsis, hepatitis, pneumonitis, osteomyelitis, arthritis, and infections of prosthetic devices have been described [4]. In these cases, if a causing microorganism was isolated, it was most commonly *Mycobacterium Bovis* or bacteria [4]. Mild side effects include local bladder symptoms like cystitis, dysuria, and hematuria, which have been reported in up to 85% of patients [4]. More severe, local BCG infections have been described, including bladder ulcerations, granulomatous prostatitis and BCGitis in epididymo-orchitis [4]. Those are less frequent, reported in less than 4.5% of cases [4]. Common systemic complications include fever without sepsis, and more rarely fever with sepsis, an incidence of less than 4% in most studies [9]. Pulmonary or miliary infections after BCG instillation seem to be common manifestations, constituting up to 50% of the systemic infections in one Spanish population [4]. Other rare systemic complications include aortic mycotic aneurysm, psoas abscesses, granulomatous hepatitis, cerebral tuberculoma, meningitis, ocular manifestations, and Guillain Barre syndrome [4].

Certain risk factors can contribute to the spread of BCG hematogenously, such as traumatic catheterization leading to urothelial barrier disruption, instillation of BCG early after TURBT, concurrent urinary tract infection or immunologic dysfunction [4]. Therefore, all these

may increase the risk of systemic complications after administration.

The full mechanism of BCG in limiting bladder cancer progression is still unknown but is generally accepted to be an immunologically mediated modality of treatment. Evidence shows that cells of the immune system and urothelial cells both play roles [10]. Suggested mechanisms entail the cancer cells of the bladder attaching and internalizing BCG, which triggers an immune response by secretion of both cytokines and chemokines and presentation of BCG to immune cells. Cell types implicated in this immune response include CD4+ and CD8+ lymphocytes, natural killer cells, granulocytes, macrophages, and dendritic cells [10]. All these cells are recruited for an immunologic response mainly localized to the bladder. The cells secrete tumor necrosis factor-related apoptosis-inducing ligand which causes direct cytotoxicity [10].

The pathogenesis of VZV begins with the virus entering the body through the respiratory tract. The result is a vesicular pruritic rash called chicken pox. As a member of the herpesvirus family, VZV can establish latency in the dorsal root or cranial root ganglia and lay dormant there until reactivation. The reaction of VZV is associated with a decreased cell-mediated immunity seen in older patients and immunocompromised hosts [11]. With this proposed mechanism, it is not impossible to think that BCG instillation could cause an immunocompromised state as the systemic system targets bladder cancer cells leaving room for shingles reactivation.

## Conclusion

BCG is the most effective treatment in NMIBC. This treatment does not come without side effects, commonly including cystitis and pneumonitis. More serious post-instillation effects have been observed, such as pulmonary and miliary infections. In our patient, reactivation of dormant VZV infection may be a reaction to BCG intravesical instillation. This is, to the authors' knowledge, the first documented case of this complication. Although coincidence cannot be completely ruled out, the timing of this case and the context of immunosuppression-immunomodulation inherent to BCG therapy make causality plausible.

### What is new?

BCG is the most effective treatment in NMIBC. This treatment does not come without side effects, commonly including cystitis and pneumonitis. In our patient, reactivation of dormant VZV infection may be a reaction to BCG intravesical instillation. This is, to the authors' knowledge, the first documented case of this complication.

## List of Abbreviations

BCG Bacillus Calmette-Guerin  
NMIBC Non-muscle invasive bladder cancer

TURBT Transurethral resection of bladder tumor  
VZV Varicella Zoster virus

## Funding

None.

## Conflict of interests

Authors declare there are no conflicts of interest in the publication of this article.

## Consent for publication

Not applicable.

## Ethical approval

Ethical approval is not required to publish anonymous case reports at our institution.

## Author details

Vivian Wong<sup>1</sup>, Diana M. Lopategui<sup>2</sup>, Elias Atri<sup>1</sup>, Akshay Bhandari<sup>2</sup>  
1. Herbert Wertheim College of Medicine, Florida International University, Miami, FL  
2. Division of Urology, Columbia University Mount Sinai Medical Center, Miami, FL

## References

- Jemal A, Siegel R, Ward E, Murray T, Xu J, Thun MJ. CA Cancer J Clin. 2007;57(1):43–66. <https://doi.org/10.3322/canjclin.57.1.43>
- Heney NM. Natural history of superficial bladder cancer. Prognostic features and long-term disease course. Urol Clin North Am. 1992;19:429–33.
- Alhunaidi O, Zlotta AR. The use of intravesical BCG in urothelial carcinoma of the bladder. Ecanermedicalscience. 2019;13:905. <https://doi.org/10.3332/ecancer.2019.905>
- Larsen ES, Joensen UN, Poulsen AM, Goletti D, Johansen IS. Bacillus Calmette-Guérin immunotherapy for bladder cancer: a review of immunological aspects, clinical effects and BCG infections. APMIS. 2020. 128(2):92–103. <https://doi.org/10.1111/apm.13011>
- Chang SS, Bochner BH, Chou R. Treatment of non-metastatic muscle-invasive bladder cancer: AUA/ASCO/ASTRO/SUO guideline. J Urol. 2017;198:552–9. <https://doi.org/10.1016/j.juro.2017.04.086>
- Eure GR, Cundiff MR, Schellhammer PF. Bacillus Calmette-Guerin therapy for high risk stage T1 superficial bladder cancer. J Urol. 1992;147:376–9. [https://doi.org/10.1016/S0022-5347\(17\)37241-5](https://doi.org/10.1016/S0022-5347(17)37241-5)
- Lamm DL, Blumenstein BA, Crissman JD, Montie JE, Gottesman JE, Lowe BA. Maintenance bacillus Calmette-Guerin immunotherapy for recurrent TA, T1 and carcinoma in situ transitional cell carcinoma of the bladder: a randomized Southwest Oncology Group Study. J Urol. 2000;163(4):1124–9. [https://doi.org/10.1016/S0022-5347\(05\)67707-5](https://doi.org/10.1016/S0022-5347(05)67707-5)
- Chang SS, Boorjian SA, Chou R, et al. Diagnosis and treatment of non-muscle invasive bladder cancer: AUA/SUO guideline. J Urol. 2016;196:1021–9. <https://doi.org/10.1016/j.juro.2016.06.049>
- Larsen ES, Nordholm AC, Lillebaek T, Holden IK, Johansen IS. The epidemiology of bacille Calmette-Guérin infections after bladder instillation from 2002 through 2017: a nationwide retrospective cohort study. BJU Int. 2019;124(6):910–6. <https://doi.org/10.1111/bju.14793>

10. Redelman-Sidi G, Glickman M, Bochner B. The mechanism of action of BCG therapy for bladder cancer—a current perspective. *Nat Rev Urol.* 2014;11:153–162. <https://doi.org/10.1038/nrurol.2014.15>
11. Gershon AA, Gershon MD, Breuer J, Levin MJ, Oaklander AL, Griffiths PD. Advances in the understanding of the pathogenesis and epidemiology of herpes zoster. *J Clin Virol.* 2010;48 (Suppl 1):S2–7. [https://doi.org/10.1016/S1386-6532\(10\)70002-0](https://doi.org/10.1016/S1386-6532(10)70002-0)

### Summary of the case

1	<b>Patient (gender, age)</b>	80-year old male
2	<b>Final diagnosis</b>	Reactivation of dormant VZV infection that may be a reaction to BCG intravesical instillation
3	<b>Symptoms</b>	Rash consisted of fluid-filled <5mm vesicles over the patient’s left shoulder and upper lateral chest quadrant, in a C4 dermatome distribution
4	<b>Medications</b>	Intravenous acyclovir
5	<b>Clinical procedure</b>	BCG intravesical instillation
6	<b>Specialty</b>	Urology