


Osteoclastic giant cell tumor of the pancreas with osteoid and bone formation: a case report

Ioannis Provatat^{1*} , Dimitrios Sabaziotis¹,
Chrissa Stamou¹, Georgia Mitropoulou², Helen
Trihia³

European Journal of Medical Case Reports
Volume 5(1):07–11
<https://doi.org/10.24911/ejmcr/173-1584863716>



OPEN ACCESS: This is an open access article distributed in accordance with the Creative Commons Attribution (CC BY 4.0) license: <https://creativecommons.org/licenses/by/4.0/> which permits any use, Share — copy and redistribute the material in any medium or format, Adapt — remix, transform, and build upon the material for any purpose, as long as the authors and the original source are properly cited.

ABSTRACT

Background: Extrasosseous giant cell tumors involving visceral organs (pancreas, kidneys, bladder, etc.) and soft tissues present similar histological features to those occurring in the bones. Rarely, they may affect pancreas and their origin remains still controversial, with some authors supporting the epithelial and some others the mesenchymal origin.

Case Presentation: We report the case of a pancreatic giant cell tumor with osteoclast-like cells, negative for epithelial markers. A 64-year-old man presented with a 2-month history of progressively worsening abdominal pain, radiating to the lumbar region. He reported no other symptoms. The abdominal clinical examination was unremarkable and there was no associated jaundice. Liver function tests remained within normal limits. His past medical history had nil of note. He underwent an outpatient abdominal computed tomography which revealed a large cystic lesion at the body of the pancreas measuring 10 × 7 × 6.5 cm. We proceeded with a limited excision of the pancreatic mass alone, avoiding major dissections that would unnecessarily increase morbidity and mortality and the post-operative course was good. The histological morphological and immunohistochemical assessment revealed two tumor cell types: osteoclast-like multinucleated giant cells and pleomorphic mononuclear cells, with bone formation and without important cellular and nuclear atypia.

Conclusion: Pancreatic giant cell tumors with osteoclast-like giant cells are rare tumors of the pancreas with various clinical characteristics and controversial origin. En bloc resection has prevailed as the only beneficial treatment so far.

Keywords: Osteoclastic giant cell tumor of the pancreas, bone, osteoid.

Received: 09 May 2020

Accepted: 21 October 2020

Type of Article: CASE REPORT

Specialty: Pathology

Correspondence to: Ioannis Provatat

*Locum Pathologist, Department of Pathology, Athens General Hospital “O Evangelismos”, Athens, Greece.

Email: iannispro@yahoo.co.uk

Full list of author information is available at the end of the article.

Background

Giant cell tumors are neoplasms met commonly in bones. In contrast, extrasosseous giant cell tumors involving visceral organs (pancreas, kidneys, bladder, breast, thyroid, parotid, colon, skin, mediastinum, heart) and soft tissues are very rare and present similar histological features to those occurring in the bones. Adenocarcinoma of the pancreas is a common gastrointestinal malignancy accounting for most of the patients with pancreatic masses [1], whereas the Giant cell tumors involving the pancreas are very rare, representing less than 1% of non-endocrine pancreatic tumors [2]. The origin of this kind of tumor remains still controversial, with some authors supporting the epithelial and some others the mesenchymal origin. Nevertheless, in the latest WHO classification of Digestive System Tumors, the term “osteoclastic giant cell carcinoma” is considered an accepted term for the undifferentiated carcinoma with osteoclast-like giant cells [3]. Giant cell tumor of the pancreas usually affects patients in the 6th to 7th decade of life, with an equal male to female ratio [4]. Pancreatic giant cell tumors (PGCTs) mostly involve the body and tail of the

pancreas, unlike pancreatic adenocarcinoma which mainly involves the head. Morphologically, they are usually cystic lesions of significant size with associated hemorrhage and necrosis. In this study, we report the case of a pancreatic giant cell tumor with osteoclast-like cells, negative for epithelial markers.

Case Presentation

A 64-year-old man presented with a 2-month history of progressively worsening abdominal pain, radiating to the lumbar region. He reported no vomiting; diarrhea, or fever, and no precipitating factors were identified. The abdominal clinical examination was unremarkable and there was no associated jaundice. Liver function tests remained within normal limits. His past medical history had nil of note.

He underwent an outpatient abdominal computed tomography (CT) which revealed a large cystic lesion at the body of the pancreas measuring 10 × 7 × 6.5 cm which appeared to be compressing rather than invading

the adjacent structures. There were septa within the cystic component of the lesion. Imaging identified no ascites or distant metastasis, and the patient was referred to our Surgical Department for further management.

Laboratory values at admission were as follows; hemoglobin = 9.2, Glucose = 159, Bilirubin = 1.54, c-reactive protein = 1.77, carcinoembryonic Antigen (CEA) = 2.08, CA19-9 = 7.42.

The size of the lesion on preoperative imaging was suggestive of malignancy; therefore, we proceeded to an exploratory laparotomy with a view to resection. The mass itself was encapsulated and could be dissected free from the remaining pancreatic tissue. Inside the cystic component, there was some dark red fluid and necrotic debris. However, intraoperatively, extensive retroperitoneal disease was identified. There were large lymphatic blocks encircling the celiac vessels, small volume of diaphragmatic disease, and a distinct retroperitoneal mass. Since the disease was unresectable, we proceeded with a limited excision of the pancreatic mass alone, avoiding major dissections that would unnecessarily increase morbidity and mortality.

The patient's postoperative course was complicated with a retroperitoneal bleed that required a laparotomy and washout on day 7. He made an uneventful recovery on the Ward after that.

Macroscopically, the resected surgical specimen consisted of an oval-shaped mass measuring 11.6 × 7.4 × 6.9 cm, with an irregular surface. The interior of the mass showed an extended cystic degeneration, containing multiple cystic spaces, with variably thick elastic/sclero-elastic walls, filled with dark red hemorrhagic material. At the periphery of the neoplasm, pancreatic tissue was recognized, retaining its normal lobular architecture. The surgical specimen was formalin-fixed, and the obtained sections were embedded in paraffin, to be processed according to routine tissue protocol and to be studied using common hematoxylin-eosin stain.

Histologically, the tumor was composed of two cell types: osteoclast-like multinucleated giant cells and pleomorphic mononuclear cells, without important cellular and nuclear atypia. The stroma between these cells was fibrotic, with prominent bone and osteoid formation, at the edge of which quite a lot of the multinucleated giant cells were attached. (Figures 1-4) Also, there were a lot of hemosiderin-laden histiocytic aggregations. The mitotic count was low (checked also with Phospho-Histone H3 antibody), ranging to 3-4 mitoses / 10 high resolution visual fields (×400). The remaining segment of pancreatic parenchyma did not show important lesions.

Immunohistochemically, the osteoclast-like multinucleated giant cells were positive for cluster differentiation (CD)68 (Figure 6) and negative for cytokeratin (CK) AE1/AE3 (Figure 5) CK7, CK20, epithelial membrane

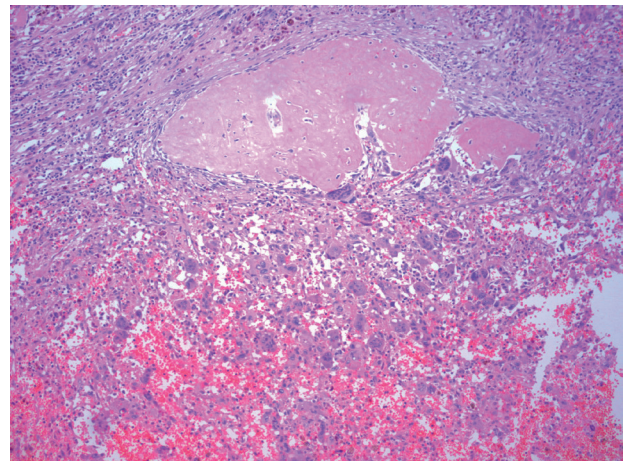


Figure 1. Giant cells with osteoid - bone formation, hematoxylin - eosin ×10.

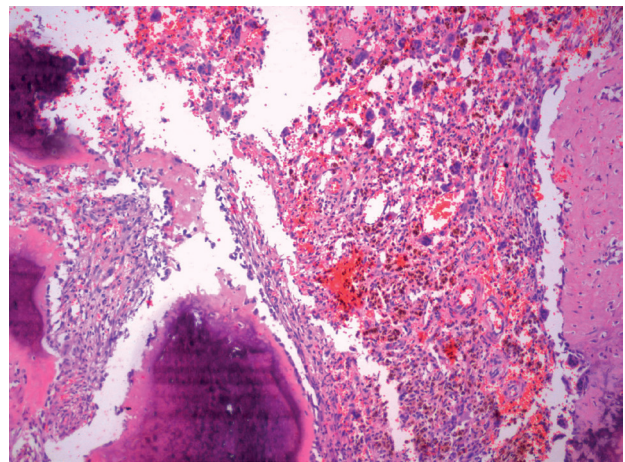


Figure 2. Giant cells with bone formation, hematoxylin - eosin ×10.

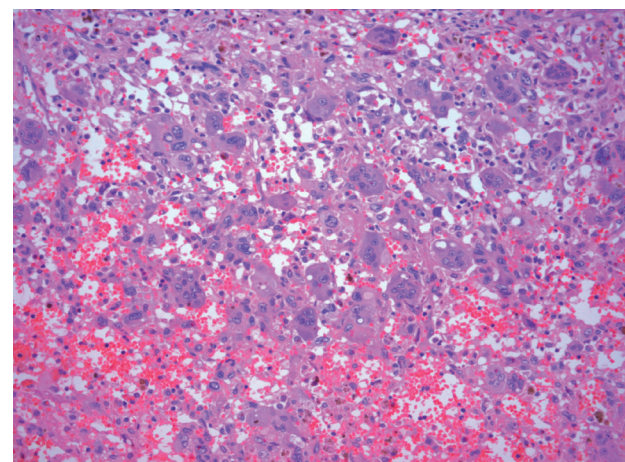


Figure 3. Tumor giant cells, hematoxylin - eosin ×20.

antigen (EMA), p53, CEA, CD34, Actin, Desmin, and Mucicarmine. Fibrous tissue was positive for Vimentin. The cell proliferation rate Ki-67 was relatively low (~10%). The surgical resection margins of the specimen were free of tumor. Based on the above findings, the diagnosis of osteoclastic giant cell tumor of the pancreas was established.

Discussion

It was Rosai [5] that first reported a pancreatic giant cell neoplasm, followed by Alguacil - Garcia, and Weiland with a similar publication [6]. Giant cell tumors present usually in the bones. The primary site of such tumors has been described in various other organs such as the gallbladder, urinary bladder, lungs, breast, etc.; however, the pancreas appears to have a greater affinity for such lesions. Irrespective of their location, the morphological characteristics are similar.

PGCTs are exceedingly rare. They were firstly described by Sommers and Meissner, and they were classified in three types: osteoclastic, pleomorphic, and mixed. WHO has grouped them under the name “undifferentiated carcinoma with osteoclast-like giant cells”, although, their origin and biological behavior remains unclear, given their rarity.

Although there are few reported cases in the literature, pancreatic osteoclastic giant cell tumors usually present in the sixth to seventh decade of life. Both sexes are affected equally. Predominant symptoms are mild abdominal pain and unintentional weight loss. Jaundice due to malignant obstruction may also be present. The above rare lesions tend to be of significant size, with a diameter greater than 5 cm in most cases. Acute pancreatitis can also be the first presentation of an occult pancreatic malignancy [7]. The underlying pathophysiologic mechanism is either obstruction of the pancreatic duct or direct parenchymal invasion. There is a single report of a pancreatic osteoclastic giant cell tumor presenting with recurrent acute pancreatitis and persistent hyperamylasemia [8].

The giant cell containing neoplasms of the pancreas have certain similar macroscopic features besides their large size. PGCTs mostly involve the body and tail of the pancreas, unlike pancreatic adenocarcinoma which mainly involves the head. Most of the described cases have a cystic component and are multiloculated [9]. The diagnosis of these tumors in pancreatic tissue is established through morphological and immunohistochemical examination. Based on WHO Classification, undifferentiated carcinomas with osteoclast-like giant cells, otherwise osteoclastic giant cell carcinoma, should contain three distinct cell types: non-neoplastic osteoclast-like multinucleated giant cells, a mononuclear histiocytic component and neoplastic mononuclear cell population. They may be graded based on the system proposed by the Netherlands Committee on Bone Tumors and taking in consideration the number and the proportion of osteoclastic giant cells and the background cells [10]. However, in our case, the tumor contained osteoclastic multinucleated giant cells and minimally atypical pleomorphic histiocytes, positive for CD68 and negative for epithelial markers, proving their histiocytic origin.

The differential diagnosis of osteoclastic giant cell tumors included pancreatic anaplastic carcinoma, mucinous

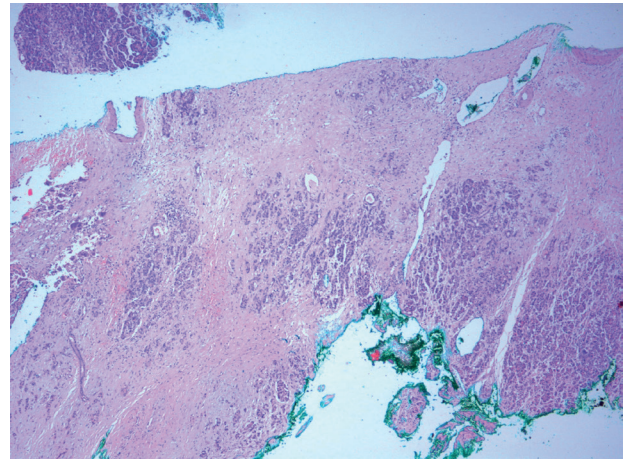


Figure 4. Surgical margins, hematoxylin - eosin $\times 4$.

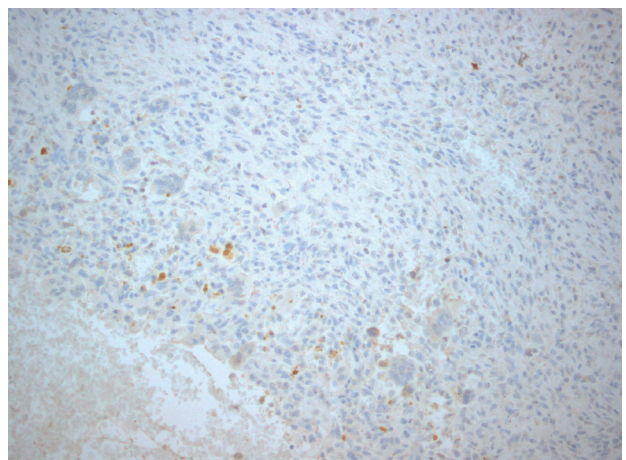


Figure 5. Immunohistochemistry, CKAE1/AE3 $\times 10$.

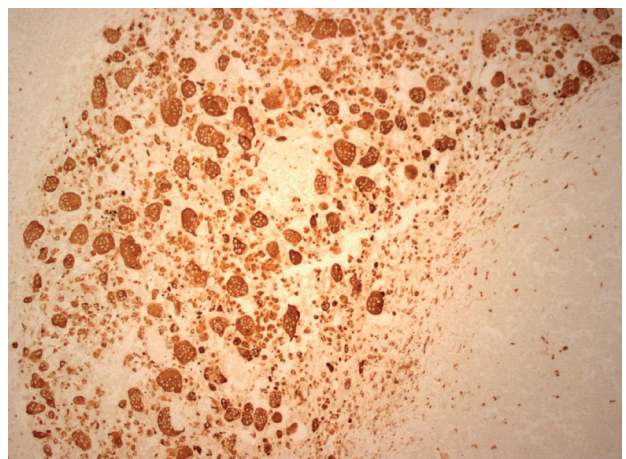


Figure 6. Immunohistochemistry, CD68 $\times 10$.

cystic neoplasms, undifferentiated pleomorphic sarcoma (malignant fibrous histiocytoma) with giant cells, leiomyosarcoma, and metastatic bone sarcoma. Pancreatic anaplastic carcinoma was excluded, as it shows carcinomatous areas with glandular/tubular/acinar differentiation, focally positive for cytokeratins and EMA. The same, mucinous cystic neoplasms were excluded because

there was no epithelial component showing glandular - mucinous morphology and differentiation and no tumor cell was positive for cytokeratins, CEA, and mucicarmine. Undifferentiated pleomorphic sarcoma with giant cells was not finally considered, as the tumor showed prominent malignant osteoid formation being CD34 negative. There was no evident smooth muscle differentiation suggesting that the tumor could correspond to a leiomyosarcoma, a fact that was confirmed by the negative actin and desmin immunohistochemical stains. The possibility of metastatic bone sarcoma was excluded by the clinical picture and the laboratory findings.

Although isolated reports of these tumors have been increasing over the last decade, its clinical course is still obscure. Recent studies have indicated that these tumors have a more protracted course relative to the conventional invasive pancreatic ductal adenocarcinoma with greater resectability. Togawa et al. [11] reported the primary tumor to be resectable in 88% of the reviewed cases. The liver and regional lymph nodes appear to be the predominant site for metastasis. En bloc resection of adjacent organs was also needed for giant tumors to achieve free surgical margins. Shiozawa et al. [12] reported the mean survival at 20.4 months.

Due to the rarity of the tumor, adjuvant treatment options have not been adequately evaluated. Bauditz et al. [13] reported their results with palliative chemotherapy; a combination of cisplatin, etoposide and ifosfamide. They only achieved partial remission. In our literature search, we encountered two reports on adjuvant chemotherapy with gemcitabine and one report of adjuvant radio-chemotherapy. Patients survived free of recurrence, thus, highlighting the clinical significance of resection. To correlate the clinical response to treatment with histopathological features, Nai et al. [14] suggested that adjuvant radiotherapy might be more appropriate for patients with pancreatic Osteoclastic giant cell tumors (OGCTs) of mesenchymal differentiation who may have anyway better prognosis, whereas chemotherapy might be more suitable for patients who have Pancreatic OGCTs of predominant epithelial differentiation.

Conclusion

Pancreatic giant cell tumors with osteoclast-like giant cells are rare tumors of the pancreas with various clinical characteristics and controversial origin. En bloc resection has prevailed as the only beneficial treatment so far, since the role of adjuvant or neo-adjuvant chemotherapy or radiotherapy, has not been yet clearly clarified [15]. Prognosis of the Pancreatic OGCTs seems to be more favorable than that of the usual ductal pancreatic carcinomas, especially in resectable cases; however, surgery with curative intent may not always be feasible as some patients have already developed the metastatic disease at the time of diagnosis.

What is new?

Giant cell tumors involving soft tissues and visceral organs are very rare tumors. Their origin remains to be clarified. In our case all morphological and immunohistochemical findings support the mesenchymal origin.

List of Abbreviations

CD	Cluster Differentiation
CEA	Carcinoembryonic Antigen
CK	Cytokeratin
EMA	Epithelial membrane antigen
OGCT	Osteoclastic giant cell tumor
PGCT	Pancreatic giant cell tumor

Funding

None.

Conflict of interests

The authors declare that there is no conflict of interests regarding the publication of this case report.

Consent for publication

Written informed consent was taken from the patient.

Ethical approval

Ethical approval is not required at our institution for publishing an anonymous case report.

Author details

Ioannis Provatas¹, Dimitrios Sabaziotis¹, Chryssa Stamou¹, Georgia Mitropoulou², Helen Trihia³

1. Department of Pathology, Athens General Hospital "O Evangelismos", Athens, Greece
2. Department of Pathology, Athens Children s Hospital Agia Sofia, Athens, Greece
3. Department of Pathology, Cancer Hospital of Piraeus Metaxa, Piraeus, Greece

References

1. Espey DK, Wu XC, Swan J, Wiggins C, Jim MA, Ward E, Wingo PA, et al. Annual report to the nation on the status of cancer, 1975–2004, featuring cancer in American Indians and Alaska Natives. *Cancer*. 2007;110(10):2119–52. <https://doi.org/10.1002/cncr.23044>
2. Loya AC, Ratnakar KS, Shastry RA. Combined osteoclastic giant cell and pleomorphic giant cell tumor of the pancreas: a rarity. An immunohistochemical analysis and review of the literature. *JOP*. 2004;5:220–4.
3. WHO Classification of Tumours Editorial Board. Digestive system tumours. 5th ed. In: Chapter 8, Tumours of the liver and intrahepatic bile ducts. Geneva, Switzerland: World Health Organization; 2019. pp 322–30.
4. Rustagi T, Rampurwala M, Rai M, Golioto M. Recurrent acute pancreatitis and persistent hyperamylasemia as a presentation of pancreatic osteoclastic giant cell tumor: an unusual presentation of a rare tumor. *Pancreatol*. 2011;11(1):12–5. [https://doi.org/10.1016/S1424-3903\(11\)80012-8](https://doi.org/10.1016/S1424-3903(11)80012-8)
5. Rosai J. Carcinoma of the pancreas simulating giant cell tumor of the bone. Electron - microscopic evidence of its acinar cell origin. *Cancer*. 1968; 22:333–4. [https://doi.org/10.1002/1097-0142\(196808\)22:2<333::AID-CN-CR2820220210>3.0.CO;2-A](https://doi.org/10.1002/1097-0142(196808)22:2<333::AID-CN-CR2820220210>3.0.CO;2-A)

6. Alguacil-Garcia A, Weiland L. The histologic spectrum, prognosis and histogenesis of the sarcomatoid carcinoma of the pancreas. *Cancer*. 1977;39:1181–9. [https://doi.org/10.1002/1097-0142\(197703\)39:3<1181::AID-CNCR2820390325>3.0.CO;2-T](https://doi.org/10.1002/1097-0142(197703)39:3<1181::AID-CNCR2820390325>3.0.CO;2-T)
7. Gambill EE. Pancreatitis associated with pancreatic carcinoma: a study of 26 cases. *Mayo Clin Proc*. 1971;46:174–7.
8. Kohler H, Lankish PG. Acute pancreatitis and hyperamylasemia in pancreatic carcinoma. *Pancreas*. 1987;2(1):117–9.
9. Scott R, Jersky J, Hariparsad G: Case report: malignant giant cell tumor of the pancreas presenting as a large pancreatic cyst. *Br J Radol*. 1993;66:1055–7. <https://doi.org/10.1259/0007-1285-66-791-1055>
10. Muraki T, Reid MD, Basturk O, Jang K-T, Bedolla G, Bagci P, et al. Undifferentiated carcinoma with osteoclastic giant cells of the pancreas: clinicopathological analysis of 38 cases highlights a more protracted clinical course than currently appreciated. *Am J Surg Pathol*. 2016;40(9):1203–16. <https://doi.org/10.1097/PAS.0000000000000689>
11. Togawa Y, Tonouchi A, Chiku T, Sano W, Doki T, Yano K, et al. A case report of undifferentiated carcinoma with osteoclast-like giant cells of the pancreas and literature review. *Clin J Gastroenterol*. 2010;3(4):195–203. <https://doi.org/10.1007/s12328-010-0160-2>
12. Shiozawa M, Imada T, Ishiwa N, Rino Y, Hasuo K, Takanashi Y, et al. Osteoclast-like giant cell tumor of the pancreas. *Int J Clin Oncol*. 2002;7(6):376–80. DOI: 10.1007/s101470200059.
13. Bauditz J, Rudolph B, Wermke W. Osteoclast-like giant cell tumors of the pancreas and liver. *World J Gastroenterol*. 2006;12:7878–83. <https://doi.org/10.3748/wjg.v12.i48.7878>
14. Nai GA, Amico E, Gimenez VR Osteoclast-like giant cell tumor of the pancreas with ductal adenocarcinoma. Case report and discussion of the histogenesis. *Pancreatol*. 2005;5(2–3):279–84. <https://doi.org/10.1159/000085283>
15. Abid H, Gnanajothy R (May 21, 2019). Osteoclast giant cell tumor of pancreas: a case report and literature review. *Cureus*. 11(5): e4710. <https://doi.org/10.7759/cureus.4710>

Summary of the case

1	Patient (gender, age)	Male, 64 years old
2	Final diagnosis	Osteoclastic Giant Cell Tumor of Pancreas
3	Symptoms	Two-month history of progressively worsening abdominal pain, radiating to the lumbar region
4	Medications	-
5	Clinical procedure	Surgical Resection
6	Specialty	Pathology