

A rare case of fibrous pseudotumor of the epididymis treated with testis-sparing surgery

European Journal of Medical Case Reports

Volume 6(9):160–164

<https://doi.org/10.24911/ejmcr/173-1643731465>



This is an open access article distributed in accordance with the Creative Commons Attribution (CC BY 4.0) license: <https://creativecommons.org/licenses/by/4.0/> which permits any use, Share — copy and redistribute the material in any medium or format, Adapt — remix, transform, and build upon the material for any purpose, as long as the authors and the original source are properly cited. © The Author(s) 2022

Luca Topazio^{1*} , Federico Romantini¹, Daniela Biferi¹, Federico Narcisi¹, Luigi Grasso¹, Pietro Morgia¹

ABSTRACT

Background: Paratesticular fibrous pseudotumors are rare benign intrascrotal lesions that can often mimic malignancy. They often arise in the scrotal tunic while less common localizations are the epididymis and the spermatic cord. Their diagnosis is challenging and often done post-operatively on definitive histopathology; for this reason, they are often treated with orchietomy which results in overtreatment.

Case Presentation: We present a case of a 42-year-old male patient that came to our observation for scrotal swelling. Physical exam and ultrasound showed a healthy testis but multiple painless, tender, oval lesions at the level of the epididymis. Laboratory tests and testicular markers were within normal limits, thus we planned explorative surgery with frozen sections that excluded malignancy. We performed testis-sparing surgery with epididymectomy, vasectomy, and resection of the tunica vaginalis. Definitive histopathology revealed a fibrous pseudotumor. To date, at 3 months follow-up, the patient is in good clinical condition with no signs of recurrence and with healthy homolateral testis.

Conclusion: Fibrous pseudotumor can mimic malignancy. A correct diagnosis is pivotal to choosing the correct treatment and avoiding aggressive surgery.

Keywords: Benign testicular neoplasm, paratesticular fibrous pseudo-tumor, benign fibrous paratesticular tumor, testis-sparing treatment. inflammatory pseudotumor.

Received: 01 February 2022

Accepted: 22 November 2022

Type of Article: CASE REPORT

Specialty: Urology

Correspondence to: Luca Topazio

*MD, Department of Urology, Mazzini Hospital, Teramo, Italy.

Email: luca.topazio@aslteramo.it

Full list of author information is available at the end of the article.

Background

Paratesticular fibrous pseudotumors are rare lesions that grow mainly in and between the testicular envelopes, and less commonly in the epididymis and the spermatic cord [1]. They are benign fibroproliferative lesions and were described for the first time in 1904, by Balloch [2] that named them fibromata. Although fibrous pseudotumors are uncommon, they are reported to be the second most common benign paratesticular lesion after adenomatoid tumors [3]; even so, they only comprise 6% of paratesticular lesions [4] but epididymal involvement is apparent in less than 10% of cases of fibrous pseudotumor [5].

The pathogenesis of the mass is highly debatable and not well understood. Mostofi [6] found a history of trauma or epididymo-orchitis in 30% of cases but in many other cases, a history of trauma is difficult to establish. Sajjad et al. [7] also thought that a relationship with an inflammatory process (epididymitis, previous surgery, infected hydrocele, trauma, etc.) is probably the most likely etiological factor.

Fibrous pseudotumor can often mimic genito-urinary malignancies and the correct diagnosis is challenging and

depends, in the vast majority of cases, on post-operative histopathology. Because of their similarity to malignant lesions, their treatment is often carried out surgically by orchietomy, thus resulting in a huge overtreatment.

Only a few cases have been reported worldwide [8] and just two cases have been previously reported in the literature in our country [9,10]. We describe a case of a 42-year-old male patient diagnosed with a fibrous pseudotumor of the epididymis and treated conservatively with testis-sparing surgery.

Case Presentation

A 42-year-old male came to our observation for a painless intra-scrotal mass. The patient had noticed the mass several years before, but he had not sought urological consultation in the past; because of a worsening in volume in the last weeks and worried about a possible malignancy, he had decided to undergo a medical evaluation. No previous scrotal trauma or genito-urinary inflammation was recorded. The family's and patient's past medical history were normal and the patient was not on medical therapy.

Physical examination showed a normal homolateral testis and absence of hydrocele while at the level of the epididymis (especially at the head and body) we observed multiple, painless nodular, well delimited, oval structures of about 2 to 4 cm in diameter each.

Ultrasound (US) examination showed a normal testis and, at the level of the epididymis, multiple hypoechoic lesions closely associated with the capsule of the testis with a substantial amount of calcifications and no significant vascularity. The cleavage between the testis and the epididymis was visible in the US.

Laboratory investigations and testicular markers resulted within normal limits; thus, we planned explorative surgery with a frozen section.

Intraoperatively, the homolateral testis was healthy and it was not affected by the lesions, but it was completely surrounded by multiple tender tan white oval nodules deriving from the epididymis and, in minor part, from the tunica vaginalis (Figure 1a and b). We performed multiple frozen sections of the nodules and thus we ruled out malignancy; therefore, we decided to proceed by performing a testis-sparing surgery with epididymectomy, vasectomy, and resection of the tunica vaginalis (Figures 2 and 3). A drain was left in place for 12 hours and removed on post-operative day 1. The early post-operative period was uneventful, and the patient was discharged from the hospital on post-operative day 1.

The histopathology revealed a “reactive connective tissue neoplasm with hypocellular hyaline fibrous tissue proliferation with collagen bands and few inflammatory chronic lymphocytic infiltrations. No necrosis or mitosis were identified” (Figure 4) and defined that lesion as a paratesticular fibrous pseudotumor.

To date, at 3 months follow-up, the patient is in good clinical condition with no signs of relapse or late complications. On physical examination and US evaluation, the homolateral testis is healthy with no signs of vascular distress. A comprehensive timeline of the case can be found in Figure 5.

Discussion

Every intrascrotal swelling is presumed to be a malignant tumor until proven otherwise; in the majority of cases, the lesions are indeed malignant testicular neoplasms that account for about >95%-98% of diagnoses while paratesticular neoplasms are rare and often benign. The most frequent paratesticular neoplasms are adenomatoid tumors and cystadenomas, but, although uncommon, fibrous pseudotumors are reported to be the second most common diagnosis among paratesticular lesions; Williams et al. [4] reported a study of 114 paratesticular neoplasms and found seven cases of fibrous pseudotumor; only 10% of these tumors were found in the epididymis and spermatic cord.

Paratesticular fibrous pseudotumors were described for the first time in 1904, by Balloch [2] that named them

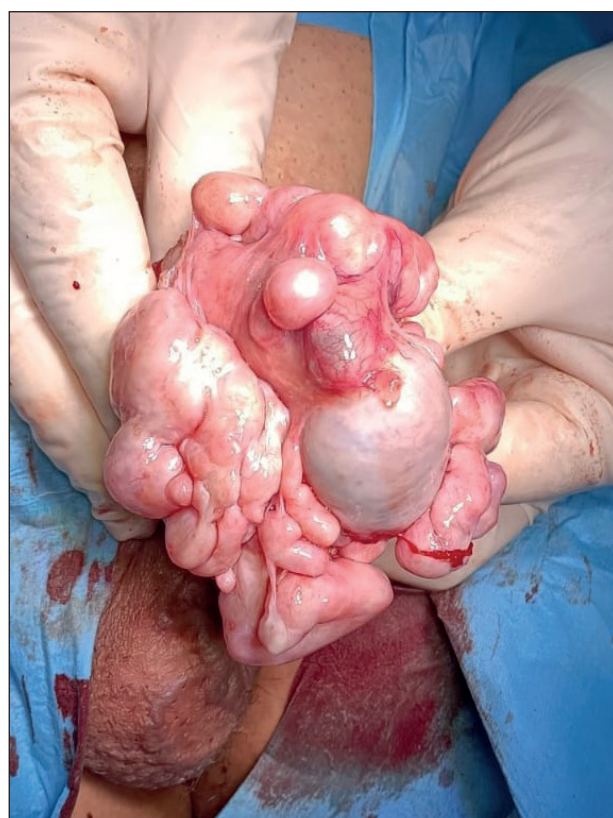
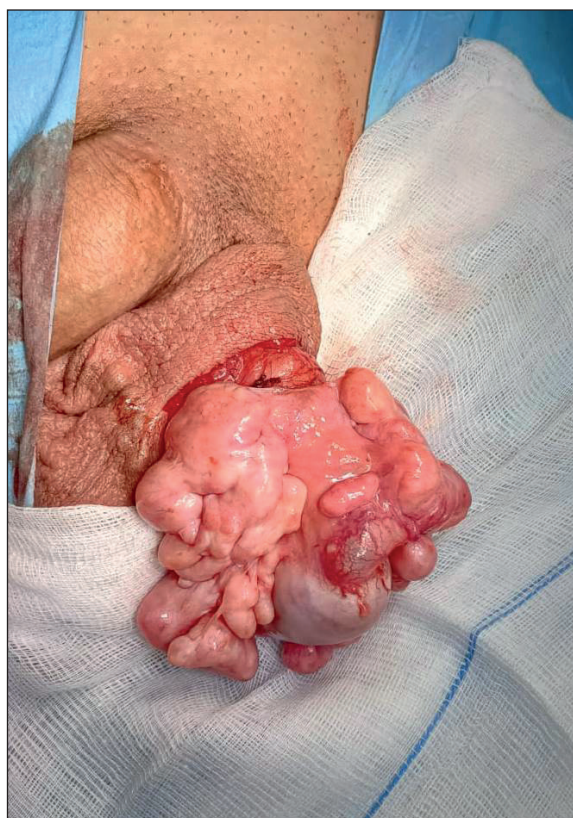
Figure 1. (a, b) Intra-operative view of the lesions.

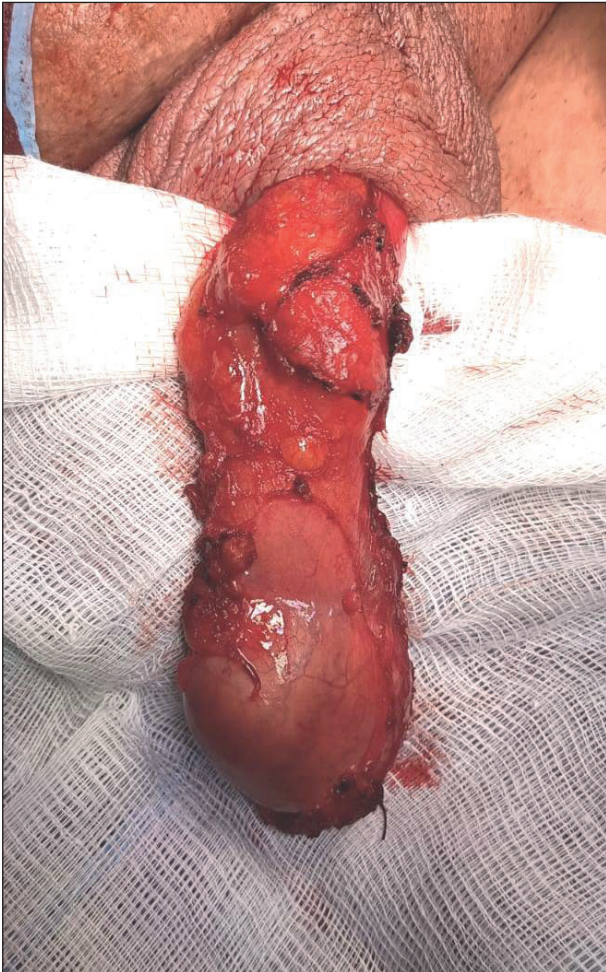

Figure 2. Homolateral testis and spermatic cord at the end of the procedure.

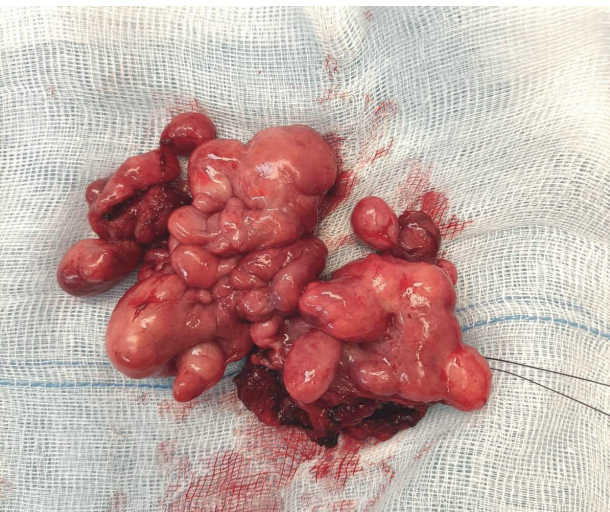

Figure 3. Epididymis affected by fibrous pseudotumor.

“fibromata”; in 1936, Thompson [11] published an extensive review on this subject while in 1963 Gibson [12] tried to classify the paratesticular tumors into those arising from the tunica vaginalis testis and those arising from the tunica albuginea testis. In 1997, Jones et al. [13] proposed a new

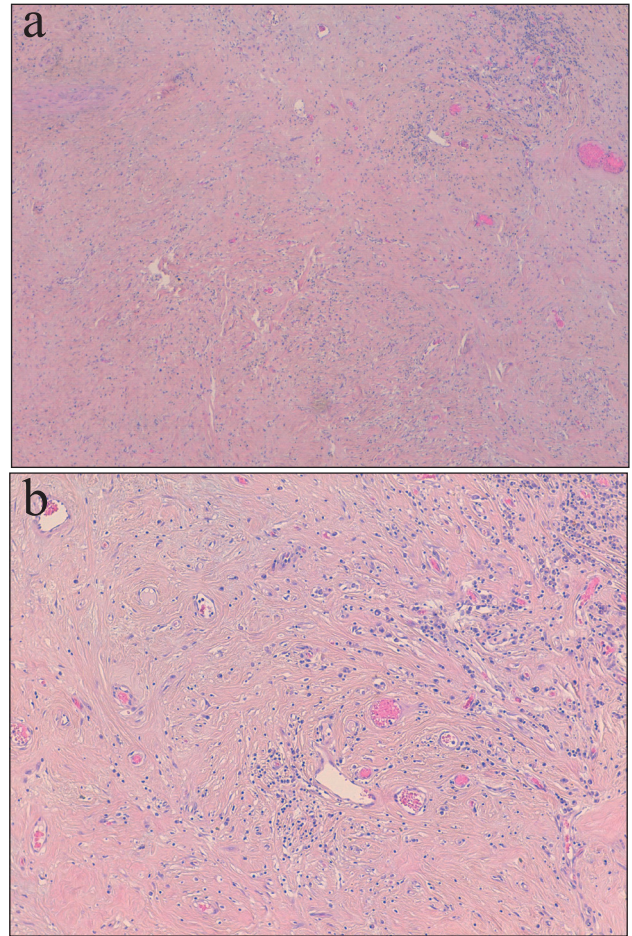


Figure 4. (a and b) Microscopic view of the lesions.

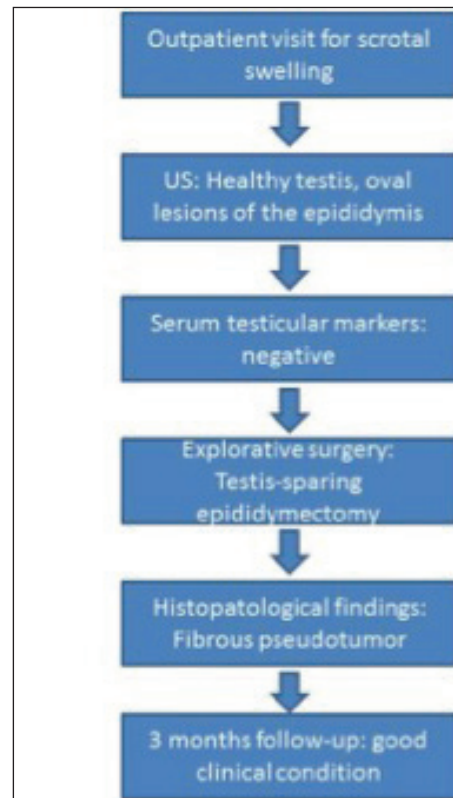

Figure 5. Timeline of the case.

classification aimed to standardize anatomic-pathologic findings based on their 9-case experience. They classified benign fibromatous testicular and paratesticular proliferations into four categories: angiomyofibroblastoma, fibromas of testicular tunics, fibromas of gonadal stromal origin, and fibroblastic/myofibroblastic pseudotumors (fibrous pseudotumors and pseudosarcomatous pseudotumors).

Many designations for these lesions had been considered synonyms and include the following: chronic proliferative periorchitis, inflammatory pseudotumor, nodular and diffuse fibrous proliferation, proliferative funiculitis, fibromatous periorchitis, fibroma, benign fibrous paratesticular tumor, fibrous mesothelioma, pseudofibromatous periorchitis, nonspecific peritesticular fibrosis, and reactive periorchitis. In 1973, Mostofi and Price [5] have included all of these proliferations under the term fibrous pseudotumor to encompass all reactive fibroinflammatory lesions of the testicular tunics.

Macroscopically, the tumors are multiple, tan-white, nodular, well-delimited, oval, and mobile structures with tissue that grossly appears thick. Their dimensions may range from a few millimeters to 8-10 cm and they may be associated with diffuse fibrosis of the testicular tunic. Usually, they derive from the tunics while in rare cases they originate from the spermatic cord or epididymis.

Under microscopic examination, fibrous tissue, spindle cells, plasma cells, and lymphocytes are commonly present, sparse in number, and engulfed within a keloid-like collagen. Histologic staining will identify multiple fibroblasts, intermixed with a few inflammatory cells in dense fibrous tissue, an apparent product of myofibroblastic proliferation. Immunohistochemical staining of the fibrous pseudotumor is highly positive for vimentin, smooth muscle-specific actin, and common muscle actin. The pseudotumor is negative for S-100, keratin, and desmin. Necrosis and increased areas of mitosis and pleomorphism, features that would suggest malignancy, also will not be evident within the fibrous mass [14].

Fibrous pseudotumor has been reported in all age groups with a peak incidence in the third decade of life and the pathogenesis is due to a reactive fibrous inflammatory hyperplasia, which is a likely response to trauma, surgery, infection, or inflammatory hydrocele; rarely schistosoma haematobium infection has also been associated with fibrous pseudotumor [15].

Paratesticular fibrous pseudotumor diagnosis and treatment are very challenging; the right diagnosis is often dependent on post-operative histology, and this could lead to pre-operative misdiagnosis and choice of a not well appropriate treatment; indeed, the vast majority of fibrous pseudotumor cases are victims of overtreatment because of orchiectomy. This could represent a huge problem, especially for patients in their fertile age. Misdiagnosis is often caused by the lack of frozen sections and by the use of a normal testicular cancer work-up in such

patients (physical exam, testicular markers, and CT scan). Therefore, overtreatment is always caused either by misdiagnosis or by lack of feasibility of conservative surgery.

In our case, the pre-operative US and physical exam showed a normal testis with only the epididymis involved; moreover, the US revealed a good cleavage between the testis and the epididymis. Thus, in consideration of the age of the patient and having in mind the normal results of the testicular work-up, we decided not to go for orchiectomy but to plan explorative surgery in the hope of being able to spare the testis. Frozen sections permitted us to rule out malignancy and to perform conservative surgery with epididymectomy and vasectomy.

In our opinion, a good clinical work-up of rare intra-scrotal tumors is pivotal and must consist of a physical exam; US and testicular markers as the very first step; as the second passage, in case of the normal appearance of the testis and paratesticular location of the lesions, explorative surgery and frozen sections must be planned. Only a good work-up can help us to rule out malignancy, thus permitting conservative surgery and avoiding overtreatment.

In our view, this article shows several points of interest:

It describes a rare intrascrotal tumor. To date, less than 60 papers have been published on PubMed on this issue, most of which from eastern countries, while in our national database, just two papers have been found on a PubMed search [9,10];

It describes a rare location of fibrous pseudotumor. As already stated, paratesticular pseudotumors very often derive from the scrotal tunic while rarely they arise from the epididymis and the spermatic cord [4];

It describes a satisfying diagnostic work-up of the lesion that permitted a conservative surgery. Most of the papers analyzed make a misdiagnosis and treat fibrous pseudotumor in an aggressive manner as for malignancy; a correct diagnostic workup with the use of frozen sections allows to rule out malignancy and carry out conservative surgery.

Conclusion

Paratesticular fibrous pseudotumors are rare and their diagnosis and treatment are challenging. Frozen sections are of utmost importance to exclude malignant lesions and the correct diagnosis is pivotal to avoid surgical overtreatment.

What is new?

This case report is about a rare benign paratesticular tumor (fibrous pseudotumor). A few cases have been reported in the literature and just two papers have been published in our country. This article is interesting because it describes a rare location at the epididymis and it shows a good diagnostic work-up aimed to avoid misdiagnosis and overtreatment.

List of Abbreviations

US Ultrasound

Conflict of interest

The authors declare no conflict of interest regarding the publication of this article.

Funding

None.

Consent for publication

Written informed consent to publish this case was obtained from the patient.

Ethical approval

Ethical approval is not required at our institution to publish an anonymous case report.

Author details

Luca Topazio¹, Federico Romantini¹, Daniela Biferi¹, Federico Narcisi¹, Luigi Grasso¹, Pietro Morgia¹

1. MD, Department of Urology, Mazzini Hospital, Teramo, Italy

References

1. Srigley JR, Hartwick RW. Tumors and cysts of the paratesticular region. *Pathol Annu*. 1990;25 Pt 2:51–108.
2. Balloch EA. IX. Fibromata of the tunica vaginalis. *Ann Surg*. 1904;39(3):396–402. <https://doi.org/10.1097/00000658-190403000-00009>
3. Oliva E, Young RH. Paratesticular tumor-like lesions. *Semin Diagn Pathol*. 2000;17(4):340–58.
4. Williams G, Banerjee R. Paratesticular tumours. *Br J Urol*. 1969;41(3):332–9. <https://doi.org/10.1111/j.1464-410X.1969.tb11893.x>
5. Mostofi FK, Price EB. Tumors of the male genital system. Washington, DC: AFIP; 1973.
6. Mostofi FK. Proceedings: testicular tumors. Epidemiologic, etiologic, and pathologic

- features. *Cancer*. 1973;32(5):1186–201. [https://doi.org/10.1002/1097-0142\(197311\)32:5<1186::AID-CNCR2820320527>3.0.CO;2-8](https://doi.org/10.1002/1097-0142(197311)32:5<1186::AID-CNCR2820320527>3.0.CO;2-8)
7. Sajjad SM, Azizi MR, Llamas L. Fibrous pseudotumor of testicular tunic. *Urology*. 1982;19(1):86–8.
8. Bösmüller H, von Weyhern CH, Adam P, Alibegovic V, Mikuz G, Fend F. Paratesticular fibrous pseudotumor--an IgG4-related disorder? *Virchows Arch*. 2011;458(1):109–13. <https://doi.org/10.1007/s00428-010-0995-4>
9. Miscia ME, Cecinati V, Fusillo M, Persico A, Lauriti G, Lisi G, et al. Paratesticular fibrous pseudotumor in children: a case report and review of literature. *J Pediatr Hematol Oncol*. 2019; 41(5):404–6. <https://doi.org/10.1097/MPH.0000000000001274>
10. Leone L, Fulvi P, Sbröllini G, Filosa A, Caraceni E, Marronaro A, et al. Rare presentation of a testicular angiofibroma treated with testis sparing surgery. *Arch Ital Urol Androl*. 2016;88(4):330–2. <https://doi.org/10.4081/aiaa.2016.4.330>
11. Thompson GJ. Tumours of the spermatic cord and epididymis. *Surg Gynec Obstet*. 1936;62:712.
12. Gibson TE. Tumors of the seminal vesicles, spermatic cord, epididymis and testicular tunics. In *Urology*, Saunders, Philadelphia, PA; 1963. pp 1284–314. Vol. 2.
13. Jones MA, Young RH, Scully RE. Benign fibromatous tumors of the testis and paratesticular region: a report of 9 cases with a proposed classification of fibromatous tumors and tumor-like lesions. *Am J Surg Pathol*. 1997;21(3):296–305. <https://doi.org/10.1097/00000478-199703000-00005>
14. Seethala RR, Tirkes AT, Weinstein S, Tomaszewski JE, Malkowicz SB, Genega EM. Diffuse fibrous pseudotumor of the testicular tunics associated with an inflamed hydrocele. *Arch Pathol Lab Med*. 2003;127(6):742–4. <https://doi.org/10.5858/2003-127-742-DFPOTT>
15. Ugras S, Yesil C. Fibrous pseudotumors of tunica albuginea, tunica vaginalis and epididymis: report of two cases. *Cancer Epidemiol*. 2009;33(1):69–71. <https://doi.org/10.1016/j.canep.2009.03.002>

Summary of the case

1	Patient (gender, age)	Male, 42 years old
2	Final diagnosis	Reactive connective tissue neoplasm with hypocellular hyaline fibrous tissue proliferation with collagen bands and few inflammatory chronic lymphocytic infiltration. No necrosis or mitosis was identified (Figures 3 and 4) and defined lesion as a paratesticular fibrous pseudotumor.
3	Symptoms	Scrotal swelling
4	Medications	none
5	Clinical procedure	Scrotal exploration with frozen sections
6	Specialty	Urology