

Dumbbell shaped giant intramuscular pelvic lipoma: a rare cause of sciatic nerve compression

Rohit Jindal^{1*}, Pinakin Patel¹, Suresh Singh¹, Arpita Jindal²

European Journal of Medical Case Reports

Volume 6(8):144–146

<https://doi.org/10.24911/ejmcr/173-1654726166>



This is an open access article distributed in accordance with the Creative Commons Attribution (CC BY 4.0) license: <https://creativecommons.org/licenses/by/4.0/> which permits any use, Share — copy and redistribute the material in any medium or format, Adapt — remix, transform, and build upon the material for any purpose, as long as the authors and the original source are properly cited. © The Author(s) 2022

ABSTRACT

Background: Lipoma is a common benign mesenchymal tumor that is typically located in the subcutaneous tissue and rarely symptomatic. Sciatica can be a result of various etiologies but a giant intramuscular pelvic lipoma causing sciatic nerve compression is rare, with not more than 10 cases reported so far in the literature.

Case Presentation: We report a case of a 36-year-old female who presented with a complaint of gradually worsening sciatica for 6 months. Magnetic resonance imaging showed a large well-defined intramuscular dumbbell-shaped mass in the right gluteal region, herniating through the sciatic foramen into the pelvis. After successful resection of the mass transabdominally, the histopathological examination confirmed the diagnosis of a benign lipoma. The patient improved gradually thereafter and is asymptomatic since then.

Conclusion: Our case not only describes the appropriate diagnosis and surgical management of this common benign entity with a rare location and even rarer clinical presentation but also creates a paradigm for future insight into the effective management of such a patient.

Keywords: Pelvic lipoma, dumbbell shaped, sciatica, intramuscular, liposarcoma.

Received: 08 June 2022

Accepted: 28 October 2022

Type of Article: CASE REPORT

Specialty: General Surgery

Correspondence to: Rohit Jindal

*Senior Resident, Department of Surgical Oncology, Sawai Man Singh Medical College and Hospital, Jaipur, India.

Email: doc_rj24@yahoo.com

Full list of author information is available at the end of the article.

Background

A lipoma is a benign encapsulated indolent tumor of adipose tissue with unknown etiology. Out of all the tumors arising from the adipose tissue, 94% are lipomas, 4.7% are lipoblastomas, and 1.7% are liposarcomas [1]. A lipoma seldom grows more than 2 cm in size and is called a giant lipoma when the diameter exceeds 10 cm [2]. The usual site of lipomas is the subcutaneous tissue and rarely they are found in deeper tissues. A pelvic lipoma is usually presacral in location and can extend toward the inguinal region or in the perineum through the sciatic foramen, the obturator foramen, or the pelvic floor [2]. To the best of our knowledge, not more than 10 cases of pelvic giant lipoma have been reported to date [3]. Sciatic nerve pain, also called lumbar radiculopathy, is a very disabling disorder for the patient. It is not so uncommon, with various etiologies that include spinal trauma, lumbar disc herniation, lumbar spinal stenosis, spinal tumors, or even rarely, a dumbbell-shaped pelvic tumor traversing through the sciatic foramen and thereby causing sciatic nerve compression. We report a case of a female who presented with gradually worsening sciatica for 6 months owing to a dumbbell-shaped giant intramuscular pelvic lipoma which

is not only infrequently described in the literature but also both a clinical conundrum and a surgical challenge.

Case Presentation

A 36-year-old female was admitted with a complaint of pain in the right lower limb for 6 months which was gradually increasing in intensity. Also, recently she suffered from constipation for the past 1 month. The past history and medical history were unremarkable. A general physical examination revealed nothing significant but mild hypertension. No abnormality was detected on the abdominal examination. However, on digital rectal examination, a smooth non-tender mass could be felt in the right ischio-rectal fossa. On raising the right leg straight, the patient experienced sharp excruciating pain, which aggravated dorsiflexion at the hip joint, thus indicating the pain to be of sciatic nerve compression. The rest of the neurological examination was completely normal.

Routine workup included several blood investigations which revealed a normal complete blood count, renal function test, liver function test, and coagulation profile. Magnetic Resonance Imaging (MRI) of the pelvis was

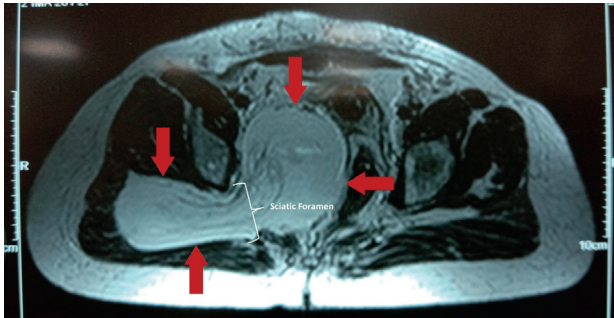


Figure 1. Magnetic resonance imaging of the pelvis (axial section) showing a large well defined intramuscular lesion in the right gluteal region which is seen traversing the sciatic foramen into the pelvis, thus giving it the appearance of a dumbbell (red arrows).

done which showed a well-defined intramuscular slightly heterogeneous fat-intensity lesion in the right gluteal region which was seen extending into the pelvis via the sciatic foramen (Figure 1). The pelvic component measured $9.5 \times 7.7 \times 8.8$ cm which had a mass effect resulting in the rectum being displaced laterally and the uterus anterolaterally. The appearance of the mass lesion was characteristically dumbbell-shaped.

An ultrasound-guided core biopsy of the mass lesion was planned to reach the diagnosis, which revealed a benign soft tissue lipoma. Thereafter under general anesthesia, successful resection of the mass lesion was done using the midline transabdominal approach without injuring the sciatic nerve (Figure 2). The mass lesion was encapsulated with only a few adhesions at the foramen sciatica. The histopathological examination of the resected specimen confirmed the diagnosis of a benign lipoma, as mature adipocytes were seen arranged in layers, separated by fibrous septa on hematoxylin and eosin staining, without any evidence of atypia, pleomorphism, lipoblasts, or mitotic figures (Figure 3). Subsequent to surgery, she recovered gradually and was discharged in healthy condition. The patient improved symptomatically gradually on follow-up and is now asymptomatic after 1 year of follow-up with regular pelvic ultrasonographic

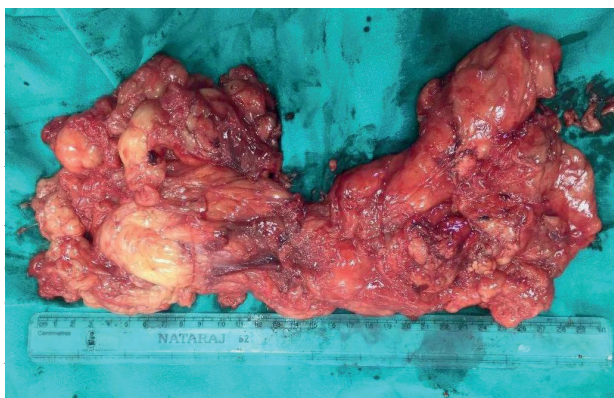

Figure 2. The large resected dumbbell-shaped fatty tumor.

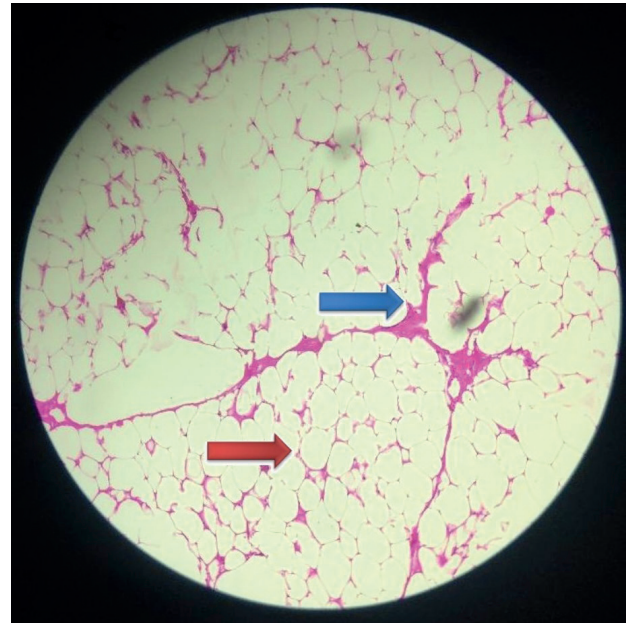


Figure 3. Hematoxylin and eosin staining at 20x magnification showing sheets of mature adipocytes (red arrow) separated by fibrous septa (blue arrow).

However, the involvement of peripheral nerves by soft tissue tumors including lipoma is very uncommon [4,5]. MRI is the best investigation to diagnose soft tissue tumors. A lipoma appears homogenous and hyperintense in T1 and T2 weighted images. In our case, the tumor primarily involved the gluteus muscle on the right side, then traversed through the sciatic foramen into the pelvis, thus giving rise to a dumbbell appearance. Small asymptomatic lipomas can be managed conservatively, but a giant lipoma with mass effect has to be invariably resected surgically. Complete resection remains the treatment of choice with a high risk of recurrence associated with incomplete resections. Incomplete resection is associated with a 2%-5% recurrence rate [2]. Therefore, regular follow-up after surgery shall be a rule, particularly if it was an incomplete resection.

Conclusion

MRI is the benchmark investigation as it not only aids in the precise diagnosis of the soft tissue tumor but also delineates the surrounding vital structures such as the sciatic nerve. A well-differentiated liposarcoma also presents imaging characteristics similar to a benign lipoma because both lesions consist of large amounts of fat tissue (more than 75%) [6]. Preoperative biopsy, if done, will help to differentiate a lipoma from its malignant counterpart, especially a well-differentiated liposarcoma, and thus guide future surgical planning. Complete resection of the tumor by a single transabdominal approach is difficult but possible, thus avoiding unnecessary additional morbidity. Complete resection of the tumor not only alleviates the symptoms but also prevents recurrence.

What is new?

This case not only covers essential information regarding the rare presentation of a rare entity, which is giant pelvic lipoma but also creates a paradigm for future insight into the effective management of such a patient. MRI is the benchmark investigation as it not only aids in the precise diagnosis of the soft tissue tumor but also delineates the surrounding vital structures such as the sciatic nerve. Preoperative biopsy, if done, will help to differentiate a lipoma from its malignant counterpart, especially a well-differentiated liposarcoma, and thus guide future surgical planning. Complete resection of the tumor by a single transabdominal approach is difficult but possible, thus avoiding unnecessary additional morbidity.

Acknowledgments

None.

List of Abbreviation

MRI Magnetic resonance imaging.

Conflict of interest

The authors declare that there is no conflict of interest regarding the publication of this Case Report.

Funding

None.

Consent for publication

Written informed consent was obtained from patient.

Ethical approval

Ethical approval is not required at our institution to publish an anonymous case report.

Author details

Rohit Jindal¹, Pinakin Patel¹, Suresh Singh¹, Arpita Jindal²

1. Senior Resident, Department of Surgical Oncology, Sawai Man Singh Medical College and Hospital, Jaipur, India
2. Department of Pathology, Sawai Man Singh Medical College and Hospital, Jaipur, India

References

1. Gardikis S, Kambouri K, Tsalkidis A, Chatzimicael A, Vaos G. Lipoblastoma on the posterior side of the neck. *Turk J Pediatr*. 2009;51(3):287–9.
2. Verdin V, Preud'Homme L, Lemaire V, Jacquemin D. Giant dorsal lipoma. *Rev Med Liege*. 2009;64(7–8):414–7.
3. Dhouha B, Maroua W, Seifeddine B, Ghofrane T, Lassaad G, Rached B, et al. Lipome géant pelvien mimant un liposarcome [Giant pelvic lipoma mimicking a liposarcoma]. *Pan Afr Med J*. 2019;33:20. <https://doi.org/10.11604/pamj.2019.33.20.15008>
4. Flores LP, Carneiro JZ. Peripheral nerve compression secondary to adjacent lipomas. *Surg Neurol*. 2007;67(3):258–62. <https://doi.org/10.1016/j.surneu.2006.06.052>
5. Kim DH, Murovic JA, Tiel RL, Moes G, Kline DG. A series of 146 peripheral non-neural sheath nerve tumors: 30-year experience at Louisiana State university health sciences center. *J Neurosurg*. 2005;102(2):256–66. <https://doi.org/10.3171/jns.2005.102.2.0256>
6. Hansch A, Gajda M, Boettcher J, Pfeil A, Kaiser WA. Incomplete paresis of the sciatic nerve due to massive atypical lipoma of the pelvis: a case report. *Cases J*. 2008;1(1):296. <https://doi.org/10.1186/1757-1626-1-296>

Summary of the case

1	Patient (gender, age)	Female, 36 years old
2	Final diagnosis	Giant intramuscular pelvic lipoma
3	Symptoms	Pain in right lower limb; constipation
4	Medications	Analgesics
5	Clinical procedure	Transabdominal resection
6	Specialty	Oncology, general surgery, neurology, neurosurgery