

# Role of radiological imaging techniques in the diagnosis of scrotal cystocele; a case report

Muhammad Qasim Khan<sup>1\*</sup>, Nayab Alia<sup>1</sup>,  
Muhammad Babar Imran<sup>2</sup>, Adeela Abid<sup>1</sup>

European Journal of Medical Case Reports

Volume 6(7):131–138

<https://doi.org/10.24911/ejmcr/173-1658315728>



This is an open access article distributed in accordance with the Creative Commons Attribution (CC BY 4.0) license: <https://creativecommons.org/licenses/by/4.0/> which permits any use, Share — copy and redistribute the material in any medium or format, Adapt — remix, transform, and build upon the material for any purpose, as long as the authors and the original source are properly cited. © The Author(s) 2022

## ABSTRACT

**Introduction:** The condition known as scrotal cystocele occurs when the urinary bladder slides through the inguinal canal and fills the scrotum. It is a rare condition that typically affects obese male patients between the ages of 50 and 70. Massive scrotal cystocele in men younger than 45 or in the pediatric population is uncommon. Most people with scrotal cystocele are asymptomatic or present with the typical two-phase micturition with intermittent swelling that goes down after voiding.

**Presentation of the case:** We present the case of a 44-year-old obese man who visited the radiology department with unusual symptoms, such as urinary frequency, urgency, nocturia, and suprapubic pain, along with scrotal enlargement. He was diagnosed as having a large scrotal cystocele based on his clinical history and radiological findings.

**Discussion:** Rarely, reported cases include massive scrotal cystocele and left-sided ureter herniation. Preoperative diagnosis of IBH is important to lessen postoperative complications.

**Conclusion:** Ultrasound, computed tomography intra-venous urogram (IVU), fluoroscopic cystography, antegrade IVU, and single-photon emission computerized tomography aid to diagnose the scrotal cystocele or mimicking inguinal metastasis on bone scan.

**Keywords:** Scrotal cystocele, inguinal bladder hernia (IBH), “Chiragh”-like sign, Mery sign, inguinal metastasis, fluoroscopic cystography, antegrade IVU, CT-IVU, SPECT-CT, herniorrhaphy.

Received: 20 July 2022

Accepted: 02 September 2022

Type of Article: CASE REPORT

Specialty: Diagnostic Radiology

Correspondence to: Muhammad Qasim Khan

\*Department of Diagnostic Radiology, Madinah Teaching Hospital, Faisalabad, Pakistan.

Email: [muhammad.qasimk@gmail.com](mailto:muhammad.qasimk@gmail.com)

Full list of author information is available at the end of the article.

## Background

There are many causes of the enlarged scrotum, one of which is herniated urinary bladder (UB) sliding into it. Massive scrotal cystocele or inguinal bladder hernia (IBH; herniation of UB through the inguinal canal and filling the scrotum) is a rare entity [1] and diagnosed incidentally during hernia repair or imaging studies [2]. In addition to being rare, it may be misdiagnosed as an inguinoscrotal hernia [3]. IBH accounts for only 0.5%-4% of all inguinal hernias [1,4,5]. A large scrotal cystocele along with left-sided pelvic ureter herniation is an extremely rare event [4].

IBH can be partial which is usually asymptomatic or complete in which the entire UB herniates into the scrotum and the patient completes two-stage micturition (manual compression of the scrotum to empty the bladder) [5,6]. A large scrotal cystocele may cause genitourinary malignancy [7]. 7% of IBH are diagnosed pre-operatively, and 16% are diagnosed post-operatively likely due to leakage of urine from wounds, the rest are diagnosed intra-operatively [8]. Current recommendations are the resection of the urinary bladder if it has diverticulum, incidental

bladder tumor, bladder necrosis, or hernias neck less than 5 mm [5,7]. The important risk factors of scrotal cystocele are body mass index (BMI) > 30, past pelvic surgery, obstructive bladder disease (prostatic hypertrophy, urethral strictures), and bladder wall disease [4]. Large scrotal cystocele has been reported in infants [9]. Females are also affected by this condition, but males are 10 times more affected [1].

The ultrasound (USG) is the initial modality for any scrotal swelling [10]. Computed tomography intra-venous urogram (CT-IVU), fluoroscopic cystography, antegrade IVU, and single-photon emission computerized tomography (SPECT-CT) may help to diagnose the massive scrotal cystocele or mimic inguinal metastasis on bone scan [1,2,11,12].

This case study aimed to show a unique anatomical variation that a radiologist or nuclear physician can come across while investigating a scrotal swelling or routine fluorodeoxyglucose-positron emission tomography (FDG-PET) and bone scan. Despite this fact, it's crucial to

know the hernial sac contents pre-operatively to prevent any serious complications during surgery.

### Case Presentation

We report the case of a 44-year-old male referred to the radiology department for sonographic evaluation of left-sided scrotal swelling. The patient had scrotal swelling for 6 months with complaints of painful micturition, urinary frequency, nocturia, and incomplete emptying. The swelling regressed on manual compression of the scrotum while voiding. However, it didn't vanish completely after urination.

On physical examination, his BMI was found to be 35 kg/m<sup>2</sup>, with no swelling in the abdomen or bilateral inguinal regions. Left-sided hemiscrotum was grossly enlarged, non-tender, and approximately measured 10 × 8 cm. Patient had no urinary complaints before the development of swelling. He had no previous relevant history or surgery. Blood samples didn't show any abnormality. A digital rectal examination (DRE) was not done.

Scrotal and abdominal ultrasonography revealed a well-defined anechoic cystic lesion in the left hemiscrotum (Figures 1 and 5) The wall of the lesion was measuring 1.7 mm and tapering cranially into the left inguinal canal forming a “Chiragh”-like sign (Figures 4 and 5) The intra-abdominal bladder measured 5.7 × 2.8 cm, tapering left laterally into the inguinal canal and showed communication with scrotal anechoic cystic lesion through a neck measuring 9.9 mm (Figure 3). The testes were displaced

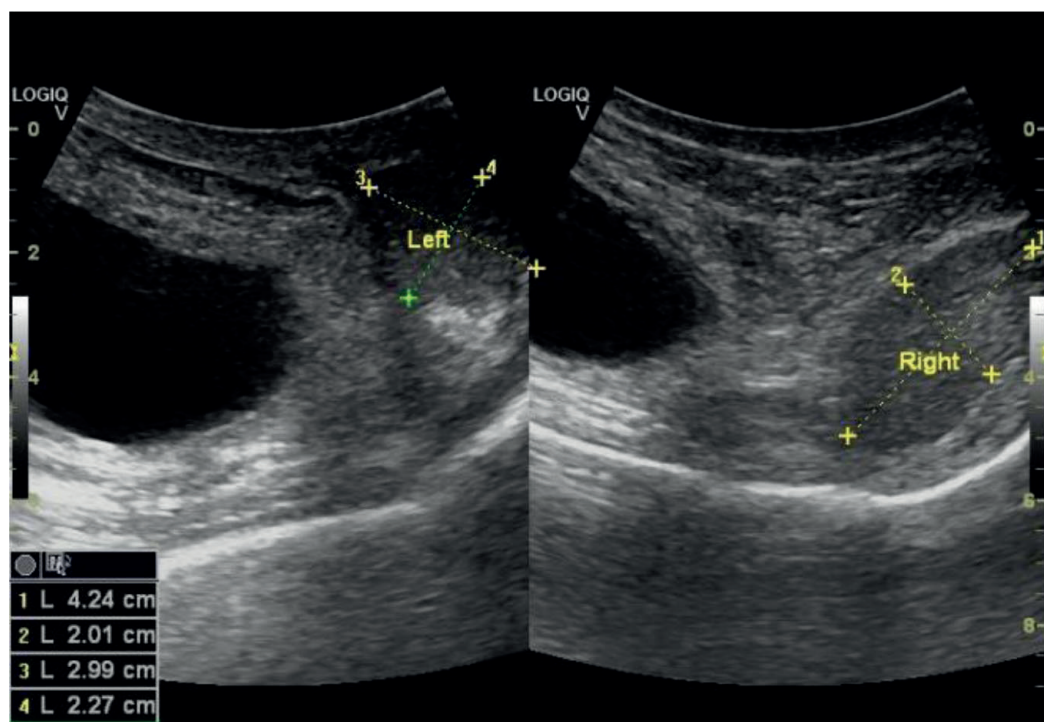
laterally due to the mass effect of the lesion, however, the echotexture and the size of the testes were normal. The penile shaft was above the lesion (Figure 2). Left-sided kidney showed grade 2 hydronephrosis and dilated tortuous proximal ureter. The right-sided kidney was unremarkable. The post-void volume after two-stage micturition was 5 ml in the intra-abdominal part of the UB. There was a reduction in scrotal swelling. But the herniated bladder is not completely emptied. These findings were in favor of scrotal cystocele. But confident diagnosis alone on ultrasonography is difficult and may misdiagnose the condition.

To ascertain the cause of hydronephrosis, fluoroscopic IVU and retrograde cystography were done that showed a dumbbell-shaped UB herniated through the left inguinal region along with the left distal ureter into the scrotum (Figure 6 a-c).

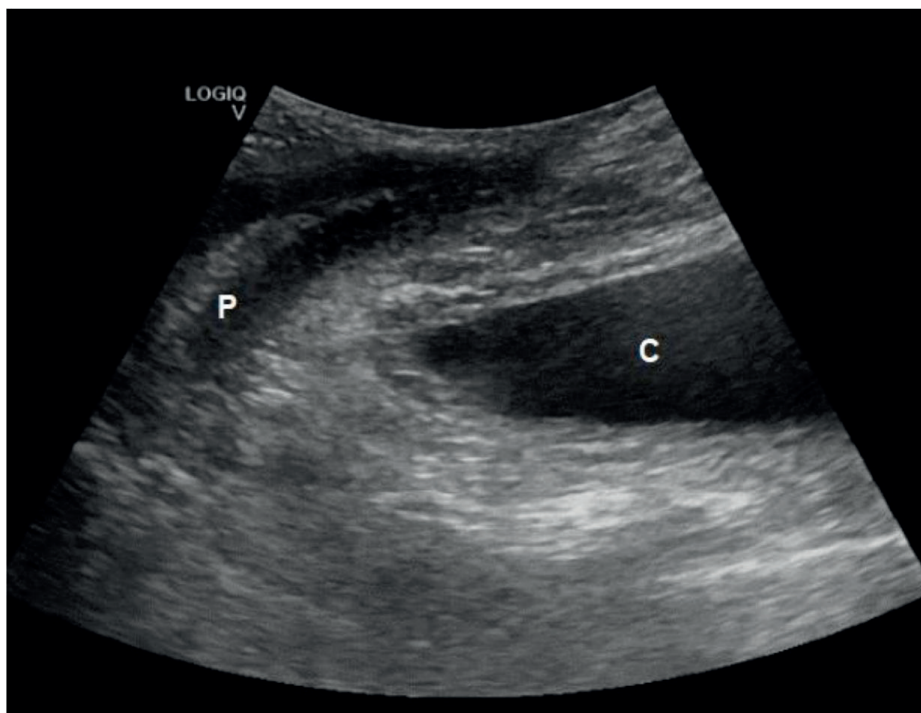
There was associated left-sided moderate hydronephrosis and kinked hydroureter (Figure 7).

No filling defect or trabeculations were seen in the kidneys and UB (Figures 6b and 7). The findings likely showed acute or subacute conditions.

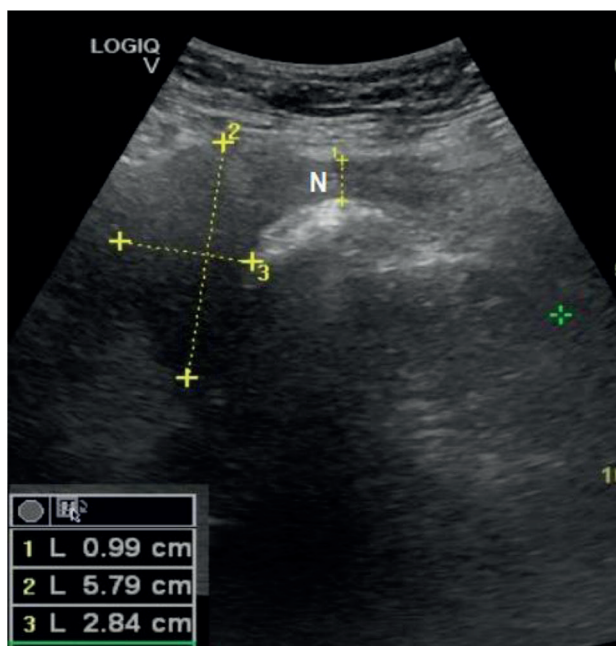
To see any associated complications like necrosis of the UB, CT-IVU was done, which showed grade-2 left-sided hydronephrosis (not shown in the figure) and kinked hydroureter (Figures 10 and 12a and b). Plain and delayed urography showed the bulk of the UB along with the left-sided distal ureter herniated through the inguinal region into the left hemiscrotum (Figures 9-11). No signs of



**Figure 1.** Anechoic cystic lesion displacing both testes laterally.

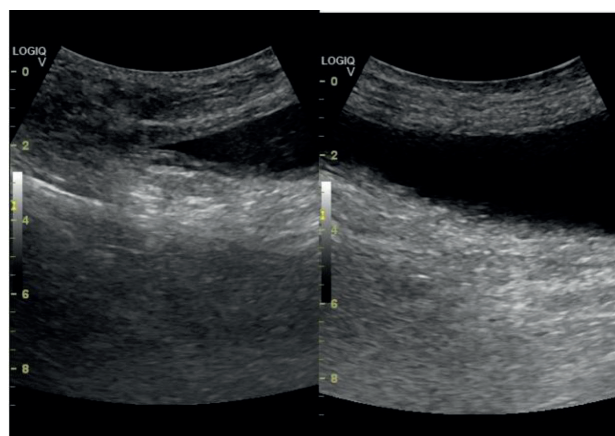


**Figure 2.** Anechoic cystic lesion (C) below the penile shaft (P) showed a thick wall of the lesion.



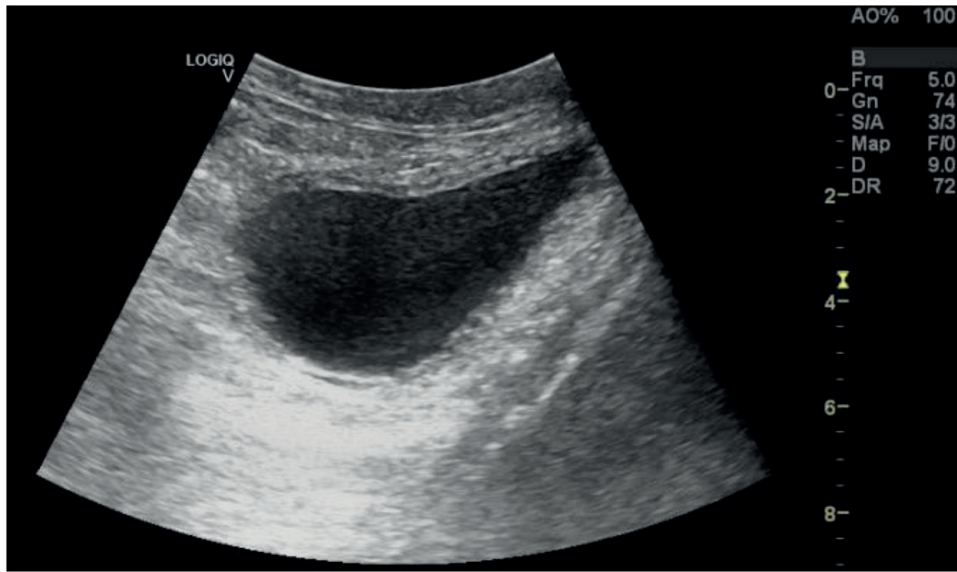
**Figure 3.** Intra-abdominal part of urinary bladder (5.7 × 2.8 cm) and hernia neck (N) measuring 9.9 mm.

UB necrosis, gut herniation, or dilatation were seen. CT scout image or plain abdominal CT (not shown in the figure) didn't show any renal or UB calculus (Figures 8 and 9). Maximum intensity projection (MIP) images of CT showed the herniation of the bladder along with the left-sided ureter in 3D format (Figure 12a and b).

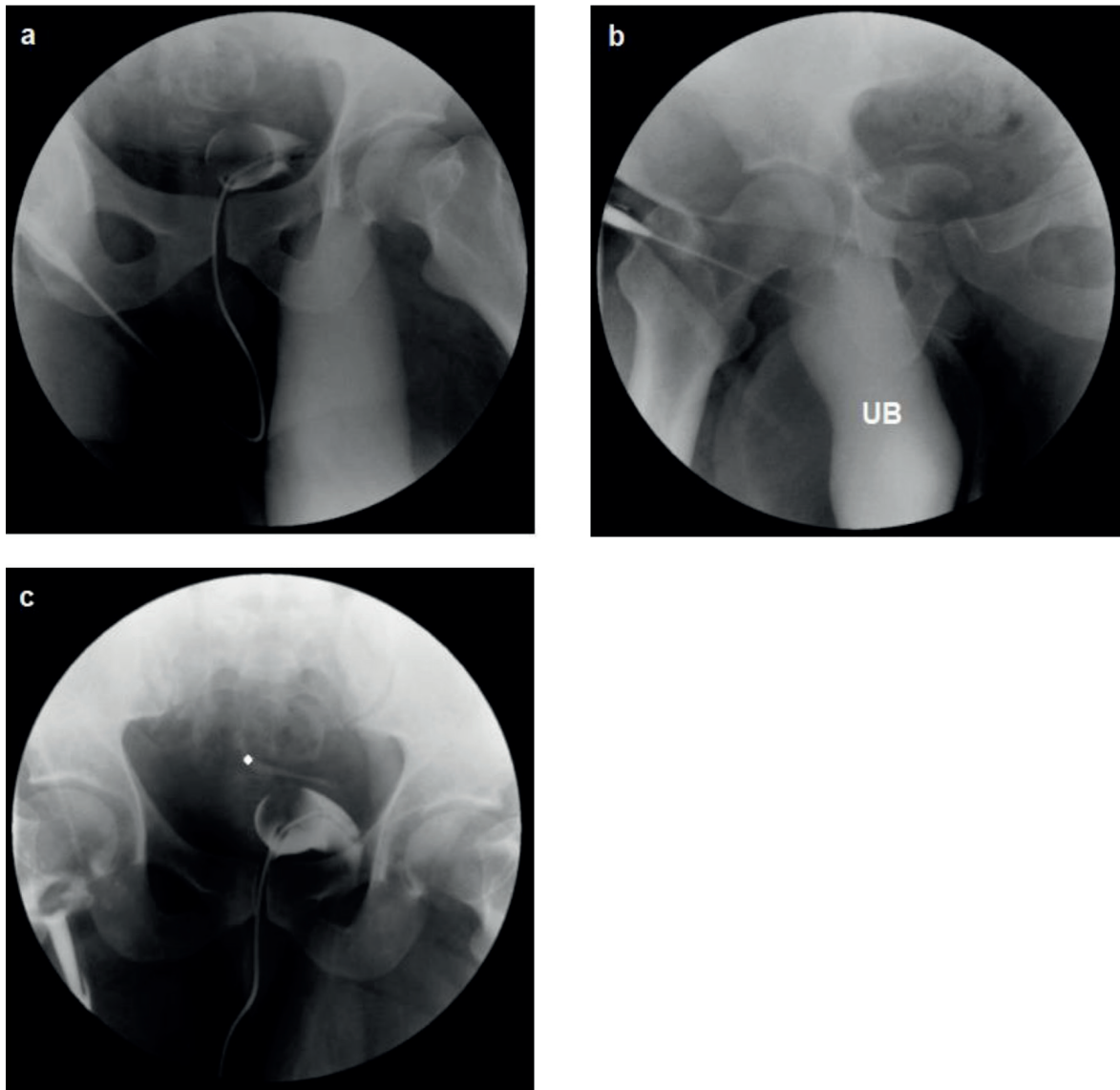


**Figure 4.** Anechoic cystic lesion superior end tapering into left inguinal.

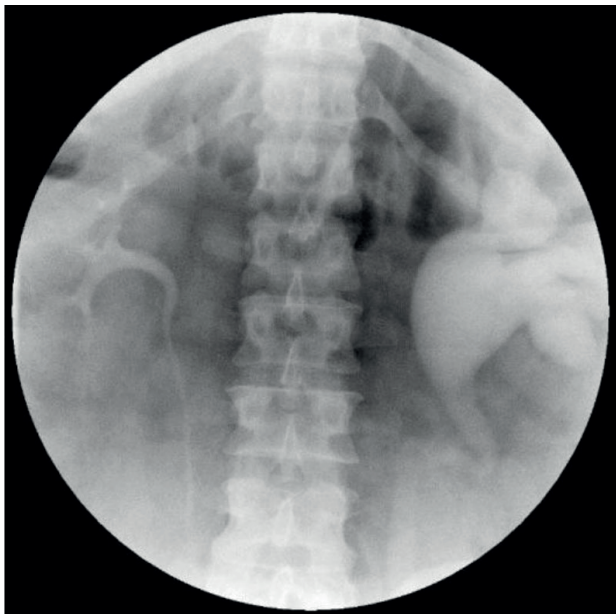
Elective surgery was decided. During surgery, the bladder was seen herniated into the scrotum through the posterior wall of the abdomen. The bladder was carefully reduced back to the pelvis and the defect of the posterior wall of the abdomen was closed with proline one sutures (herniorrhaphy). The surgery was uneventful and the patient was discharged on the fourth post-op day. He came back on the 14th day. Follow-up USG showed mild left-sided hydrocele likely reactionary. No reherniation of the UB was seen. The patient's symptoms of urinary frequency, urgency, nocturia, suprapubic pain, and two-stage micturition were also relieved.



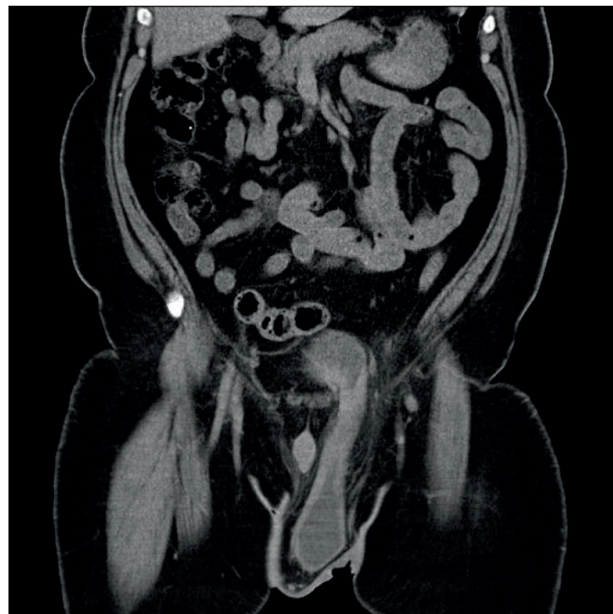
**Figure 5.** Anechoic cystic lesion forming a “Chiragh”-like sign, having well defined wall measuring 1.7 mm (measurement not shown).



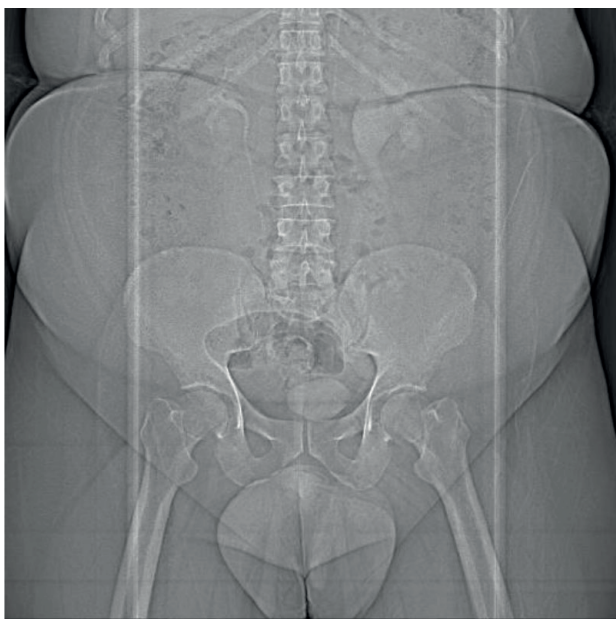
**Figure 6.** (a and b) Retrograde cystography showed dumbbell shaped UB herniation through left inguinal region and (c) left distal ureter herniation (the white dot).



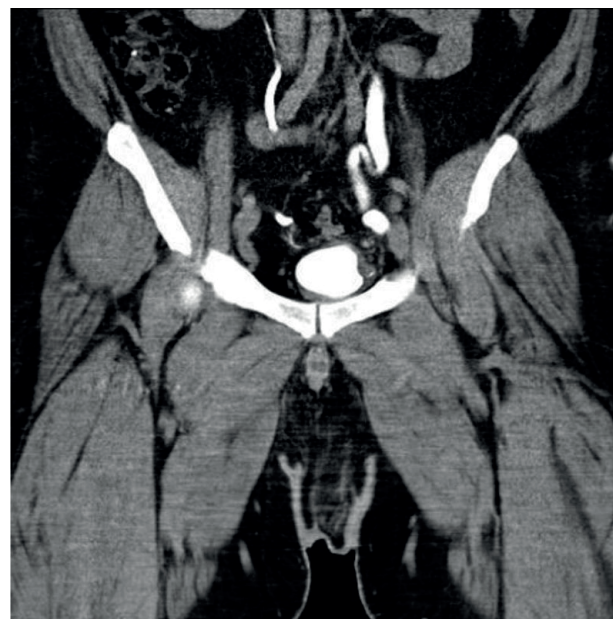**Figure 7.** IVU showed left-sided moderate hydronephroureter.



**Figure 9.** Plain CT showed UB herniation into the scrotum.



**Figure 8.** CT scout image showed no renal or UB calculus.



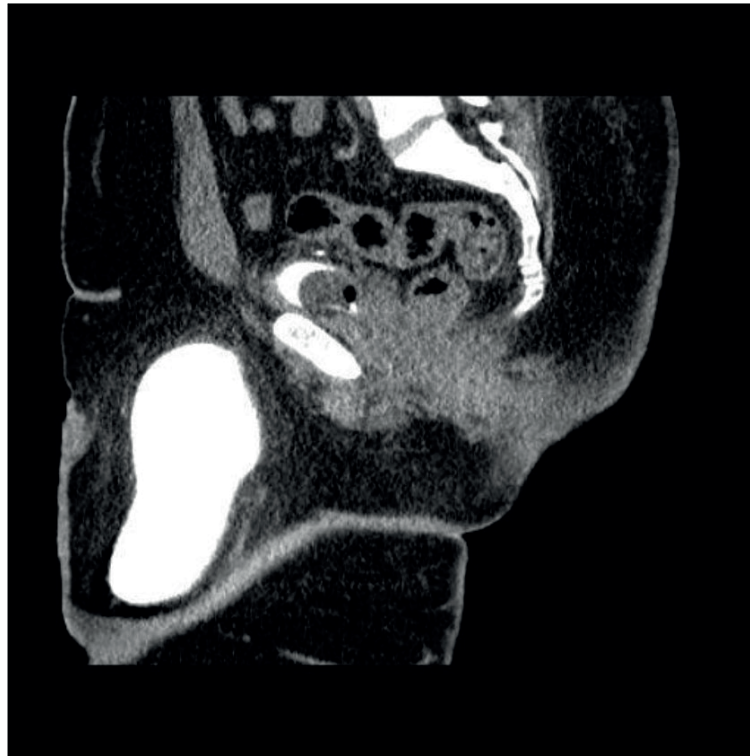
**Figure 10.** Delayed CT-IVU; left-sided ureter is dilated and herniated into the left inguinal region.

## Discussion

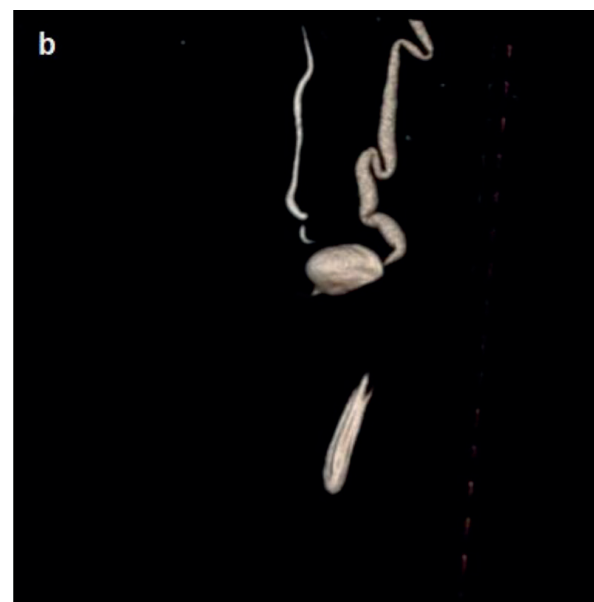
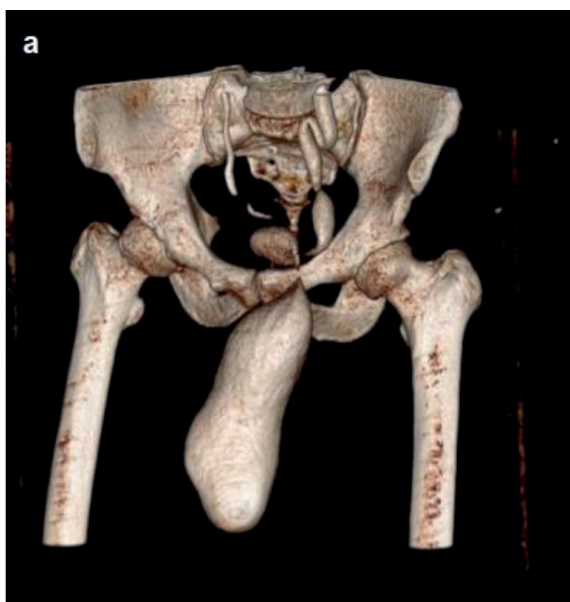
Herniation of the UB into the scrotum was defined as scrotal cystocele for the first time by Levine in 1951 [6,8,11]. Most of the time, scrotal cystocele occurs in older men; however, it can also happen in women [1,6,13]. Risk factors include male gender, BMI > 30 kg/m<sup>2</sup>, and benign prostatic hypertrophy (BPH). Due to the low incidence and non-specific symptoms of IBH, pre-operative diagnosis is tremendously challenging, as only 7% are diagnosed pre-operatively. If pre-operatively not diagnosed correctly, complications like iatrogenic injury or long-term complications (ureteric obstruction, vesicoureteric reflux,

bladder stones, sepsis, ischemia or perforation of herniated UB wall, kidney failure, or malignancy) can occur [1].

Radiological modalities like USG fluoroscopic cystography, antegrade IVU, CT-IVU, or SPECT-CT can help diagnose IBH pre-operatively [1]. In USG diagnostic criteria include the presence of an anechoic cystic lesion in the scrotum that is tapering cranially (a Chiragh-like sign) and shown to join the intra-abdominal part of the bladder. On excretory urography, Reardon and Lowman reported a triad comprising lateral dislocation of the distal ureter, a



**Figure 11.** Sagittal reformat image of CT-IVU showed the main bulk of UB herniated into the scrotum



**Figure 12.** (a and b) CT- MIP images showed large scrotal cystocele and left-sided hydronephrotic kidney with kinks.

small-sized asymmetric UB, and partial visualization of the bladder. Retrograde cystography is considered best in diagnosing IBH as it is easy to perform, causes less harm, and has good diagnostic reliability [2]. Nevertheless, a CT scan is the modality of choice [1]. A few studies showed SPECT-CT may also help to diagnose massive scrotal cystocele, that is mimicking inguinal metastasis on routine bone scan or an FDG PET scan but there is limited work done in nuclear medicine in this regard [11,12].

In our case, the male patient was 44 years old, obese, and presented with large globular left-sided scrotal swelling that completely buried the penile shaft, associated with forced and painful micturition. The swelling reduced significantly in size by squeezing the scrotum during micturition. Any inguinal swelling that reduces with micturition should raise the suspicion of scrotal cystocele. In this case, the patient had left-sided obstructive uropathy due to left pelvic ureter incarceration into the hernial neck and

reaching into the left hemiscrotum, while most described cases were on the right side [6]. Ureteral involvement should be in mind when the diagnosed IBH coincidentally has unexplained hydronephrosis, as in this case. Secondly, presenting symptoms were atypical but two-stage micturition (the most typical feature) is almost suggestive of scrotal cystocele [4]. In the first stage, he used to start to urinate naturally. In the second stage, he had to squeeze the scrotum to facilitate urination, which is known as the Mery sign [2].

With the age and voiding difficulties in consideration, benign BPH was also thought to have caused scrotal cystocele. Though DRE was not performed, as the patient could void without difficulty after manipulation of the scrotum, BPH was ruled out.

In patients with bladder hernia, the urological cancer ratio (mostly bladder cancer) is much more than the normal population [13].

#### What is new?

Scrotal cystocele is a rare condition typically affecting obese male patients between the ages of 50 and 70. Massive scrotal cystocele in those younger than 45 or in the pediatric population is uncommon. The patient involved in this study was a 44-year-old obese man, who presented with unusual symptoms.

#### Acknowledgments

Not applicable.

#### List of Abbreviations

BPH	benign prostatic hypertrophy
CT-IVU	Computed tomography intra-venous urogram
DRE	Digital rectal examination
FDG-PET	Fluorodeoxyglucose-positron emission tomography
IBH	Inguinal bladder hernia
SPECT-CT	Single-photon emission computerized tomography
MIP	Maximum intensity projection
UB	Urinary bladder
USG	Ultrasound

#### Conflict of interest

The authors declare that there is no conflict of interest regarding the publication of this article.

#### Funding

None.

#### Consent for publication

Written and informed consent was taken from the patient to publish this case report.

#### Ethical approval

Ethical approval is not required at our institution to publish an anonymous case report.

#### Availability of data and materials

Data sharing is not relevant to this article as no datasets were generated or analyzed (as this is a case report).

#### Authors' contribution

All of the authors have contributed sufficiently in the submission of this case and take public responsibility for its content. MQK and AA helped in writing the manuscript and selecting the case and images. NA and MBI helped in supervising and revising the manuscript. MBI also helped in corresponding with the journal.

#### Author details

Muhammad Qasim Khan<sup>1</sup>, Nayab Alia<sup>1</sup>, Muhammad Babar Imran<sup>2</sup>, Adeela Abid<sup>1</sup>

1. Department of Diagnostic Radiology, Madinah Teaching Hospital, Faisalabad, Pakistan
2. Department of Nuclear Medicine, Punjab Institute of Nuclear Medicine (PINUM), Faisalabad, Pakistan

#### References

1. Binjawhar A, Alsufyani A, Aljaafar M, Alsunbul A, AlMuaiqel M, Alghamdi AM. Vesical tumor within an inguinal bladder hernia: a case report. *Urol Case Rep*. 2021;38:101680. <https://doi.org/10.1016/j.eucr.2021.101680>
2. Gonzalez-Urquijo M, Mayagoitia-Gonzalez JC, Rodarte-Shade M, Bermea-Mendoza JH, Gil-Galindo G. Large inguinal bladder hernias: can a preoperative diagnosis be made? *Hernia*. 2019;23(6):1221–7. <https://doi.org/10.1007/s10029-019-01955-3>
3. Penha D, Pinto EG, Costa A. Scrotal cystocele by computed tomography and ultrasound. *Acta Med Port*. 2017;30(1):81. <https://doi.org/10.20344/amp.7513>
4. De Angelis M, Mantovani G, Di Lecce F, Boccia L. Inguinal bladder and ureter hernia: definition of a rare clinical entity and case report. *Case Rep Surg*. 2018;2018:9705728. <https://doi.org/10.1155/2018/9705728>
5. Habib A. A rare case of inguinal hernia with complete bladder herniation. *Case Rep Surg*. 2017;2017:4658169. <https://doi.org/10.1155/2017/4658169>
6. Reddy A, Shukla A, Jayamohan A, Lakshmanan P. The rarest of rare case of scrotal cystocele. *J Med Sci*. 2016;2(4):68–9. <https://doi.org/10.5005/jp-journals-10045-0043>
7. Hata K, Takahashi K, Kimura T, Egawa S. Repair of inguinal bladder hernias concomitant with localized prostate cancer: a case report and review of the literature. *Case Rep Urol*. 2020;2020:8877694. <https://doi.org/10.1155/2020/8877694>
8. Namba Y, Fukuda T, Ishikawa S, Kai S, Kohata A, Okimoto S, et al. Inguinal bladder hernia treated using transabdominal preperitoneal approach: a case report. *Int J Surg Case Rep*. 2020;67:165–8. <https://doi.org/10.1016/j.ijscr.2019.11.045>
9. Foladi N, Farzam F, Tahir Aien M. Massive inguino-scrotal herniation of urinary bladder in an infant (scrotal cystocele)-case report. *Radiol Case Rep*. 2020;15(5):607–9. <https://doi.org/10.1016/j.radcr.2020.02.024>
10. Chun K, Inn F, Hing E, Hong G. Imaging modalities for an uncommon inguinal scrotal pathology: a case report and literature review. *Urol Ann*. 2017;9(4):387–9. [https://doi.org/10.4103/UA.UA\\_69\\_17](https://doi.org/10.4103/UA.UA_69_17)
11. El Bez I, Munir I, Tulbah R, Alghmlas F, Alharbi M. Bladder hernia mimicking bone metastasis: case report with literature review. *Ann Clin Case Rep*. 2020;5:182.

12. Shagos GS, Padma S, Shanmuga Sundaram P. Incidentally detected inguinal herniation of urinary bladder in whole body skeletal scintigraphy. *Iran J Nucl Med*. 2012;20(2):34–6.
13. Ugur M, Atci N, Oruc C, Akkucuk S, Aydogan A. Left inguinal bladder hernia that causes dilatation in the ureter. *Arch Iran Med*. 2016;19(5):376–8.

#### Summary of the case

1	<b>Patient (gender, age)</b>	Male, 44 years
2	<b>Final diagnosis</b>	Left-sided scrotal cystocele causing left-sided obstructive uropathy
3	<b>Symptoms</b>	Two-step voiding, painful micturition, urinary frequency, nocturia, and incomplete emptying
4	<b>Medications</b>	NA
5	<b>Clinical procedure</b>	Herniorrhaphy
6	<b>Specialty</b>	Diagnostic radiology