

Coexistence of Paget disease and lung cancer - importance of patient management

Nevena Manevska^{1*}, Anamarija Jankulovska¹,
Dusica Todorova Stefanovski², Tanja Makazlieva¹,
Sinisa Stojanoski^{1,3}

European Journal of Medical Case Reports

Volume 6(1):21–26

<https://doi.org/10.24911/ejmcr/173-1634979125>



This is an open access article distributed in accordance with the Creative Commons Attribution (CC BY 4.0) license: <https://creativecommons.org/licenses/by/4.0/> which permits any use, Share — copy and redistribute the material in any medium or format, Adapt — remix, transform, and build upon the material for any purpose, as long as the authors and the original source are properly cited. © The Author(s) 2021

ABSTRACT

Background: The coexistence of metabolic bone disease, such as Paget disease (PD) and malignant tumor is frequently described in patients with breast, prostate, lung, lymphoproliferative, colorectal, and renal neoplasms. Indeed, when evaluating cancer patients, there may be diagnostic dilemma of interpreting some changes in bone involvement, whether they are malignant or metabolic changes, since some radiological features of metabolic bone disease can mimic those of bone metastases.

Case Presentation: We report a case of 55-year-old male patient, with diagnosed lung adenocarcinoma, referred to the Nuclear Medicine Department for a bone scintigraphy (BS), for evaluation of presented bone metastasis. The Single photon emission computed tomography (SPECT)/computer tomography (CT) scan revealed intensive metabolic accumulation of the radiotracer in cervical vertebra C7, and thoracic vertebra Th1, Th6, Th11, Th12, as well as lumbar vertebra L4, L5, left sacroiliac joint, both iliac and pubic bones and left proximal femur. The FDG PET/CT showed diffuse, but mildly increased uptake in Th6, Th11, L4, L5 and pelvic bones (SUV max = 3.3). The CT revealed destruction of Th11 body with compression fracture. Diagnosis of PD was made based on the findings of BS and PET/CT and further confirmed on bone biopsy and the patient was started with bisphosphonate therapy.

Conclusion: BS and SPECT/CT are of great importance in accurate detection of incidental PD in patients with lung cancer.

Keywords: Bone scan, SPECT/CT, bone metastasis, Paget disease, lung cancer, case report.

Received: 23 October 2021

Accepted: 18 December 2021

Type of Article: CASE REPORT

Specialty: Nuclear Medicine

Correspondence to: Nevena Manevska

*Medical Faculty, Institute of Pathophysiology and Nuclear medicine, Acad. Isak S. Tadzer, University of Ss. Cyril and Methodius, Skopje, Macedonia.

Email: dr.nmanevska@gmail.com and nmanevska@medf.ukim.edu.mk

Full list of author information is available at the end of the article.

Background

Bone scintigraphy (BS) is a non-invasive, highly sensitive, and cost-effective nuclear medicine procedure for evaluating the presence, location, and extent of bone metastasis, as well as for evaluation of response to therapy in cancer patients. Malignant tumors of breast, prostate, and lung commonly present with skeletal involvement in about 30% to 70% cases at initial presentation or during follow up. Although BS is a less specific method for bone metastases, it is easily available technique at all nuclear medicine centers and helps in further management of the patient, by assessing the distribution pattern of the metastasis [1,2].

The coexistence of metabolic bone disease, such as Paget disease (PD) with malignant tumor is frequently described in patients with breast, prostate, lung, lymphoproliferative, colorectal, and renal neoplasm [3,4]. Indeed, when evaluating cancer patients, there may be a diagnostic dilemma of interpreting some changes in bone involvement, whether they are malignant or metabolic changes, since some radiological features of metabolic bone disease can mimic those of bone metastases [5]. Sometimes

the disease is asymptomatic and found by coincidence when an imaging test is done for another reason. When BS is performed in patient with malignant disease, the nuclear medicine specialist should be aware about this possibility, because high radionuclide uptake in undiagnosed PD of the bone may lead to false-positive findings in oncological patients.

Case Presentation

We report a case of a 55-year-old male patient, diagnosed with non-small cell lung cancer (NSCLC), who was referred to the Nuclear Medicine Department for a BS, for evaluation of presence of bone metastasis. The history of the patient revealed a diagnosis of right lower lobe lung adenocarcinoma, and further treatment with operation (right lower lung lobectomy, with pTNM = pT4 pN2 G2 NG2 Stage III B), followed by chemotherapy and radiation therapy. Computer tomography (CT) of the thorax was performed before surgery, but without revealing the thoracic sclerotic changes of the vertebra. Two months after treatment he presented with a severe constant back

pain, as well as hip pain radiating to both lower extremities. He had a limitation of movement and was using a crutch for support. Oral narcotics were used to relieve the pain. Laboratory tests revealed elevated serum alkaline phosphatase.

Whole body bone scan was performed 3 hours after iv administration of 740 MBq 99mTc-MDP with planar (MEDISO-DHV) gamma camera in AP and PA position with a low energy, general purpose collimator and 128 × 128 matrix. The scan revealed intense accumulation of the radiotracer in the cervical vertebra C7, thoracic vertebra Th1, Th6, Th11, Th12, as well as lumbar vertebra L4, L5, further in the left sacroiliac joint, both iliac and pubic bones and left proximal femur (Figure 1). Single photon emission computed tomography/ computed tomography (SPECT/CT) (OPTIMA NM/CT 640, GE Healthcare) of the spine and pelvis was performed for further evaluation of the areas with increased osteoblastic activity (Figure 2, Figure 3).

Additional imaging studies, such as a CT of the spine and pelvis and 18F-fluorodeoxyglucose positron emission tomography / computed tomography (18F-FDG PET/CT) were performed 3 months after the bone scan. CT of the thorax detected diffuse sclerotic lesions on multiple thoracic vertebral bodies and it could not rule out malignant/metastatic cause. Several months later another PET/CT for surveillance was performed 60 minutes after intravenous administration of 267 MBq 18F-FDG. Images were acquired using SIEMENS Biograph mCT with low dose CT without contrast. The PET/CT scan showed diffuse, but mildly increased uptake in Th6, Th11, L4, L5 and pelvic bones (SUV max = 3.3). The CT revealed destruction of Th11 vertebral body with compression fracture (Figure 4). Diagnosis of PD was made based on the findings of BS and PET/CT, later confirmed with bone biopsy and the patient was started on bisphosphonate therapy. He

was started with bisphosphonate therapy with significant improvement of clinical symptoms afterwards

Discussion

Lung cancer is the leading cause of cancer deaths in males and females worldwide, with 1.8 million (one-fifth of the total) deaths in 2018. According to the World Health Organization in our country, there are 1,158 (14.8%) new cases of lung cancer per year, 909 (21.3%) are males and the 5-year prevalence is 52.76% [6]. In the European Community, the incidence of this disease for both genders in 2018 was 43.5/100,000 per year and the mortality rate was 34.8/100,000 [7].

Bone scan is still a common method for clinical diagnosis of bone metastases from lung cancer. 99mTc-MDP, a bone-seeking tracer, after iv injection is rapidly deposited to bones, binds to bone crystal surface by chemisorption and shows bone metabolism specifically. The bone and bone marrow are the most common site of metastasis for NSCLC, with around 30%-40% being confirmed during the course of the disease. In NSCLC, bone metastasis scintigraphy is used for clinical staging of the disease and in selecting patients for surgical resection [8].

Under the name osteitis deformans, PD was for the first time described by Sir James Paget, back in 1877 due to the characteristic change in the shape and size of the bone [9]. The underlining pathophysiologic mechanism of PD of bone is abnormalities in bone turnover due to imbalance between osteoclastic and osteoblastic activity. This results in increased risk of developing skeletal deformities, that as a consequence affect the physical functioning, as well as pathological fractures that have a significantly negative impact on the quality of the patient's life [10].

Generally, PD involves the axial skeleton, with strong predilection for the skull, the thoraco-lumbar spine and

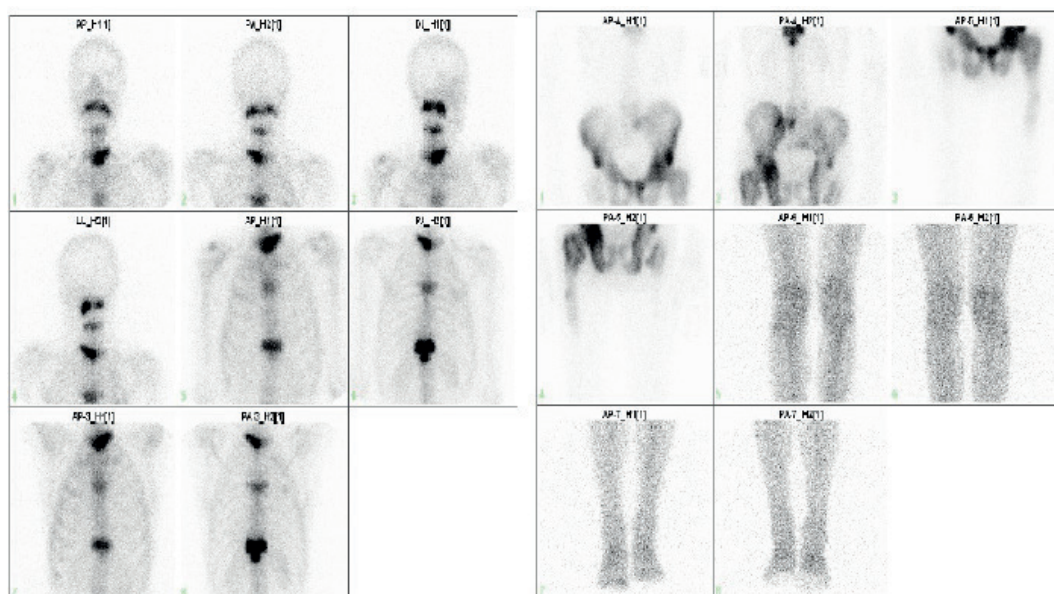


Figure 1. Planar bone scan.

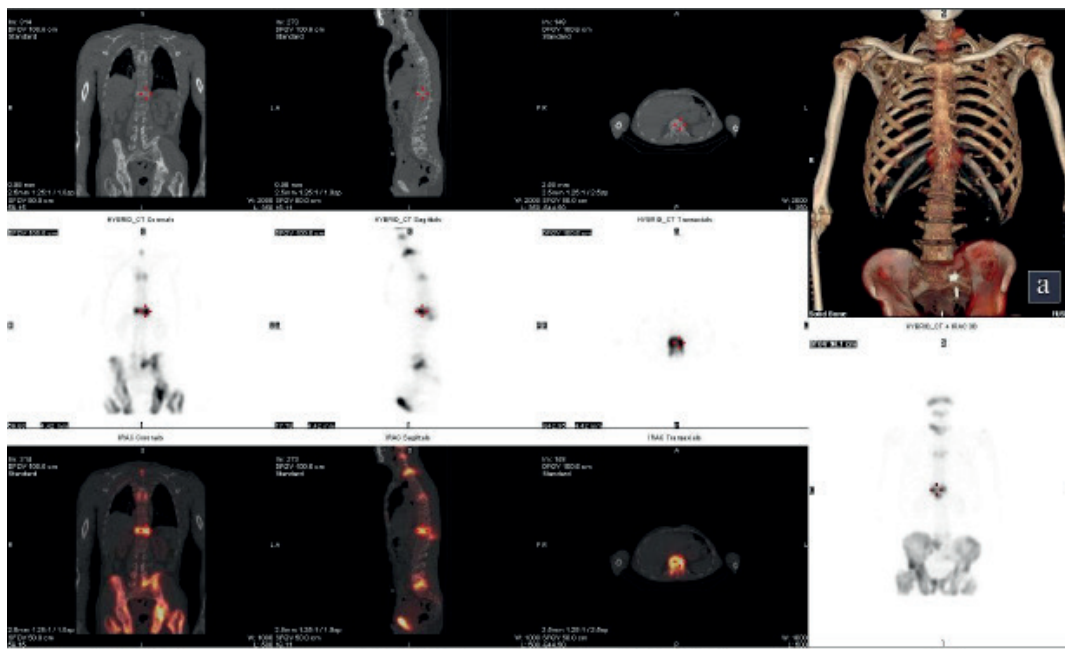


Figure 2. SPECT/CT of the spine.

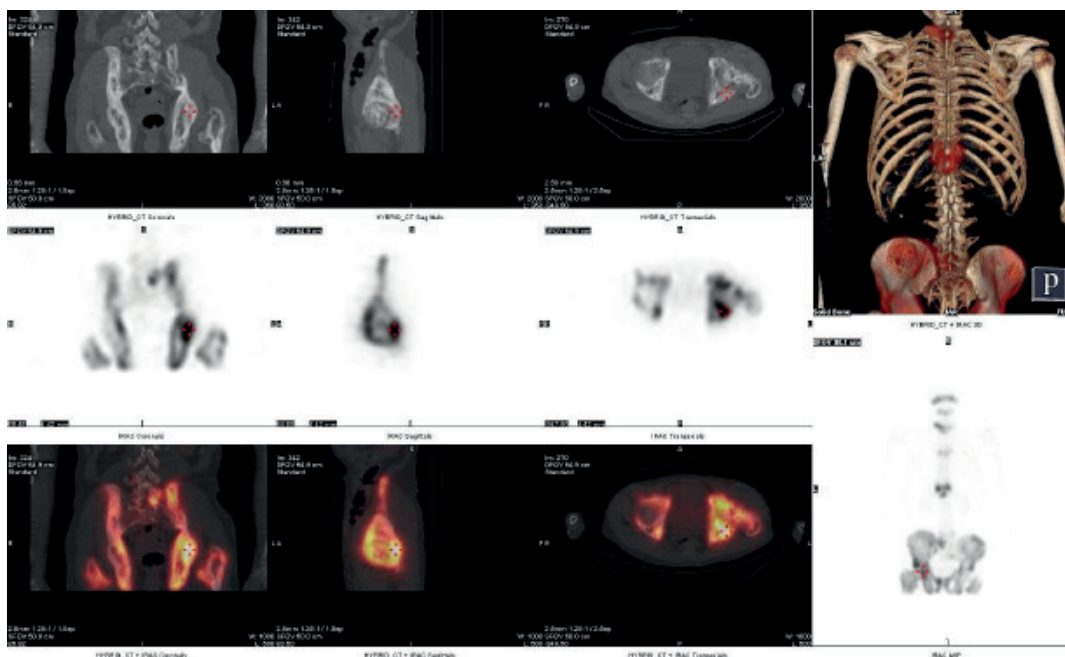


Figure 3. SPECT/CT of os coxae.

the pelvis and long bones of the lower extremities. There are two distinct forms of PD, monostotic and polyostotic, the latter appears more frequently, characterized by right-sided predominance and is more often asymmetrical in distribution. It involves the cranium (25% to 65%), vertebral column (30% to 75%), sacrum (30% to 60%), pelvis (30% to 75%), femur (25% to 35%), and tibia. The bone turnover distinguishes three phases. The first phase is the lytic phase (incipient-active), with osteoclasts predominance; followed by the mixed phase (active),

when osteoclast-mediated bone resorption continues but the activity of the osteoblasts begin as well, so their activity leads to coarsening and thickening of the trabecular pattern and cortex and the last phase is the blastic phase (late-inactive), in which osteoblastic activity predominates, resulting with sclerotic areas, mosaic pattern of the newly formed bone deposition and bone enlargement [11]. The diagnosis of the disorder is made by finding high serum levels of alkaline phosphatase in patients with increased radionuclide uptake in BS followed by typical

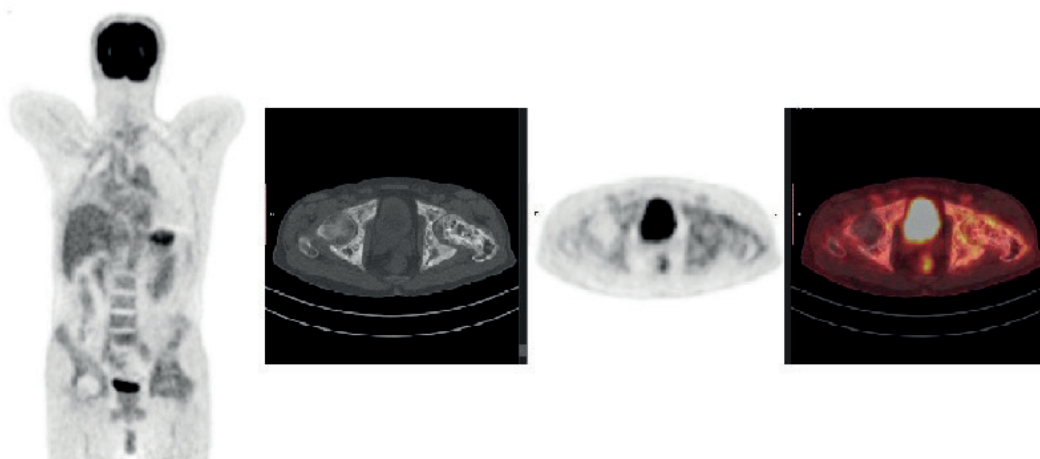


Figure 4. PET/CT scan (MIP and os coxae region).

X-ray features on plain radiography of the affected areas, with the typical cotton wool appearance as radiographic sign [12,13]. However, low serum levels of alkaline phosphatase should not exclude the possible presence of PD [14].

PET-CT scan may demonstrate positive accumulation sites of FDG, thus presenting active PD. But besides this, this diagnostic modality is not reliable to differentiate benign pagetoid changes from metastatic and sarcomatous changes of bone [15]. Active PD was described by Kamaleshwaran et al. [3] in the left hemipelvis in a patient with lung cancer, evaluated by FDG PET/CT for staging. The FDG uptake in left hemipelvis remained the same after three cycles of chemotherapy on the follow up scan suggestive for PD. Similar case was reported by Sá Pinto et al. [16] of uncommon monostotic form of PD affecting the scapula and mimicking a metastasis on FDG PET/CT during the staging of a lung cancer patient. BS and CT scan findings revealed PD.

PD was mimicking bone metastasis in other oncologic patients as well, showing heterogeneous moderate tracer uptake on PET/CT scan and “Swiss cheese” appearance on the CT part [4,17]. Typical “Mickey Mouse” sign of PD on BS was found by Dhanushkodi et al. [18] in a 62-year-old female patient with left breast carcinoma. Bone biopsy excluded metastasis and the patient was put on zoledronic acid therapy.

BS using ^{99m}Tc -MDP typically demonstrates marked increased uptake of the radionuclide in all three phases of PD. It is more sensitive than plain radiography for detection of increased both vascularity and osteoblastic activity and is most useful diagnostic tool in assessing the extent of the disease in polyostotic forms. In the long bones, increased radiotracer uptake typically abuts one joint and extends into the diaphysis to a variable extent. Some lesions in which osteoblastic activity

has become inactive will be negative on bone scan and can be detected only by plain radiography or CT scan. Initially, on plain radiography, there are signs of osteolysis in the affected areas (radiolucent regions), particularly affecting the skull (osteoporosis circumscripta) and subchondral long bones (V-shaped lesion). The mixed phase is characterized by thickening and disorganizing of the bone trabecular pattern, referred to as a “mosaic” pattern. Other typical signs in this phase include cotton wool appearance (skull), picture frame sign (spine) and cortical thickening and sclerosis of the iliopectineal and ischiopubic lines in the pelvis. Finally, in the blastic phase, diffuse sclerosis will develop. This highlights the importance of fusion imaging in the proper evaluation and characterization of skeletal lesions [19]. Paget bone lesions showing the characteristic radiological appearances are usually evident on CT too.

The intense MDP uptake in the pelvis lesion on BS and SPECT/CT in our case is a possibility of false positive finding in this patient with lung cancer. SPECT/CT in this case illustrates the usefulness of the fusion techniques in proper evaluation of skeletal lesions with the potential for discriminating between benign PD and bone metastasis. In practice, confusion may occur because of the similar radiological features for PD lesions and bone metastasis. For that reason, whenever this dilemma is present, bone biopsy should be performed which will enable the histopathological diagnosis of the lesion.

Conclusion

This case report highlights the importance of BS and SPECT/CT in accurate detection of incidental PD in patients with lung cancer. One should be aware of the possibility of this benign lesion for mimicking metastasis during the interpretation of the BS in oncological patients. Correlation with patient history, biochemical and

radiological findings would be helpful to differentiate PD from bone metastases. We believe that this knowledge is

What is new?

Coexistence of PD and malignant tumor may lead to false-positive findings in oncological patients. This case highlights the challenge of accurate interpretation of bone scan and SPECT/CT in differentiation between incidentally detected PD and bone metastasis in lung cancer patients that is crucial for further treatment and follow up.

crucial for optimal evaluation of bone scan and it could avoid as far as possible, false positive results in oncological patients with coexistence of a benign bone disease.

List of Abbreviations

BS	Bone scintigraphy
CT	Computed tomography
FDG	Fluorodeoxyglucose
MDP	Methylene diphosphonate
NSCLC	Non-small cell lung cancer
PD	Paget disease
PET	Positron emission tomography
pTNM	Classification of malignant tumors
SPECT	Single photon emission computed tomography
SUV	Standard uptake value

Conflict of interest

The authors declare that there is no conflict of interest regarding the publication of this article.

Funding

None.

Consent for publication

Written and informed consent was taken from patient to publish this case report.

Ethical approval

Ethical approval was received from our Institution to publish this anonymous case report.

Author details

Nevena Manevska¹, Anamarija Jankulovska¹, Dusica Todorova Stefanovski², Tanja Makazlieva¹, Sinisa Stojanoski^{1,3}

1. Medical Faculty, Institute of Pathophysiology and Nuclear medicine, Acad. Isak S. Tadzer, University of Ss. Cyril and Methodius, Skopje, Macedonia
2. University Institute for Positron Emission Tomography", Skopje, Macedonia
3. Department of Nuclear Medicine, Lazarski University, Warsaw, Poland

References

1. Heindel W, Gübitz R, Vieth V, Weckesser M, Schober O, Schäfers M. The diagnostic imaging of bone metastases. *Dtsch Arztebl Int*. 2014;111(44):741–7. <https://doi.org/10.3238/arztebl.2014.0741>
2. Wu F, Jiang Y, Ma L, Yu Q, Xue W, Wang Z. Detection of bone metastases in patients with cancer: 99mTc-MDP bone scan and 18F-FDG PET/CT. *Biomed Res*. 2017;28(3):1299–304.
3. Kamaleshwaran KK, Natarajan S, Shibu D, Malaikkal A, Shinto AS. Paget's disease of pelvis mimicking metastasis in a patient with lung cancer evaluated using staging and follow-up imaging with fluorine-18 fluorodeoxyglucose-positron emission tomography/computed tomography. *Indian J Nucl Med*. 2015;30(2):151–3. <https://doi.org/10.4103/0972-3919.152980>
4. Sasikumar A, Joy A, Pillai MR, Raman V, Vasudevan A, Madhavan J. A rare case of rectal carcinoma and prostate carcinoma with coexistent Paget's disease mimicking bone metastases in both 18F-FDG and 68Ga PSMA PET/CT. *Eur J Nucl Med Mol Imaging*. 2017;44(1):173. <https://doi.org/10.1007/s00259-016-3529-8>
5. Rybak LD, Rosenthal DI. Radiological imaging for the diagnosis of bone metastases. *QJ Nucl Med*. 2001;45(1):53–64.
6. Bray F, Ferlay J, Soerjomataram I, Siegel RL, Torre LA, Jemal A. Global cancer statistics 2018: GLOBOCAN estimates of incidence and mortality worldwide for 36 cancers in 185 countries. *CA Cancer J Clin*. 2018;68(6):394–424. <https://doi.org/10.3322/caac.21492>
7. Ferlay J, Colombet M, Soerjomataram I, Dyba T, Randi G, Bettio M, et al. Cancer incidence and mortality patterns in Europe: estimates for 40 countries and 25 major cancers in 2018. *Eur J Cancer*. 2018;103:356–87. <https://doi.org/10.1016/j.ejca.2018.07.005>
8. Rossi A, Gridelli C, Ricciardi S, de Marinis F. Bone metastases and non-small cell lung cancer: from bisphosphonates to targeted therapy. *Curr Med Chem*. 2012;19(32):5524–35. <https://doi.org/10.2174/092986712803833209>
9. Bhargava P, Maki JH. Images in clinical medicine. "Cotton wool" appearance of Paget's disease. *N Engl J Med*. 2010;363(6):e9. <https://doi.org/10.1056/NEJMicm0912945>
10. Langston AL, Campbell MK, Fraser WD, MacLennan G, Selby P, Ralston SH. Clinical determinants of quality of life in Paget's disease of bone. *Calcif Tissue Int*. 2007;80(1):1–9. <https://doi.org/10.1007/s00223-006-0184-2>
11. Smith SE, Murphey MD, Motamedi K, Mulligan ME, Resnik CS, Gannon FH. From the archives of the AFIP. Radiologic spectrum of Paget disease of bone and its complications with pathologic correlation. *Radiographics*. 2002;22(5):1191–216. <https://doi.org/10.1148/radiographics.22.5.g02se281191>
12. Griz L, Fontan D, Mesquita P, Lazaretti-Castro M, Borba VZ, Borges JL, et al. Diagnosis and management of Paget's disease of bone. *Arq Bras Endocrinol Metabol*. 2014;58(6):587–99. <https://doi.org/10.1590/0004-2730000002941>
13. Langston AL, Ralston SH. Management of Paget's disease of bone. *Rheumatology (Oxford)*. 2004;43(8):955–9. <https://doi.org/10.1093/rheumatology/keh243>
14. Paolino S, Pendolino M, Alessandri E, Cutolo M, Pizzorni C. Paget's disease of the bone mimicking metastasis: two case reports. *J Clin Case Rep*. 2018;8:2.
15. Chakraborty D, Mittal BR, Kamaleshwaran KK, Kashyap R, Bhattacharya A, Kumar S. Urinary bladder carcinoma associated with Paget's disease of skull: imaging findings on Tc99m-MDP bone scintigraphy, F18-Fluoride PET/CT and F18-FDG PET/CT. *Indian J Nucl Med*. 2011;26(1):42–3. <https://doi.org/10.4103/0972-3919.84614>
16. Sá Pinto A, Alves VM, Oliveira A, Castro RH, Pereira JG. Incidental finding of a monostotic form of Paget disease of the scapula in a lung cancer patient. *Radiography (Lond)*. 2017;23(3):e72–4. <https://doi.org/10.1016/j.radi.2017.02.005>

17. Mahmood S, Martinez de Llano SR. Paget disease of the humerus mimicking metastatic disease in a patient with metastatic malignant mesothelioma on whole body F-18 FDG PET/CT. *Clin Nucl Med*. 2008;33(7):510–2. <https://doi.org/10.1097/RLU.0b013e318177928a>
18. Dhanushkodi M, Radhakrishnan V, Kumar K, Iyer P, Ananthi B, Krishnamurthy A. Paget’s disease of bone (PDB): mimicker of bone metastasis. *Indian J Gynecol Oncol*. 2019;17(1). <https://doi.org/10.1007/s40944-019-0265-6>
19. Gezer NS, Balci A, Özdoğan Ö, Özaksoy D. Paget’s disease mimicking bone metastasis in a patient with neuroendocrine tumor on 68Ga-DOTANOC PET/CT. *J Belg Soc Radiol*. 2016;100(1):66. <https://doi.org/10.5334/jbr-btr.903>

Summary of the case

1	Patient (gender, age)	Male, 55
2	Final diagnosis	PD
3	Symptoms	Back pain
4	Medications	Bisphosphonate
5	Clinical procedure	SPECT/CT 99mTc-MDP, 18F-FDG
6	Specialty	Nuclear Medicine