

years. In September 2019 a routine abdominal CT scan did not show any tumoral recidive. Nevertheless, the physician observed a hard nodular umbilical plaque with a diameter of 1.5 cm and suspicious macroscopical features (Figure 1). Histopathological evaluation revealed metastasis of the gastric signet cell adenocarcinoma, suggesting a Sister Mary Joseph nodule (Figures 2 and 3). Because of proven tumor relapse, she went through several treatments with chemotherapy. The patient died in April 2021. The overall survival was 19 months after the diagnosis of the Sister Mary Joseph nodule.

Case Presentation Patient 2

A 62-year-old female visited the outpatient department of surgery in November 2020 for a hard painless umbilical nodule with diameter of 2.5 cm. In another hospital, a diagnosis of umbilical hernia had been made. Biopsy was performed and showed an epithelial high-grade malignant serous papillary tumor with immunoreactivity

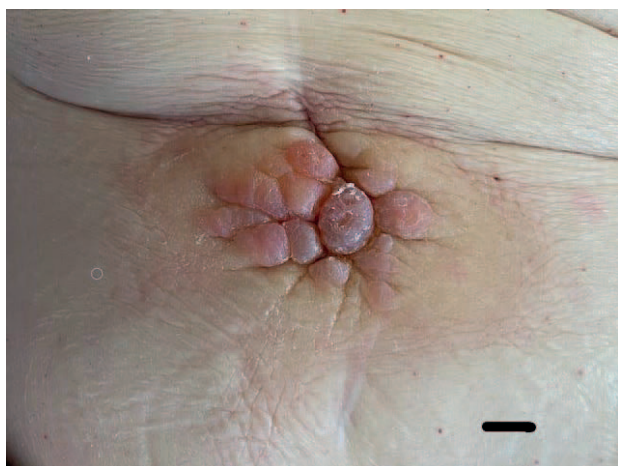


Figure 1. Umbilical skin with bluish black Sister Mary Joseph nodule of patient invaded by neoplastic cells from gastric less differentiated adenocarcinoma (Scale bar: 1 cm).

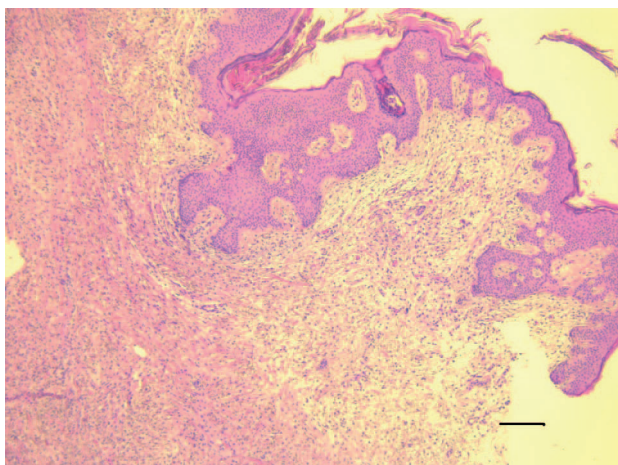


Figure 2. Umbilical skin (Sister Mary Joseph nodule) infiltrated by diffuse proliferation of malignant epithelial cells of gastric less differentiated adenocarcinoma (magnification 10x. Scale bar :200 µm. Hematoxylin/Eosin stain).

for estrogen receptor, p53, and PAX-8, highly suggestive for an umbilical metastasis (Sister Mary Joseph nodule) of an ovarian serous papillary adenocarcinoma (Figures 4 and 5). Magnetic resonance imaging (MRI) followed by laparoscopy and subsequent debulking revealed a high grade serous papillary ovarian adenocarcinoma (FIGO grade IIIB) with omental and peritoneal metastasis (TNM: pT3b N0 G3). Adjuvant chemotherapy was started with six cycles of Carboplatinum-Taxol. The patient is alive and disease free.

Discussion

Umbilical metastasis is found in 1%-3% of abdominal malignancies most frequently with gastric and ovarian carcinoma. Sister Mary Joseph nodule presents as an umbilical nodule that may be painful and discharge fluid. The size can range between 0.5 and 15 cm. It is very important to

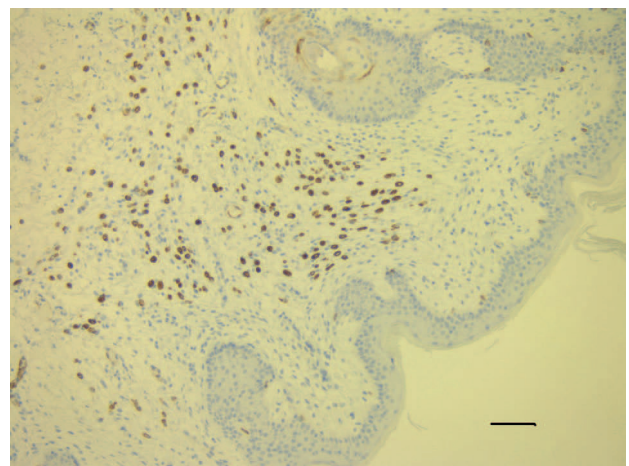


Figure 3. Umbilical skin (Sister Mary Joseph nodule) infiltrated by diffuse proliferation of malignant epithelial cells of gastric less differentiated adenocarcinoma displaying strong cytoplasmic immunoreactivity for cytokeratin 7 (immunohistochemistry for mouse anti-human monoclonal antibody CK7 with peroxidase/DAB visualization magnification 40x. Scale bar :50 µm)

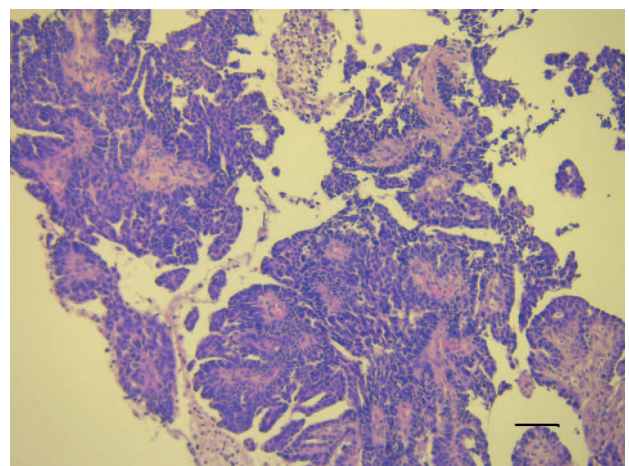


Figure 4. Biopsy of Umbilical skin (Sister Mary Joseph nodule) displaying neoplastic tissue consisting of serous papillary high grade malignant epithelial tumor (magnification 40x. Scale bar :50 µm. Hematoxylin/Eosin stain).

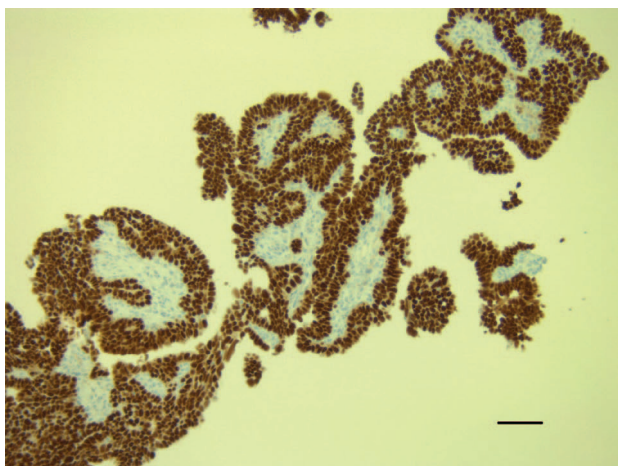


Figure 5. Biopsy of umbilical skin (Sister Mary Joseph nodule) displaying neoplastic tissue consisting of serous papillary high grade malignant adenocarcinoma with strong nuclear immunoreactivity for PAX-8 suggesting ovarian origin (magnification 40x. Immunohistochemistry for mouse anti-human monoclonal antibody PAX8 with peroxidase/DAB visualization magnification 40x. Scale bar: 50 μ m).

bear in mind that a Sister Mary Joseph nodule can be the only sign of malignancy in an otherwise well patient [4,5]. This was the case in the second patient. Metastasis to the umbilicus is quite rare and accounts for only 10% of all cutaneous metastases.

In many reports, the most common cause is gastro-intestinal cancer (35%-65%) and genito-urinary cancer (12%-35%) among which gastric cancer and ovarian cancer are often mentioned [4,5]. In one of the two patients, the umbilical metastasis was the first sign of ovarian neoplasia, more specifically papillary serous adenocarcinoma. It is worth mentioning that the patient's umbilical nodule was first diagnosed in another hospital as a benign umbilical hernia. A biopsy performed in our hospital disclosed the malignant nature of the nodule and suggested the possibility of a gynecological tumor. In the other patient, the appearance of a Sister Mary Joseph nodule was the first sign of relapse of her gastric signet cell adenocarcinoma, although the clinical imaging (CT scan) was not conclusive for malignancy. ^{18}F -FDG PET/MRI or ^{18}F -FDG PET/CT can be of value not only for highlighting Sister Mary Joseph nodule but also for detecting the primary malignant tumor and staging [6,7]. It is, therefore, very important to be clinically aware of the possibility of malignancy when exploring an umbilical nodule. The finding of a Sister Mary Joseph nodule bears an ominous prognosis for the patient. Median survival time ranges from 2 to 11 months for a known primary tumor and 10 months for an unknown primary tumor [8]. Review of the literature shows very few cases of gastric signet ring cell adenocarcinoma presenting as a Sister Mary Joseph nodule [4,9,10].

Differential diagnosis must be made with primary umbilical tumors (38% of cases) such as primary umbilical adenocarcinoma and malignant skin tumors as melanoma, basal and squamous cell carcinoma [11]. Benign lesions include endometriosis (32% of all cases), omphalitis, keloid tissue, hernia, urachal duct cysts, abscesses, pyogenic granuloma, epidermoid cysts, pyoderma gangrenosum, and foreign body reaction (piercing material). We reviewed the archives of our pathology department in Lier from 2010 to 2021 and found one case of a primary umbilical malignant tumor consisting of a basal cell carcinoma.

The exact genesis of Sister Mary Joseph nodule is not very well known. Some authors hypothesize hematogenous spread by arteries or veins, lymphatic spread, direct infiltration by peritoneal dissemination and direct extension along the embryonic ligaments [12]. These fetal structures develop into ligaments or peritoneal folds after birth. The fetal umbilical structures become four ligaments: median umbilical ligament (urachus), median umbilical ligament (umbilical arteries) ligamentum teres and falciform ligament (umbilical vein). The umbilical region is connected by the lymphatic system to the axillary, inguinal and para-aortic lymph nodes. There is a rich arterial, as well as venous blood supply connecting the umbilical region with the inferior epigastric and deep circumflex iliac vessels as well as several anastomoses from the internal mammary vein, or from the portal system of the liver. Dissemination of malignant cells can occur by the fibrotic embryonal remnants or by the rich periumbilical lymphatic, arterial and venous network.

We conclude that Sister Mary Joseph nodule is a rare but pathognomonic sign of malignancy. It is important that physicians pay attention to this sign because it can lead to a rapid diagnosis. Differential diagnosis must be made with primary malignant umbilical lesions, as well as with benign umbilical lesions such as umbilical hernia as was the case in one of our patients. Biopsy can elucidate the exact nature of an umbilical nodule and suggest a possible origin in case of malignancy.

List of Abbreviations

^{18}F -FDG	18 fluorodeoxyglucose
CDX2	Caudal related homeobox gene 2
CK 7	Cytokeratin 7
CT	computed tomography
DAB	3,3' diaminobenzidine
FIGO	Federation Internationale de Gynécologie et d' Obstétrique
MRI	Magnetic Resonance Imaging
MUC5AC	Gel forming/secreted mucin 5AC
P53	Tumor suppressor gene protein 53
PAX8	Paired box gene 8
PET	Positron Emission Tomography
TCF	Taxol-cisplatinum- 5-Fluorouracil

Conflict of interest

The authors declare that there is no conflict of interest regarding the publication of this article.

Funding

None.

Consent for publication

Written informed consent was obtained for the clinical picture from the patient.

Ethical approval

Ethical approval is not required at our institution to publish an anonymous case report.

Author details

Maaïke Ramael¹, Helene Poels², Hilde Van Steelandt³, Wim Develter⁴, Marc Ramael^{4,5}

1. Faculty of Medicine and health sciences, University of Antwerp, Belgium
2. Department of Gastroenterology, Heilig Hartziekenhuis, Lier, Belgium
3. Department of Molecular Imaging, AZ Herentals, Herentals, Belgium
4. Department of Pathology and Molecular Pathology, Heilig Hartziekenhuis, Lier, Belgium
5. Laboratory of cell biology and histology, University of Antwerp, Antwerp, Belgium.

References

1. Quenu E. Du cancer secondaire de l'ombilic. *Rev Chir*. 1896;16:97–133.
2. Bailey H. Demonstrations of clinical signs in clinical surgery. 11th ed. Bristol, UK: John Wright & sons, Ltd; 1919. 227 p.
3. Mayo WJ. Metastasis in cancer. *Proc Staff Meet Mayo Clin*. 1928;3:327.
4. Ioannidis O, Cheva A, Stavrakis T, Paraskevas G, Papadimitriou N, Kakoutis E, et al. Sister Mary Joseph's nodule as the sole presenting sign of gastric signet ring cell adenocarcinoma. *Gastroenterol Clin Biol*. 2010;34(10):565–8. <https://doi.org/10.1016/j.gcb.2010.07.005>
5. Gupta P, Kumari A, Kriplani A, Bhatla N. Sister Mary Joseph's nodule as the first and only sign of recurrence in a case of stage Ia carcinoma ovary. *BMJ Case Rep*. 2014;2014:bcr2013201779. <https://doi.org/10.1136/bcr-2013-201779>
6. Yang M, Hopp AC, Bekaii-Saab TS, Collins JM. Sister Mary Joseph nodule in advanced pancreatic adenocarcinoma identified on 18F-FDG PET/MRI. *J Nucl Med Technol*. 2019;47(4):341–2. <https://doi.org/10.2967/jnmt.119.225961>
7. Inanir S, Oksuzoglu K. FDG PET/CT imaging of calcified Sister Mary Joseph nodule. *Clin Nucl Med*. 2016;41(10):e458–9. <https://doi.org/10.1097/RLU.0000000000001283>
8. Gabriele R, Conte M, Egidi F, Borghese M. Umbilical metastases: current viewpoint. *World J Surg Oncol*. 2005;3(1):13. <https://doi.org/10.1186/1477-7819-3-13>
9. Kapoor R, Kapoor JR. Signet cell gastric adenocarcinoma presenting as a sister Joseph nodule. *J Clin Gastroenterol*. 2007;41(10):934. <https://doi.org/10.1097/01.mcg.0000225617.79223.3c>
10. Zadeh VB, Kadyan R, Al-Abdulrazzaq A, Al-Otaibi S, Sarhan A, Najem N. Sister Mary Joseph's nodule: a case of umbilical cutaneous metastasis with signet ring cell histology. *Indian J Dermatol Venereol Leprol*. 2009;75(5):503–5. <https://doi.org/10.4103/0378-6323.55396>
11. Heatley MK, Toner PG. Sister Mary Joseph's nodule: a study of the incidence of biopsied umbilical secondary tumours in a defined population. *Br J Surg*. 1989;76(7):728–9. <https://doi.org/10.1002/bjs.1800760726>
12. Palaniappan M, Jose WM, Mehta A, Kumar K, Pavithran K. Umbilical metastasis: a case series of four Sister Joseph nodules from four different visceral malignancies. *Curr Oncol*. 2010;17(6):78–81. <https://doi.org/10.3747/co.v17i6.684>

Summary of the case

1	Patient (gender, age)	Females: 71 and 62 years
2	Final diagnosis	Metastasis gastric adenocarcinoma, metastasis ovarian serous papillary adenocarcinoma
3	Symptoms	Dysphagia, weight loss, umbilical plaque
4	Medications	Chemotherapy
5	Clinical procedure	Imaging, biopsy, gastrectomy, hysterectomy + bilateral ovariectomy
6	Specialty	Oncology